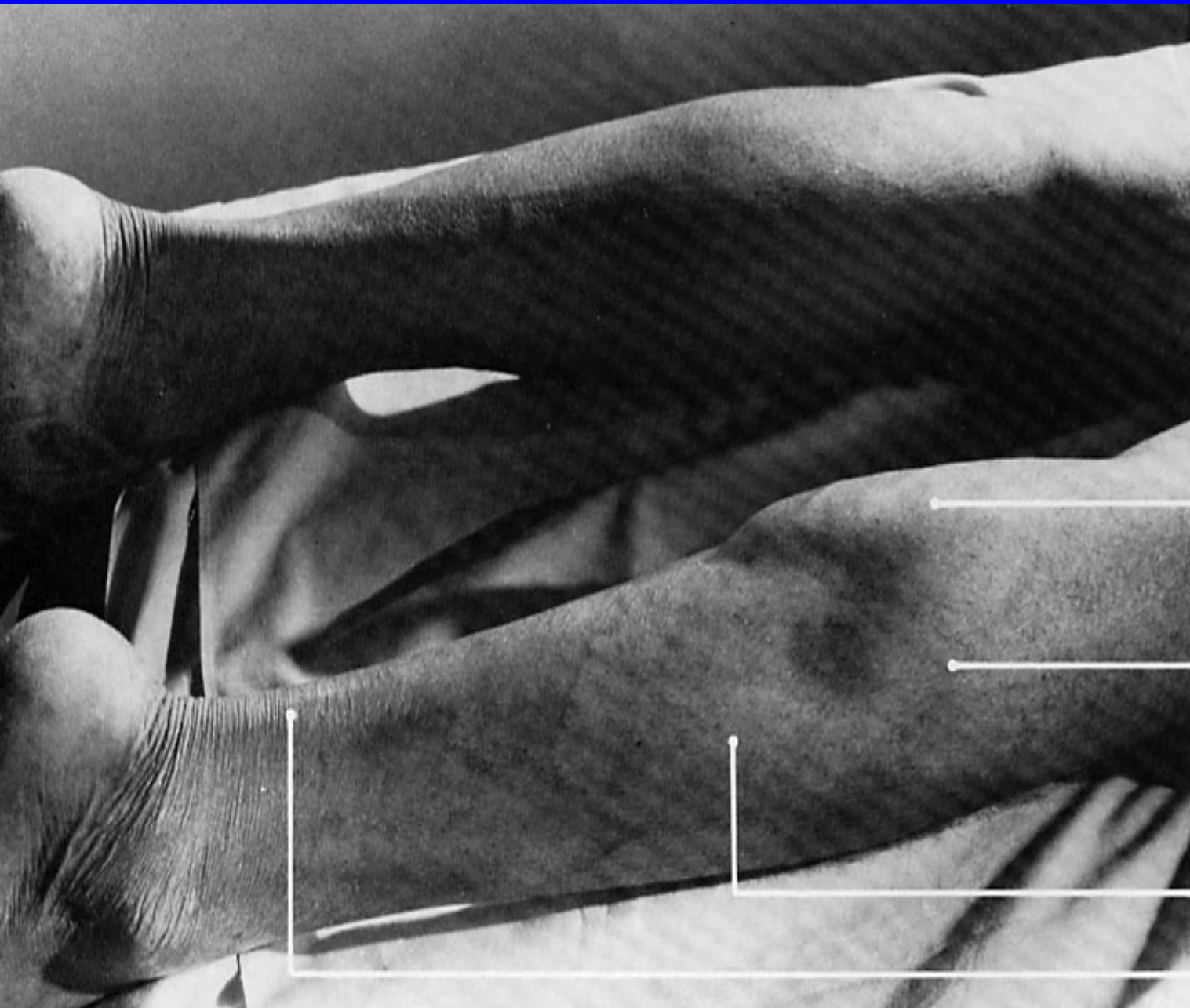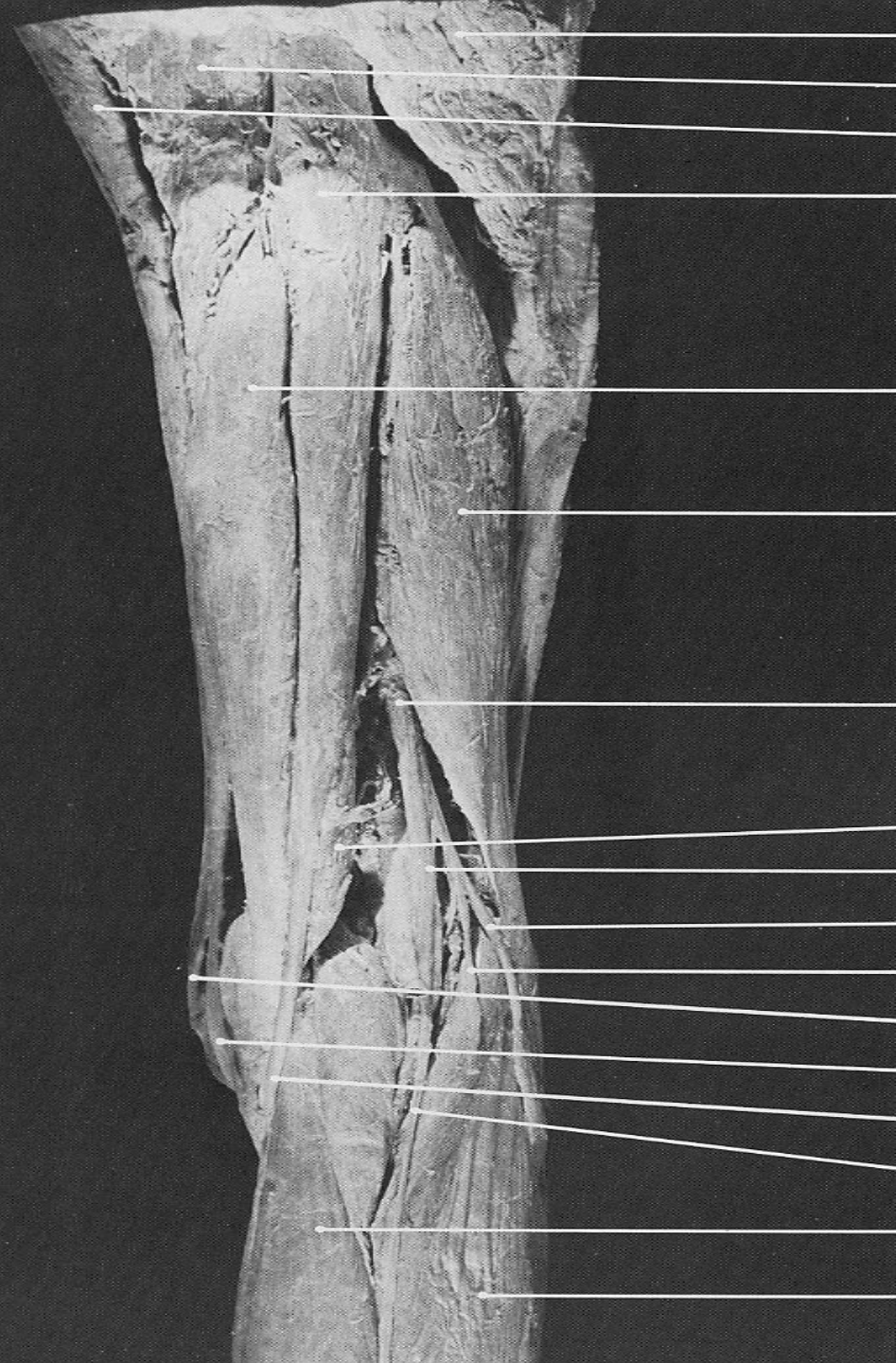


**gastrocnemius  
(medial head)**

**gastrocnemius  
(lateral head)**

**soleus**

**tendo Achillis**



gluteus maximus

adductor magnus

gracilis (belly)

semitendinosus (belly)

semimembranosus

biceps femoris (long head)

sciatic n.

semimembranosus

tibial n.

common peroneal n.

lateral sural cutaneous n. (cut off)

sartorius (tendon)

gracilis (tendon)

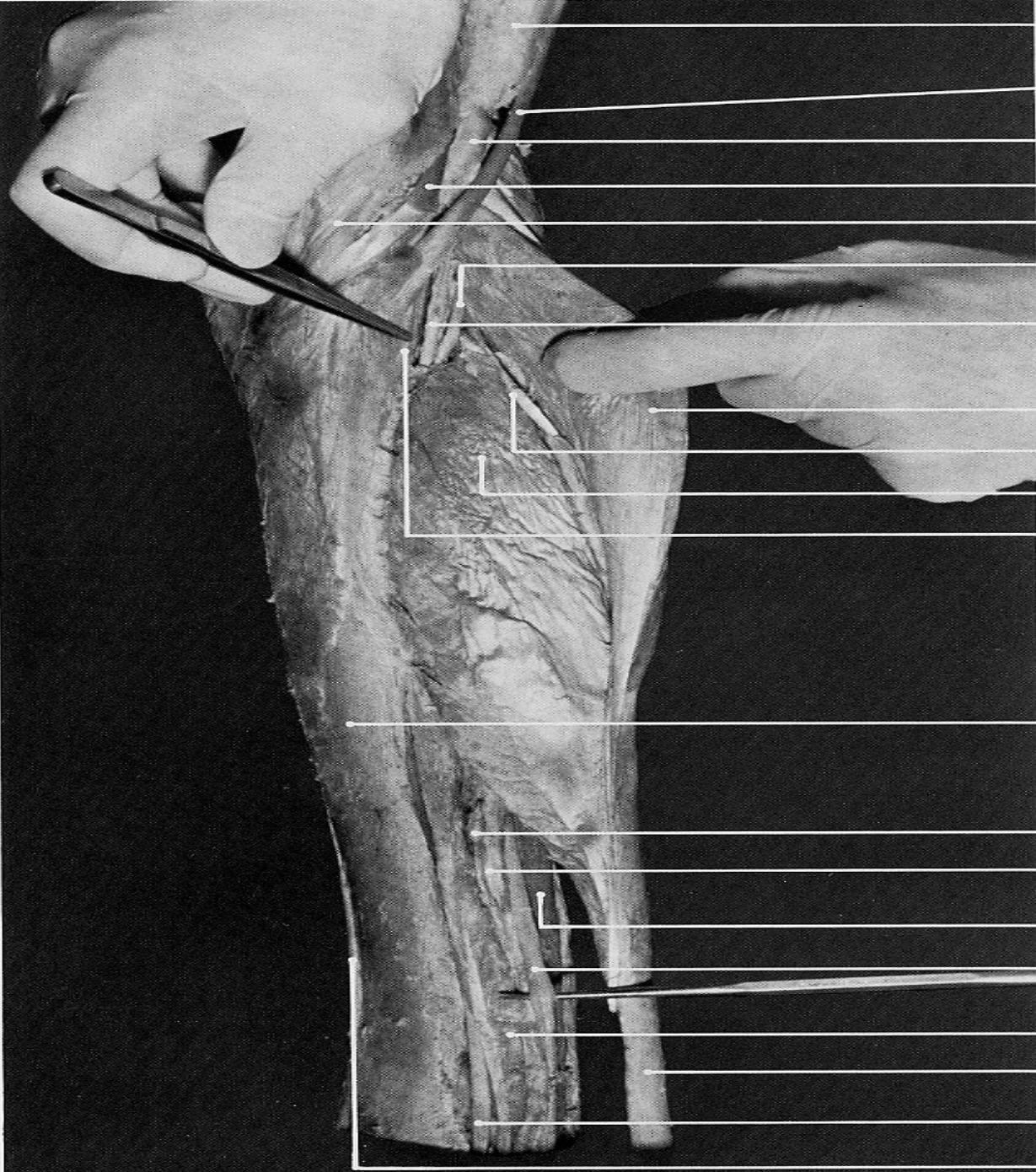
semitendinosus (tendon)

medial sural cutaneous n.

gastrocnemius (medial head)

gastrocnemius (lateral head)





semimembranosus (belly)

semitendinosus (tendon)

semimembranosus (tendon)

gracilis (tendon)

sartorius (tendon)

tibial n.

tibial v.

gastrocnemius (medial head)

plantaris (tendon)

soleus (tibial origin)

tibial a.

medial surface of tibia

posterior tibial v.

posterior tibial a.

flexor hallucis longus

tibial n. elevated by probe

flexor digitorum longus

tendo Achillis

tibialis posterior (tendon)

tibialis anterior (tendon)

# MEDIAL GASTROCNEMIUS

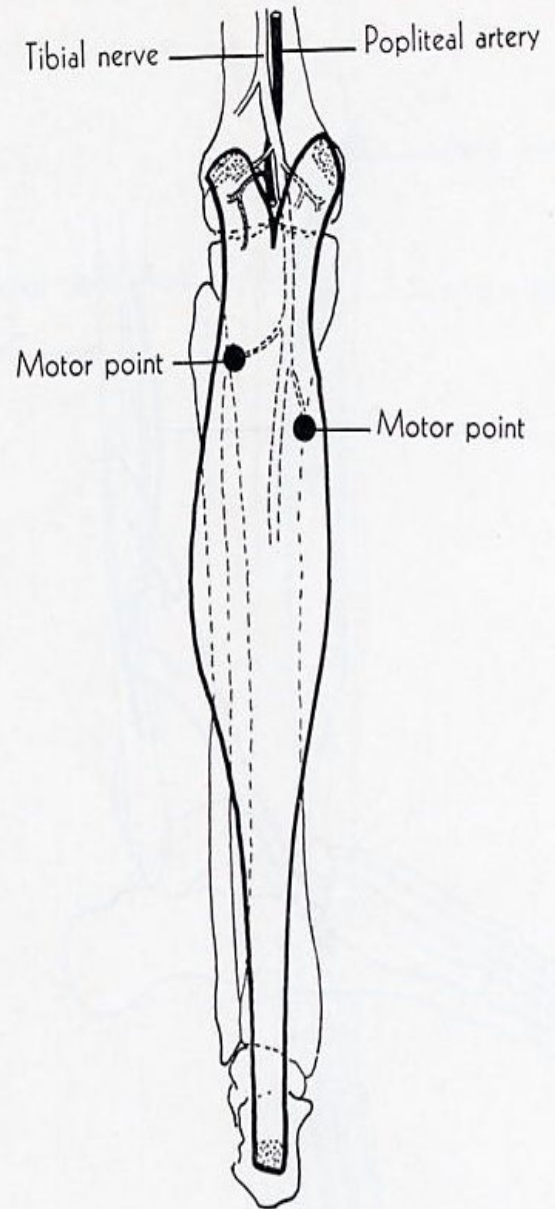
**ORIGIN:** medial condyle and adjacent part of femur, capsule of knee joint.

**INSERTION:** into calcaneus by calcaneal tendon.

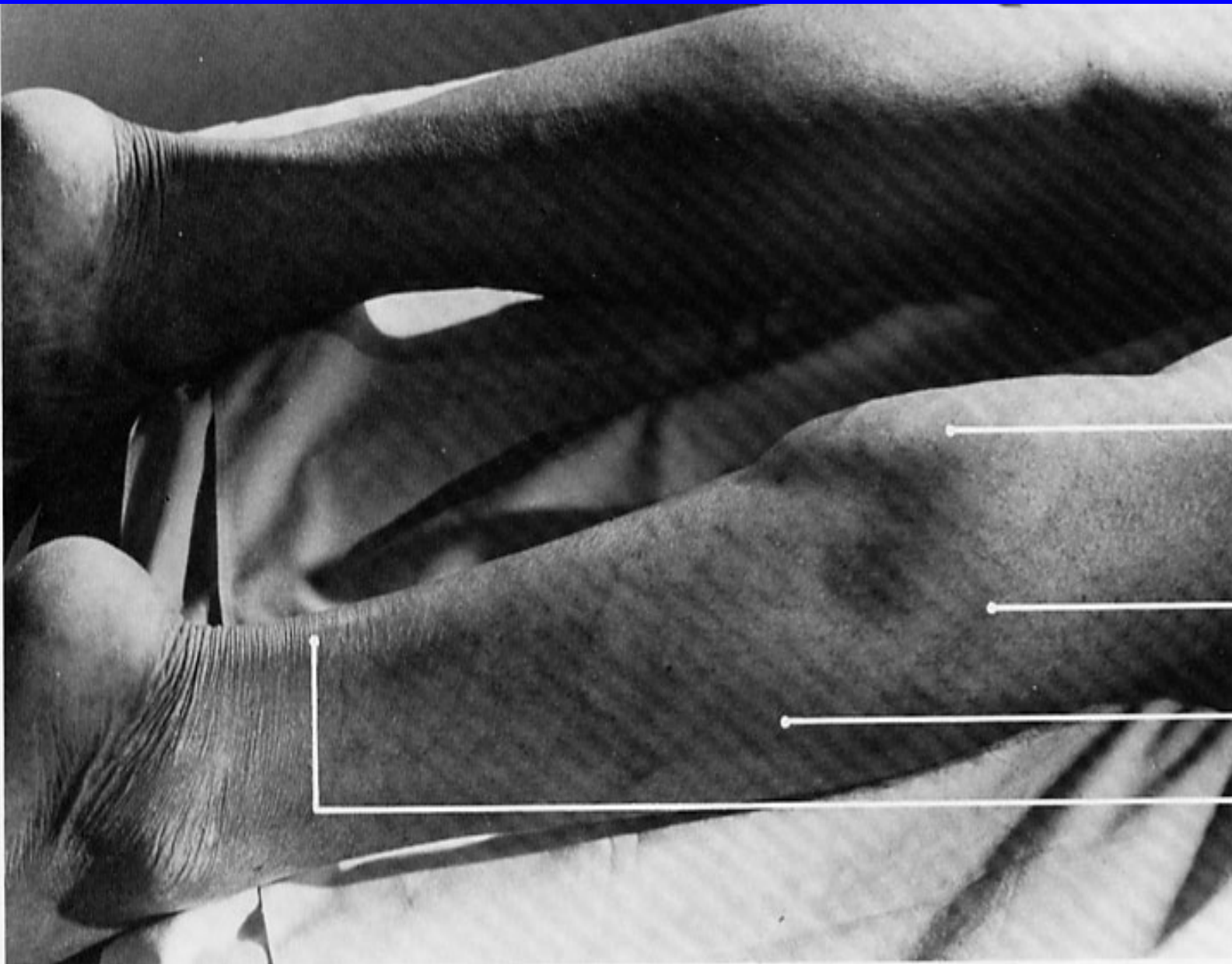
**ACTION:** plantar flexes foot; acting from below, it flexes femur on tibia.

**NERVE:** tibial.

**ROOT:** S1 and S2 mainly S1.





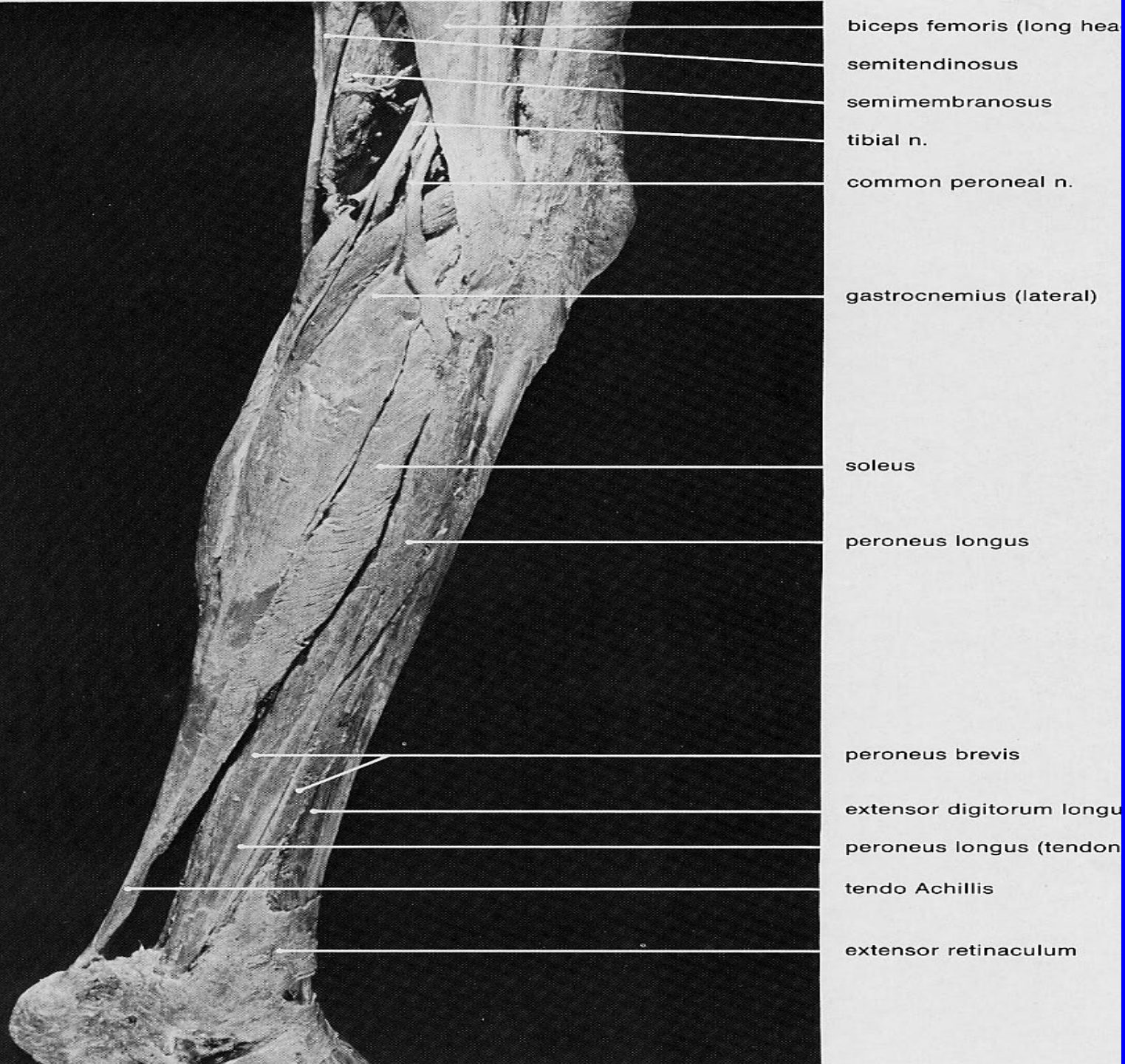


**gastrocnemius  
(medial head)**

**gastrocnemius  
(lateral head)**

**soleus**

**tendo Achillis**





# LATERAL GASTROCNEMIUS

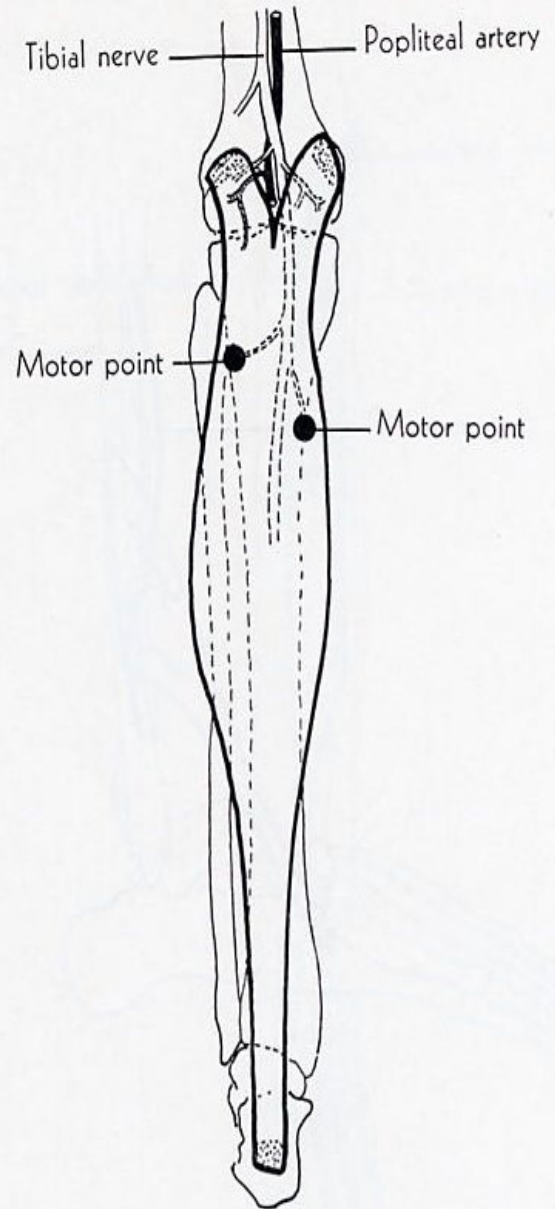
**ORIGIN:** lateral condyle and adjacent part of femur, capsule of knee joint.

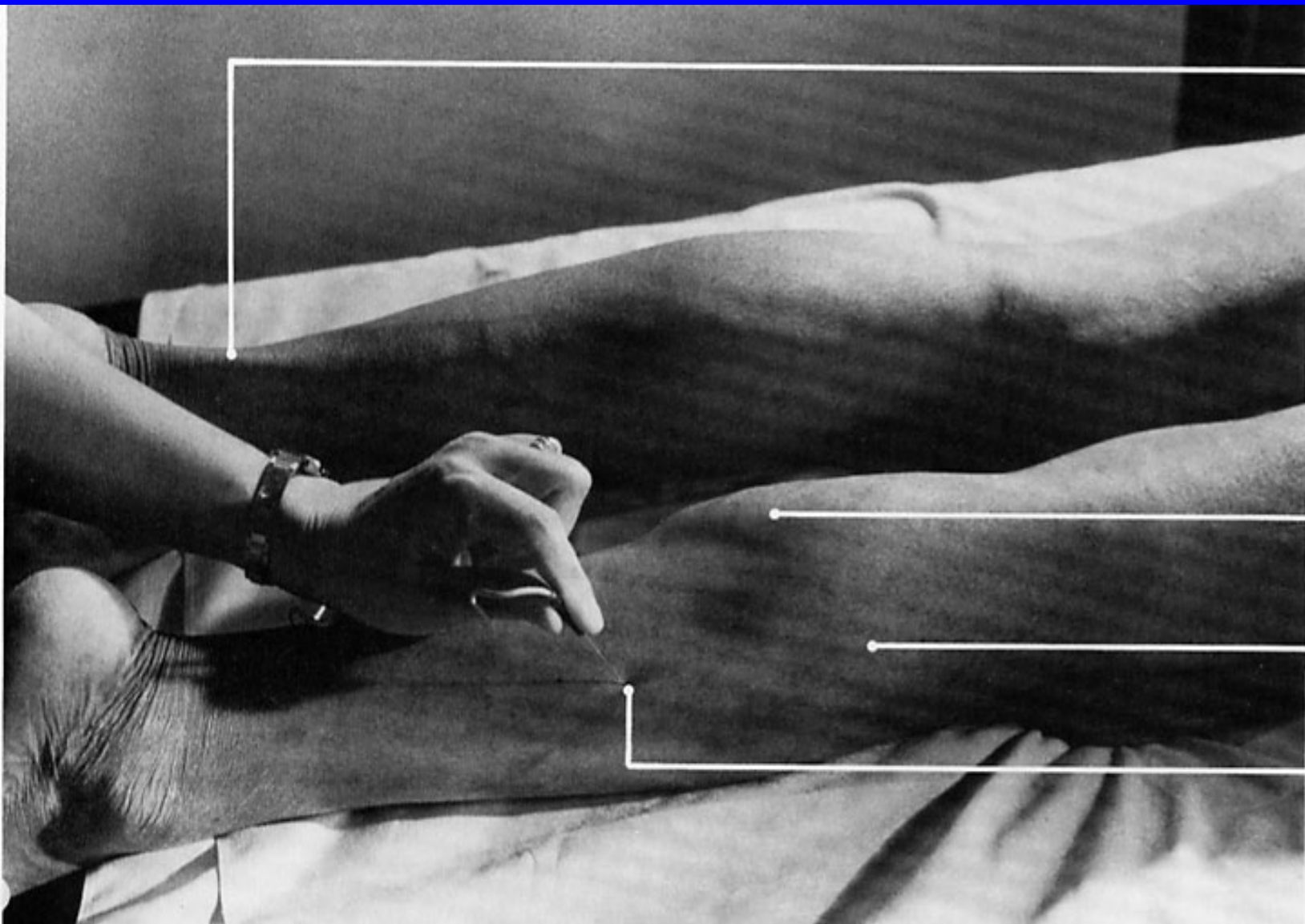
**INSERTION:** into calcaneus by calcaneal tendon.

**ACTION:** plantar flexes foot; acting from below, it flexes femur on tibia.

**NERVE:** tibial.

**ROOT:** S1 and S2 mainly L5.





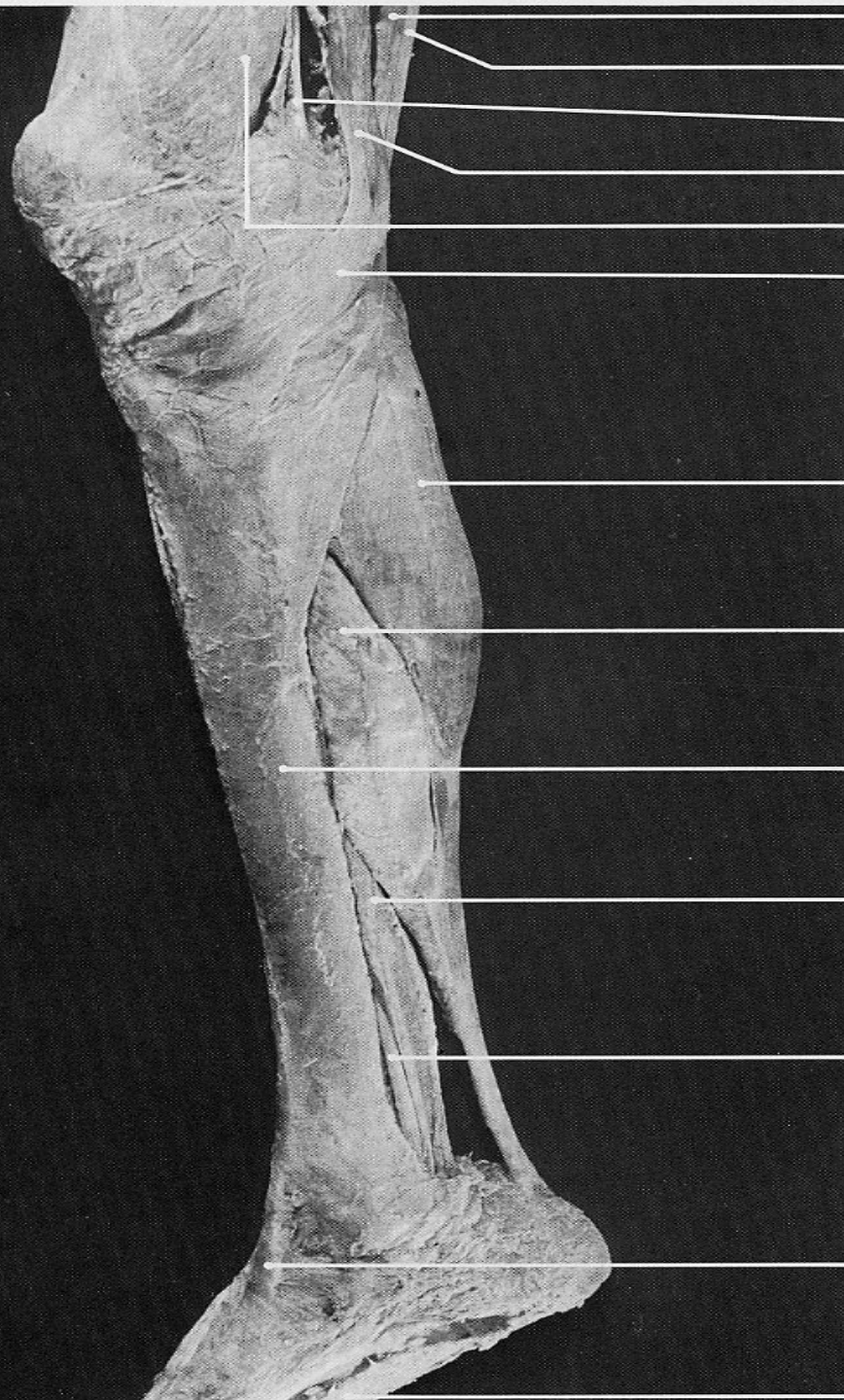
tendo Achillis

gastrocnemius  
(medial head)

gastrocnemius  
(lateral head)

pin insertion s  
for **soleus**





semimembranosus

semitendinosus (tendon)

adductor magnus (tendon)

gracilis (tendon)

vastus medialis

pes anserinus

gastrocnemius (medial head)

soleus (tibial origin)

anteromedial surface of tibia

flexor digitorum longus

tibialis posterior (tendon)

tibialis anterior (tendon)

plantar aponeurosis

# SOLEUS

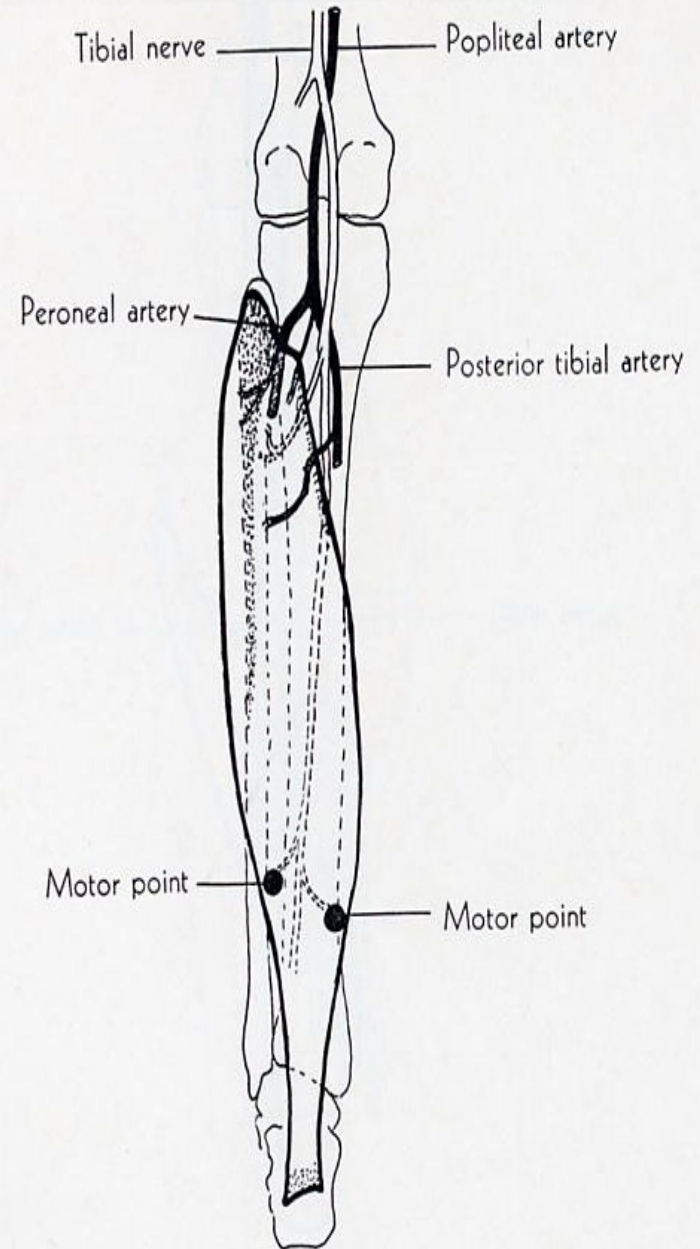
**ORIGIN:** posterior surface of head and upper third of shaft of fibula, middle third of medial border of tibia, tendinous arch between tibia and fibula.

**INSERTION:** into calcaneus by calcaneal tendon.

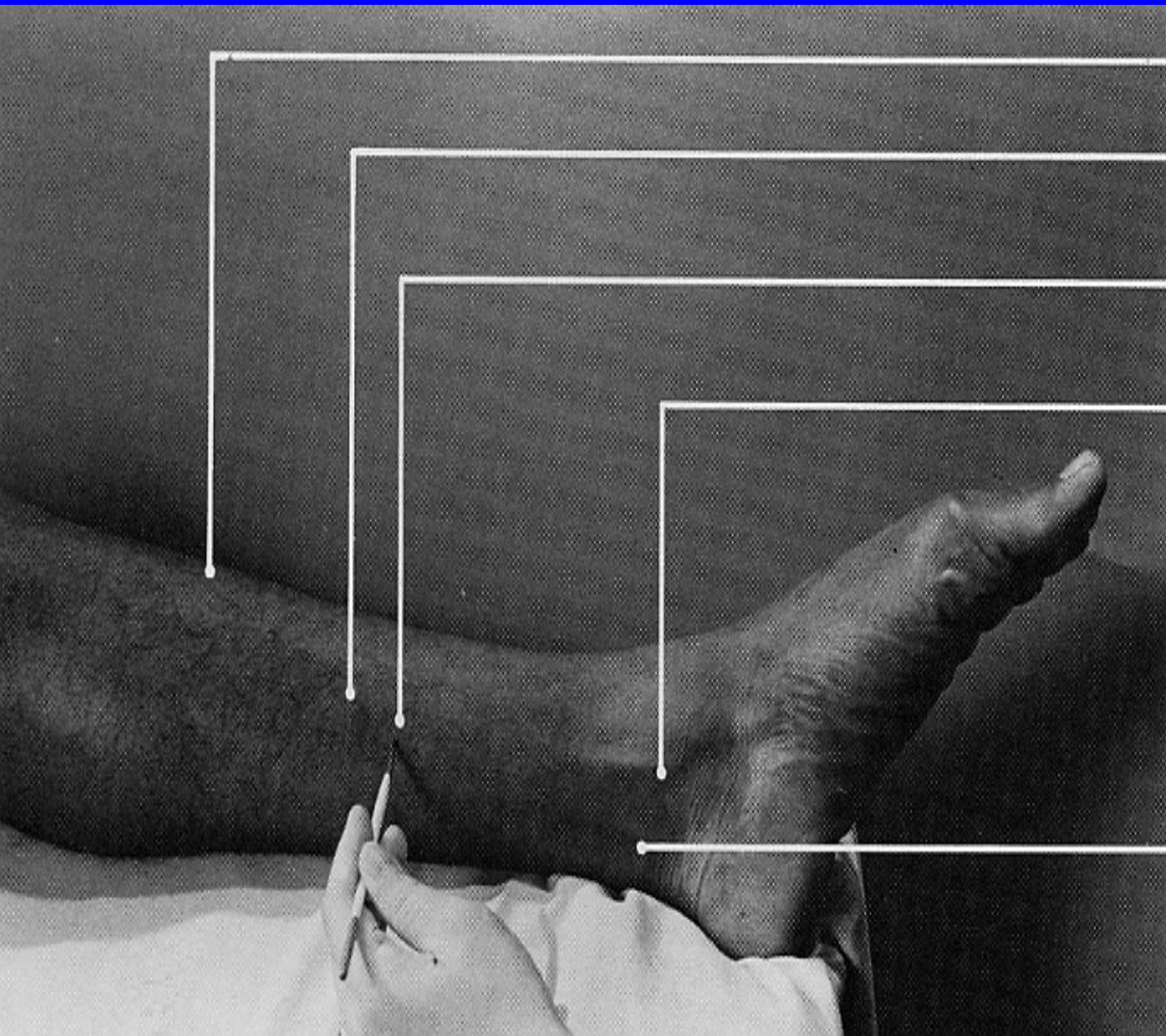
**ACTION:** plantarflexes foot, steadies leg upon foot.

**NERVE:** tibial.

**ROOT:** S1 and S2 mainly S1.







anterior margin of tibia

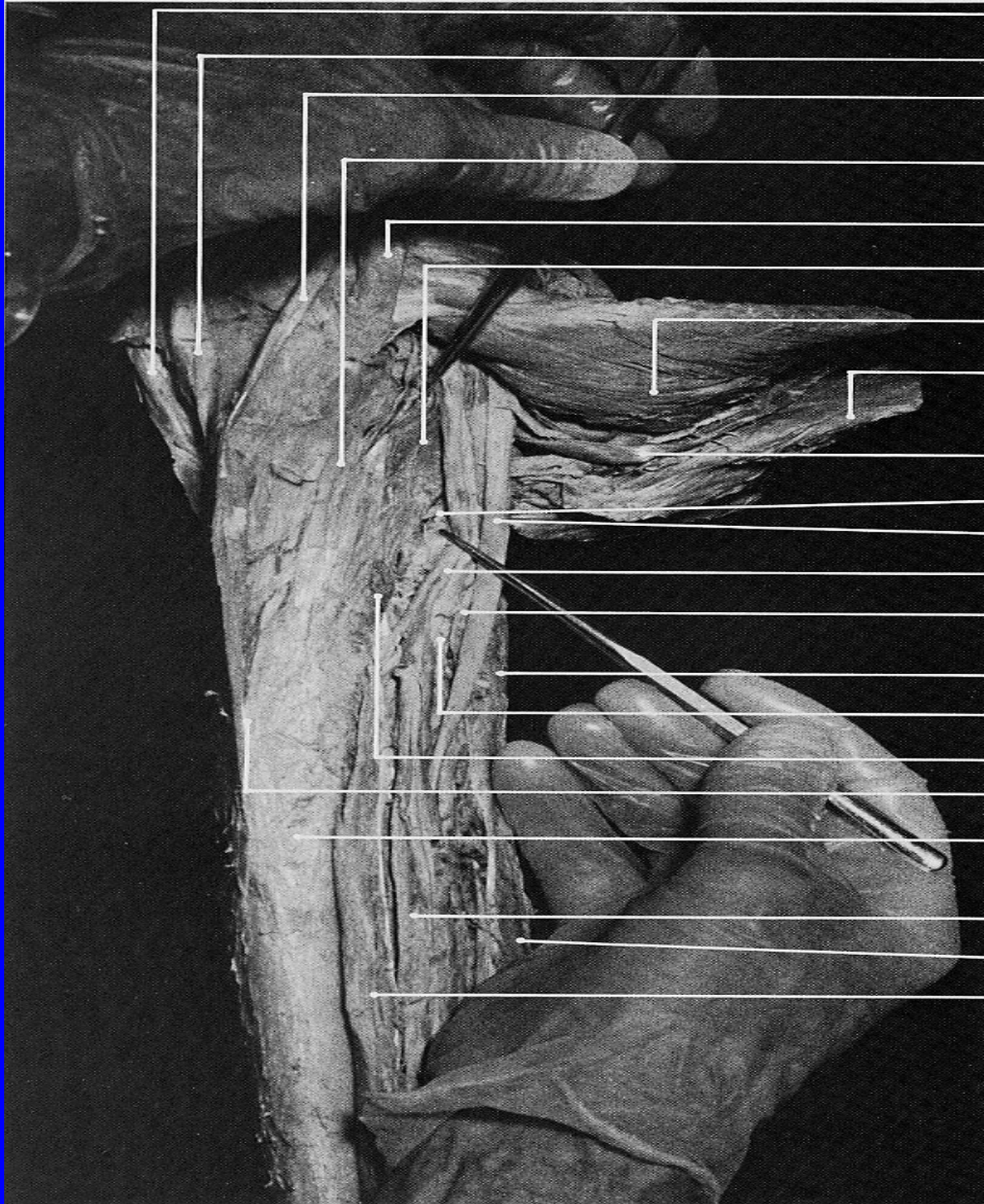
medial border of tibia

pin insertion site for  
**flexor digitorum longus**

tibialis posterior (tendon)

**flexor digitorum longus**  
(tendon)





sartorius (tendon)

gracilis (tendon)

semitendinosus (tendon)

fascial expansion from tendon  
of semimembranosus,  
which overlies popliteus

semimembranosus (tendon)

popliteus

deep surface of gastrocnemius  
(medial head)

soleus

plantaris

branch of tibial n. to popliteus

tibial n.

posterior tibial v.

posterior tibial v.

soleus (fibular origin, cut off)

posterior tibial a.

soleus (tibial origin, cut off)

posteromedial border of tibia

posterior surface of tibia

posterior tibial vessels

flexor hallucis longus

flexor digitorum longus



# FLEXOR DIGITORUM LONGUS

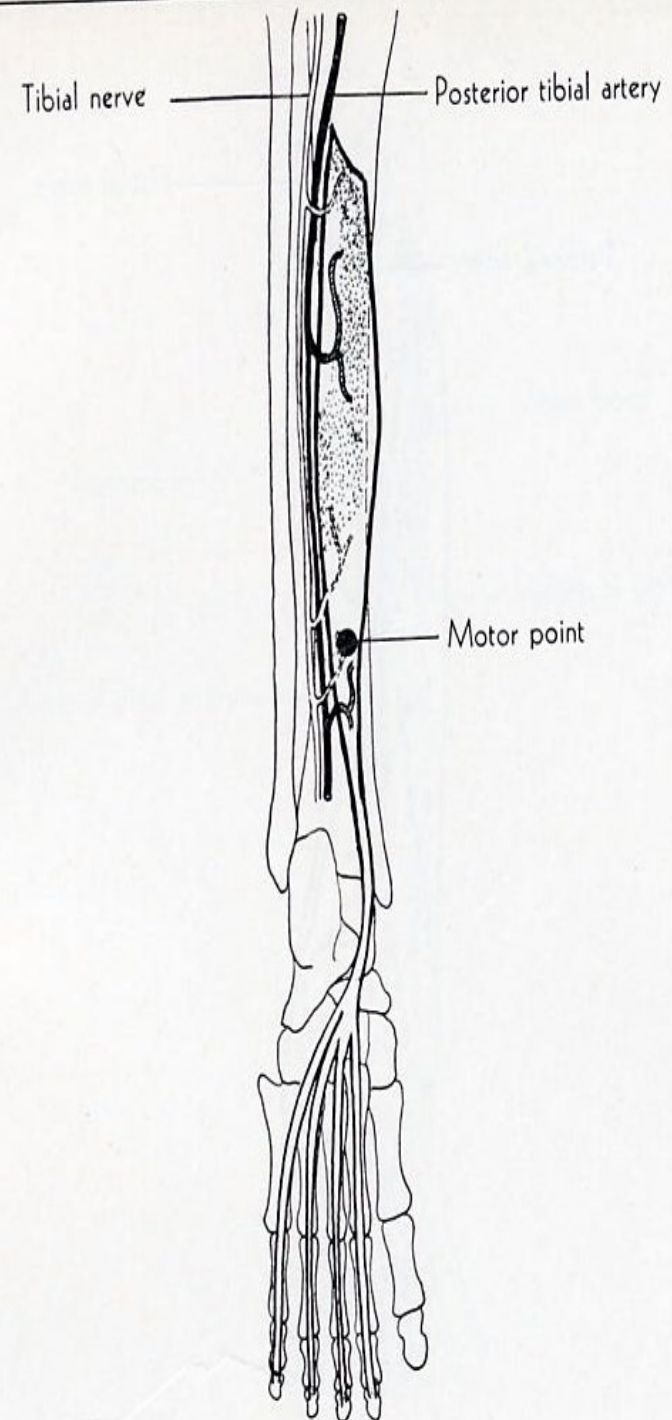
**ORIGIN:** posterior surface of middle 3/5 of tibia, fascia covering tibialis posterior.

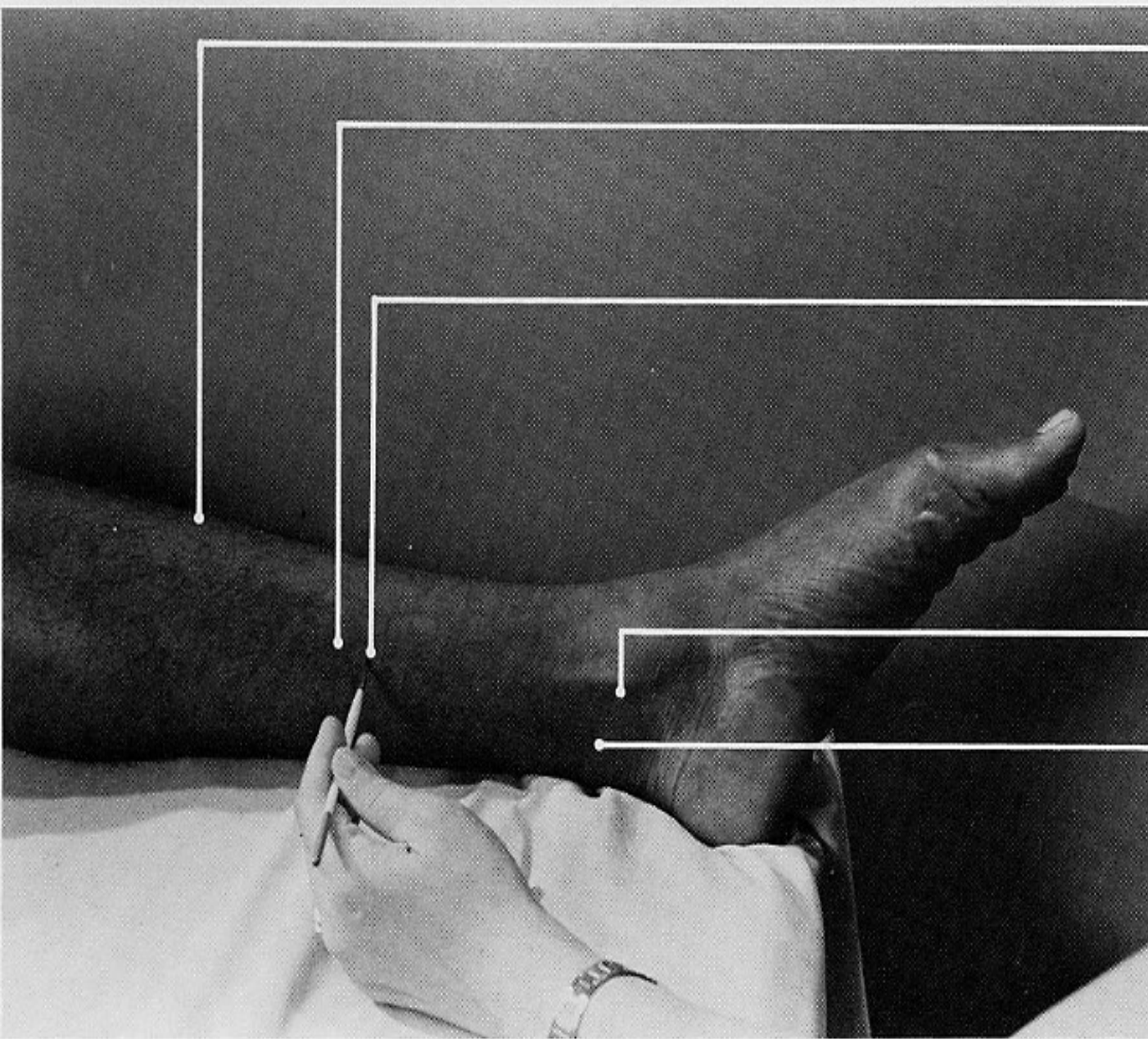
**INSERTION:** plantar surface of base of distal phalanx of lateral 4 toes.

**ACTION:** flexes phalanges, continued action plantar flexes foot.

**NERVE:** tibial.

**ROOT:** L5, S1 and S2 mainly at L5 but S1 may dominate.





anterior margin of tibia

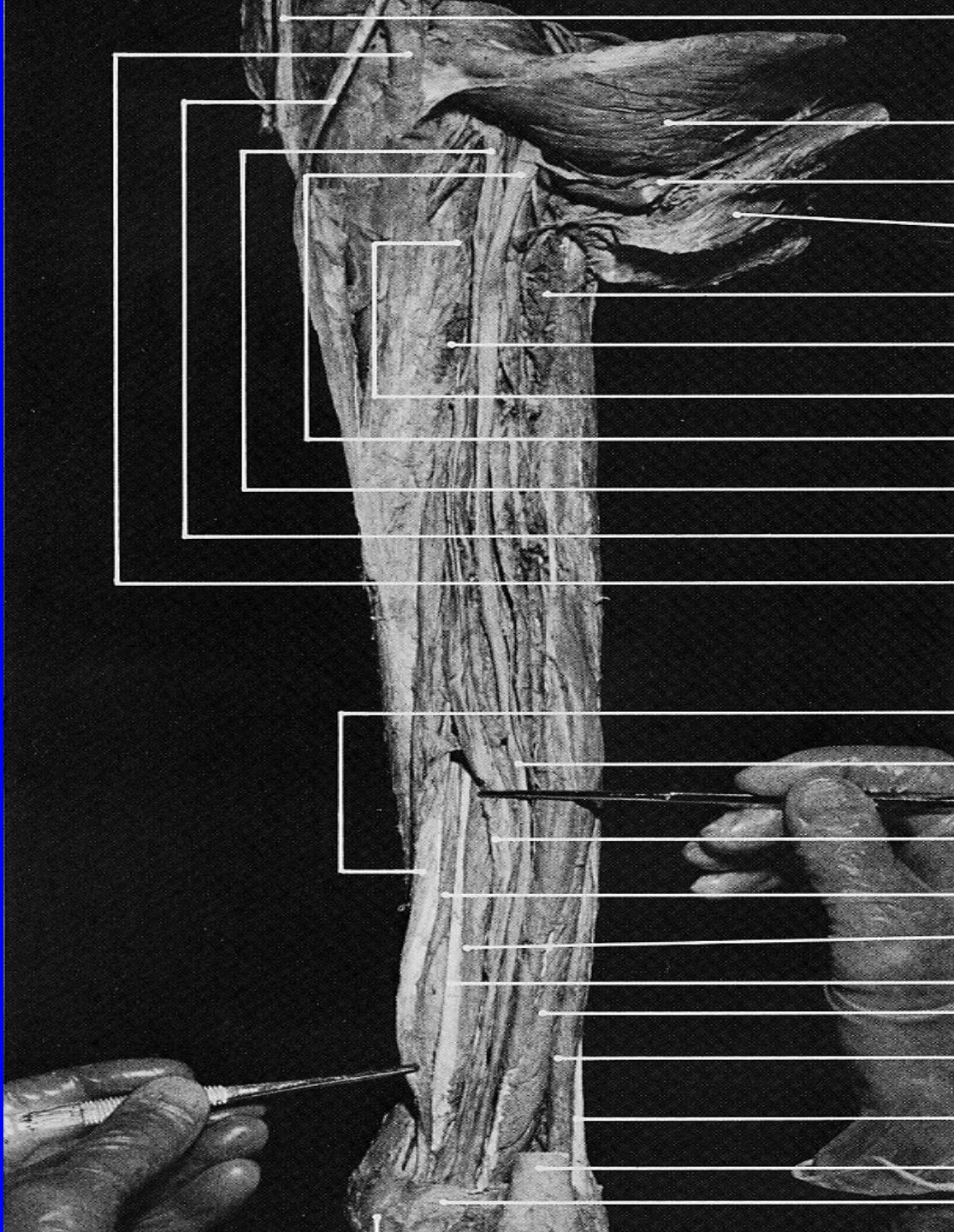
medial border of tibia

Pin insertion at this site with penetration of the pin through the flexor digitorum longus will reach the **tibialis posterior**.

**tibialis posterior**  
(tendon)

flexor digitorum longus  
(tendon)





gracilis (tendon)

deep surface of gastrocnemius  
(medial head)

plantaris

soleus (reflected upward)

soleus (fibular origin, cut off)

soleus (tibial origin, cut off)

popliteus

tibial n.

posterior tibial vessels

semitendinosus (tendon)

semimembranosus (tendon)

flexor digitorum longus (tendon)

tibial n.

posterior tibial vessels

flexor digitorum longus (belly)

tibialis posterior (belly)

tibialis posterior (tendon)

flexor hallucis longus

peroneus brevis (posterior border)

peroneus longus (tendon)

tendo Achillis (cut off)

flexor retinaculum

# TIBIALIS POSTERIOR

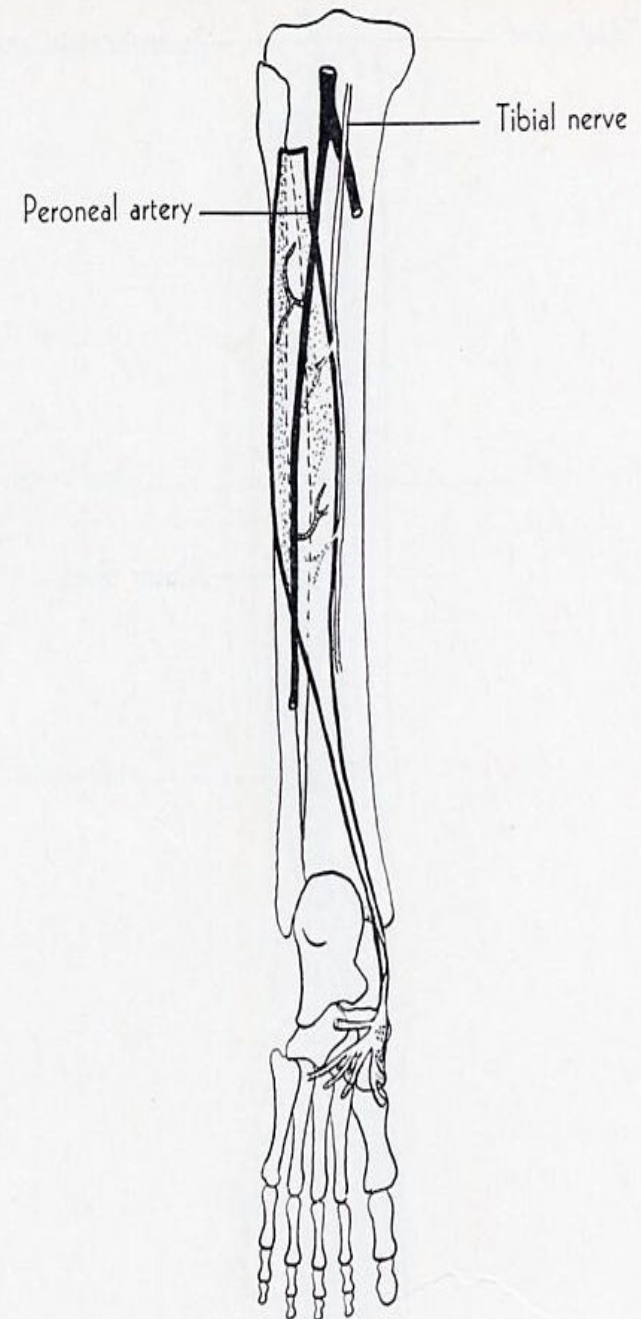
**ORIGIN:** lateral part of posterior surface of tibia, upper 2/3 of medial surface of fibula, deep transverse fascia, adjacent intermuscular septa, posterior surface of interosseous membrane.

**INSERTION:** tuberosity of navicular bone, plantar surface of all cuneiform bones, plantar surface of base of 2<sup>nd</sup>, 3<sup>rd</sup> and 4<sup>th</sup> metatarsal bones, cuboid bone, sustentaculum tali.

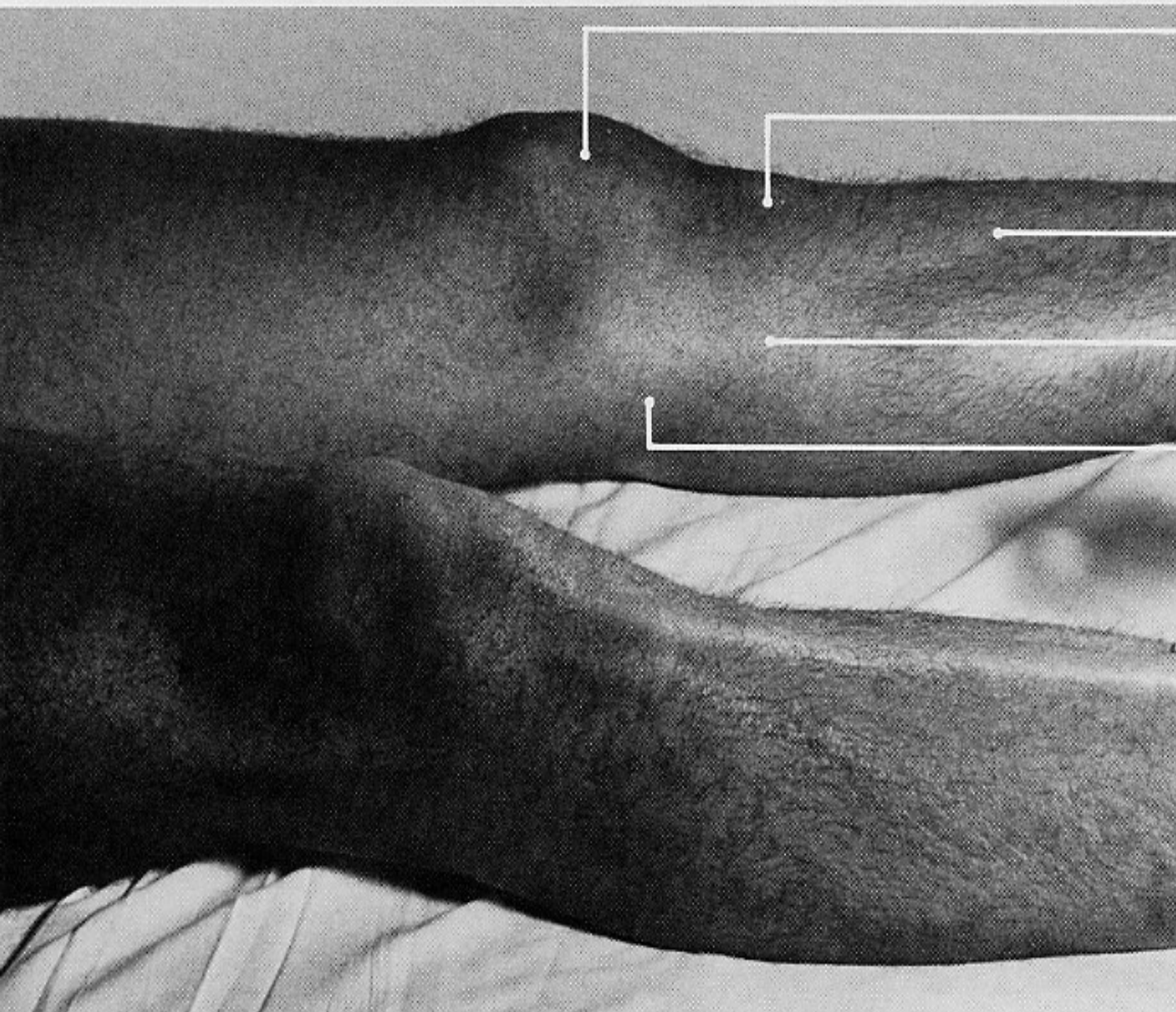
**ACTION:** plantar flexes foot, inverts it.

**NERVE:** tibial.

**ROOT:** L5 and S1, mainly L5.







patella

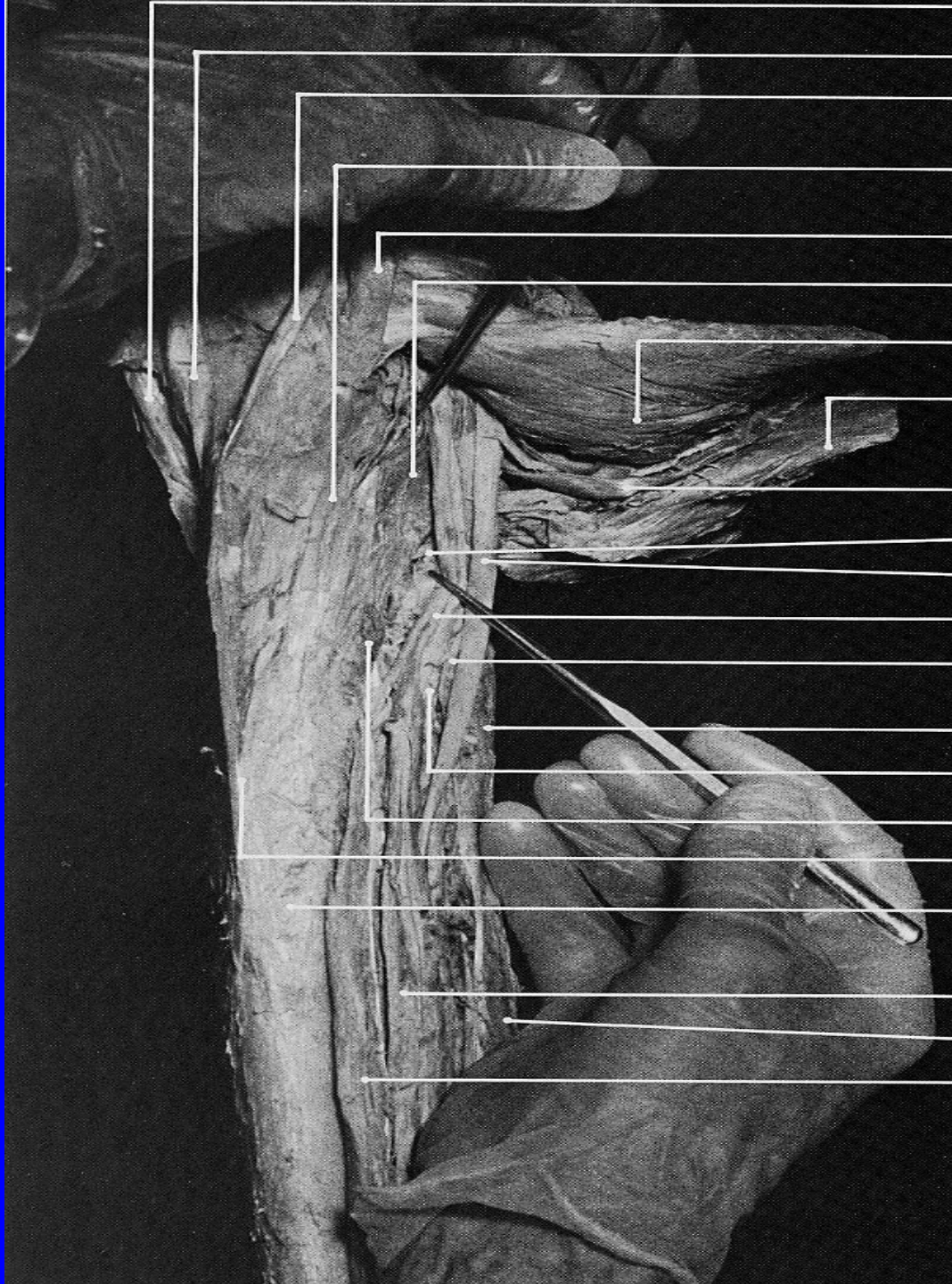
tibial tuberosity

tibialis anterior

pin insertion site  
for **popliteus**

medial femoral condyle





sartorius (tendon)

gracilis (tendon)

semitendinosus (tendon)

fascial expansion from tendon of semimembranosus, which overlies popliteus

semimembranosus (tendon)

popliteus

deep surface of gastrocnemius (medial head)

soleus

plantaris

branch of tibial n. to popliteus

tibial n.

posterior tibial v.

posterior tibial v.

soleus (fibular origin, cut off)

posterior tibial a.

soleus (tibial origin, cut off)

posteromedial border of tibia

posterior surface of tibia

posterior tibial vessels

flexor hallucis longus

flexor digitorum longus



# POPLITEUS

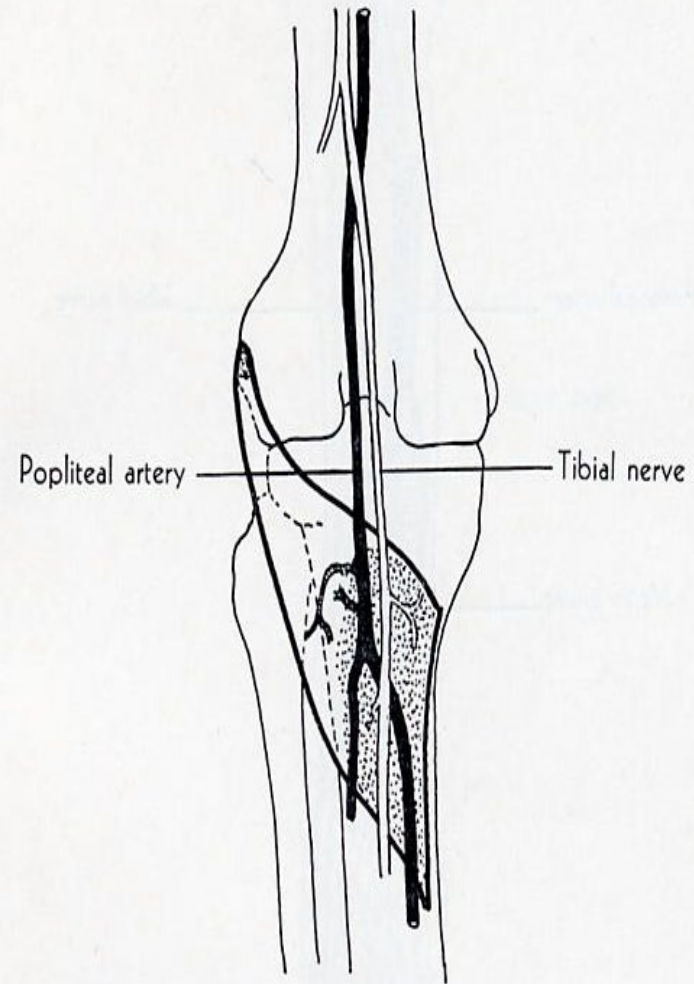
**ORIGIN:** lateral condyle of femur, oblique popliteal ligament of knee.

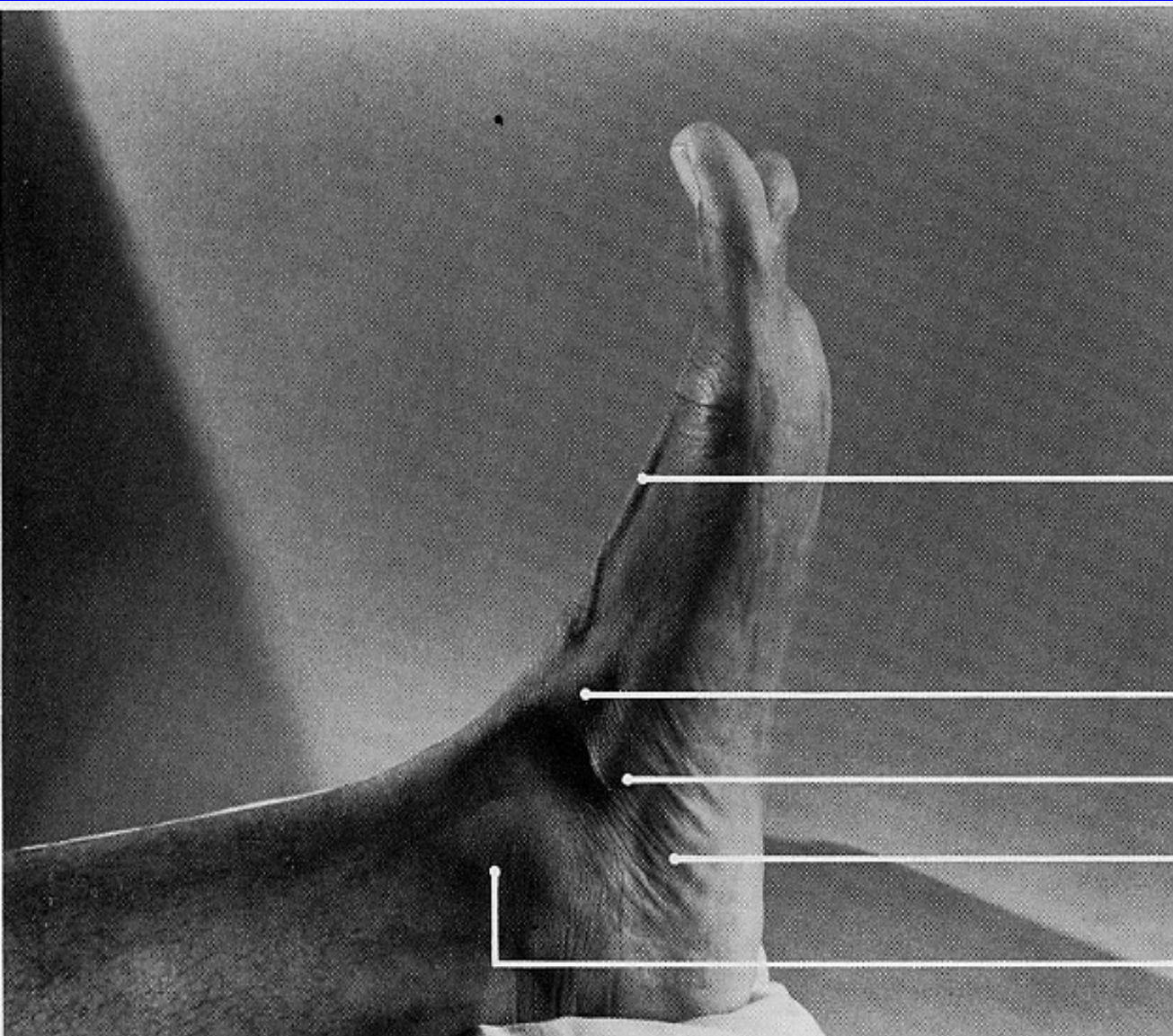
**INSERTION:** triangular area on posterior surface of tibia above soleal line.

**ACTION:** flexes leg, rotates tibia medially at beginning of flexion.

**NERVE:** tibial.

**ROOT:** L4, L5, S1, mainly L5.





extensor hallucis longus (tendon)

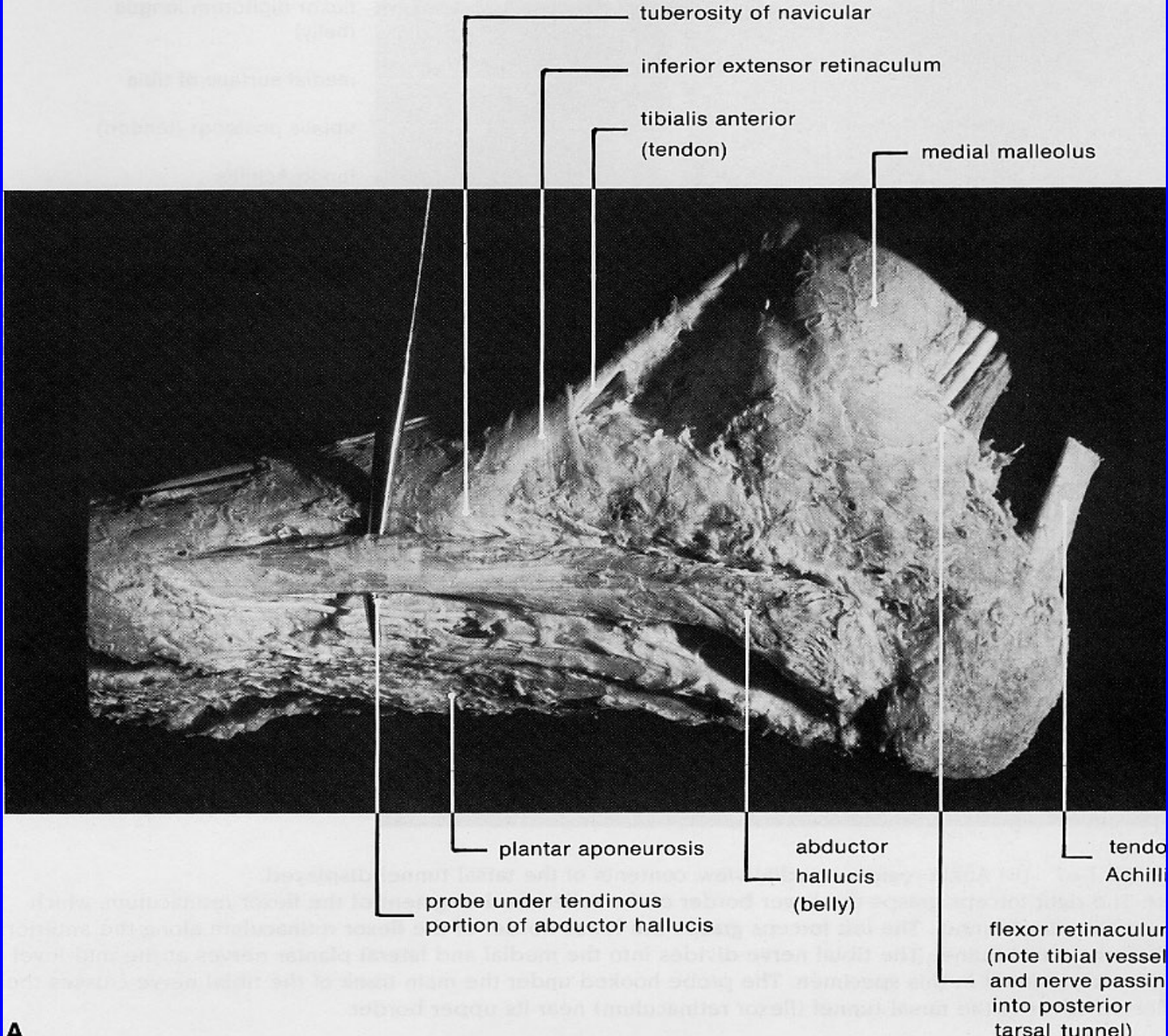
tibialis anterior (tendon)

navicular

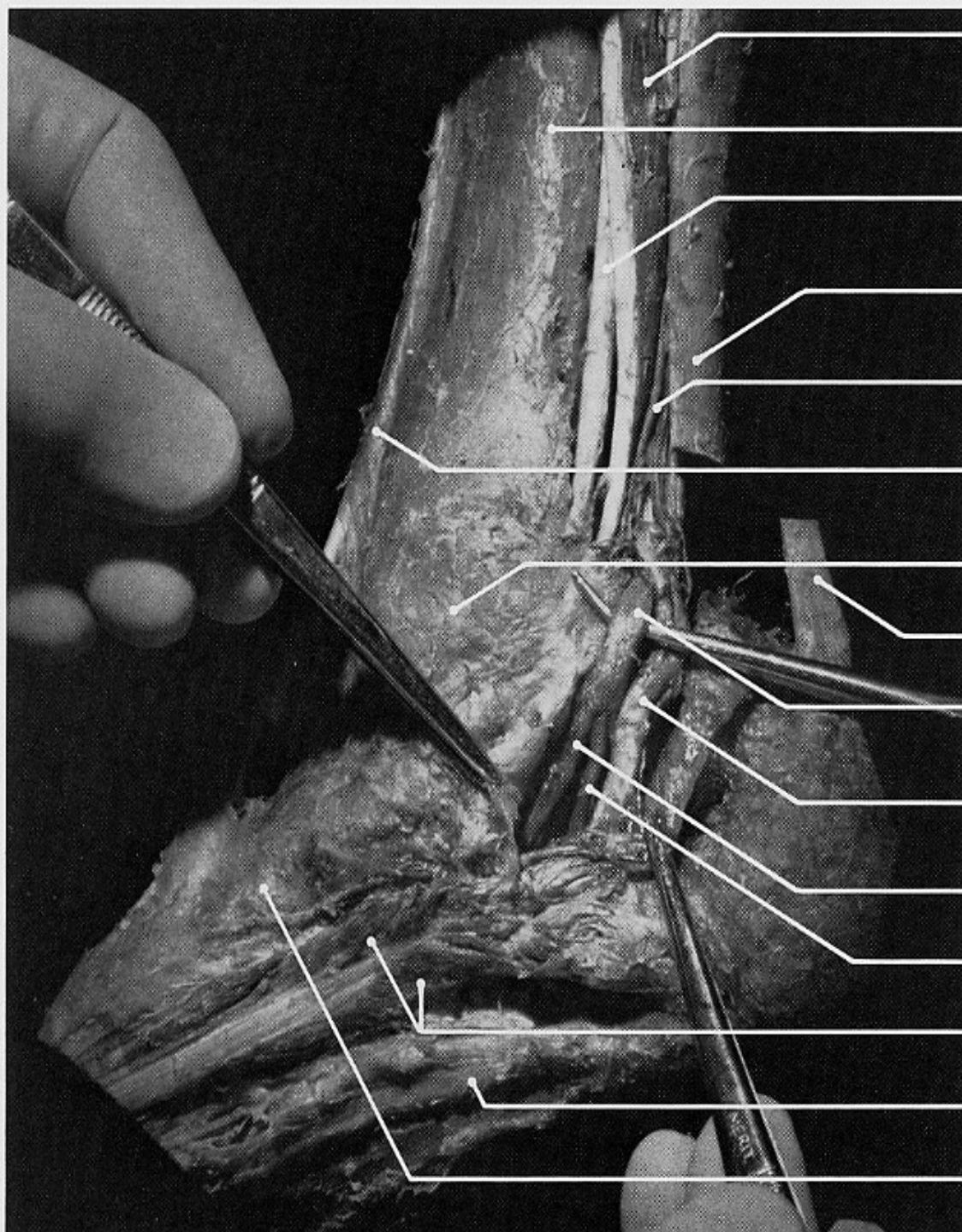
**abductor hallucis**

medial malleolus









flexor digitorum longus  
(belly)

medial surface of tibia

tibialis posterior (tendon)

tendo Achillis  
(severed and displaced)

venae comitantes

tibialis anterior (tendon) under  
superior extensor retinaculum

medial malleolus

tendo Achillis

tibial (posterior) n.

posterior tibial a.  
and venae comitantes

medial plantar n.

lateral plantar n.

abductor hallucis

plantar aponeurosis

tuberosity of navicular



# ABDUCTOR HALLUCIS

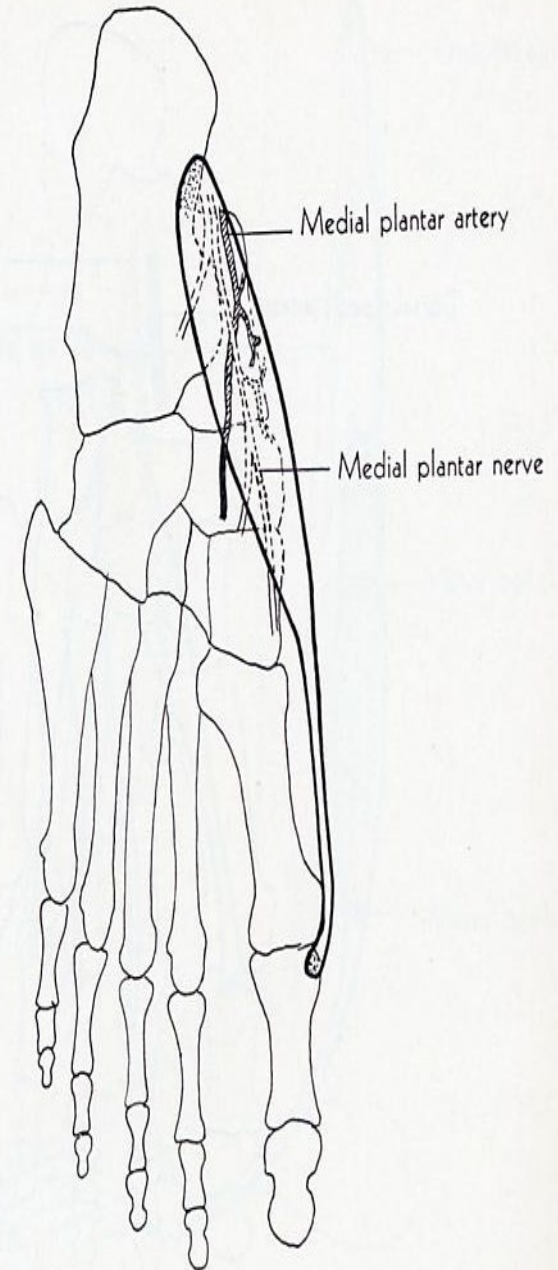
**ORIGIN:** medial process of calcaneus, laciniated ligament, plantar aponeurosis, adjacent intermuscular septum.


**INSERTION:** medial side of base of proximal phalanx of great toe.

**ACTION:** abducts great toe.

**NERVE:** medial plantar.

**ROOT:** S1 and S2 mainly S2.






pin insertion site for  
**abductor digiti minimi (quinti)**

tuberosity of 5th metatarsal

extensor digitorum brevis

lateral malleolus





extensor digitorum brevis

**abductor digiti minimi (quinti)**

peroneus longus (tendon)

lateral malleolus

cut end of  
tendo Achillis  
(displaced anteriorly)

peroneus longus and  
brevis (tendons)

superior extensor retinaculum

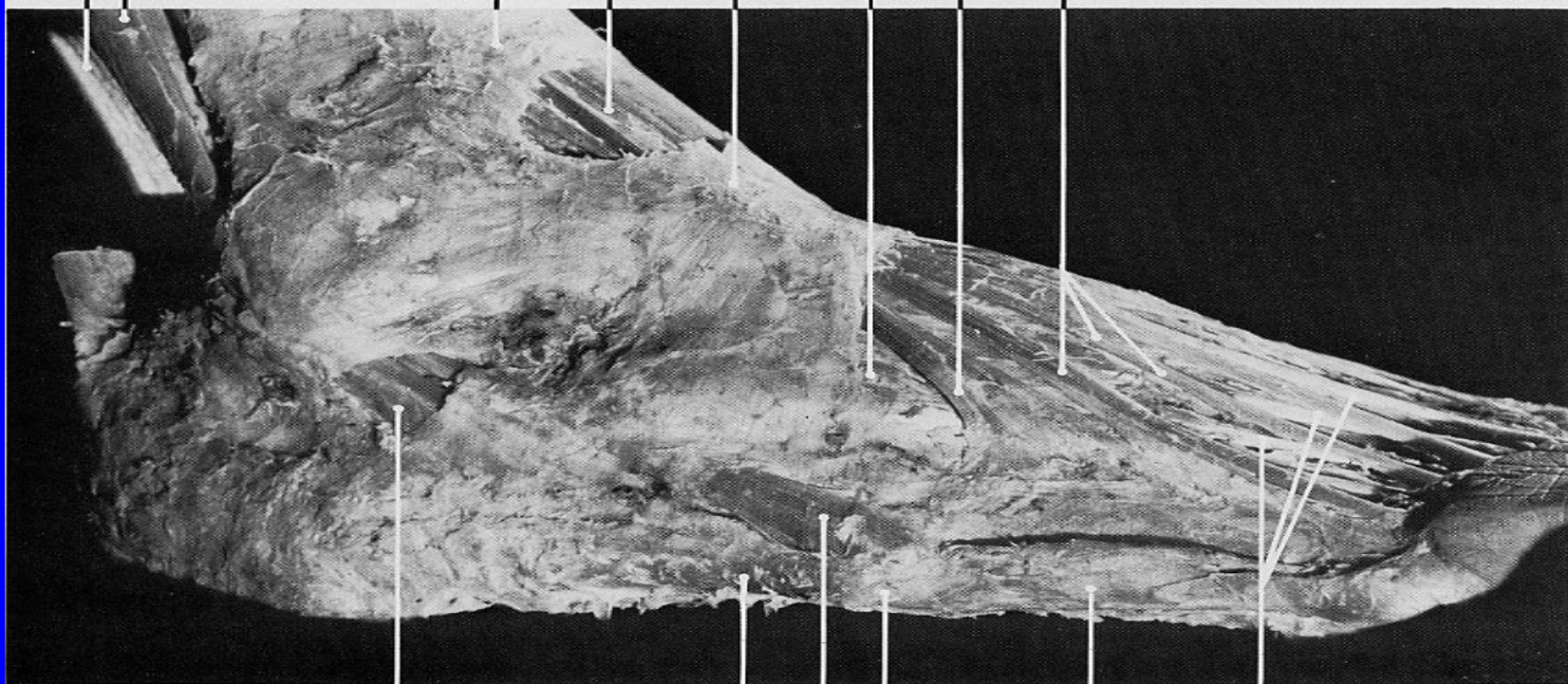
extensor digitorum longus (tendons)

inferior extensor retinaculum

extensor digitorum brevis  
(belly, largely covered  
by inferior extensor retinaculum)

peroneus tertius (tendon)

extensor digitorum longus (te



peroneus  
longus (tendon)

extensor digitorum  
brevis (tendons)

abductor digiti minimi

tuberosity of fifth metatarsal

peroneus brevis (tendon)

abductor digiti minimi



## ABDUCTOR DIGITI MINIMI

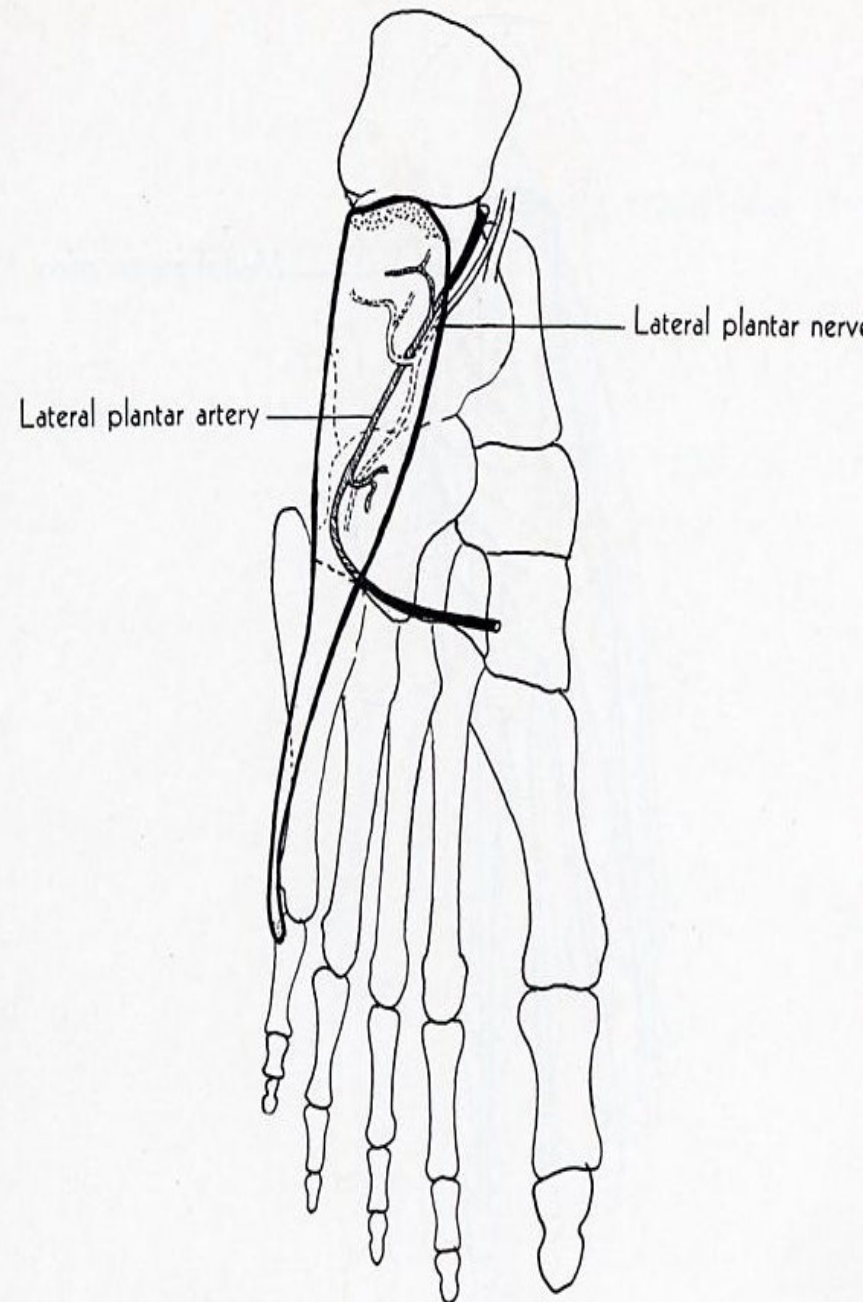
**ORIGIN:** lateral and medial processes of calcaneus, calcaneal fascia, adjacent intermuscular septum.

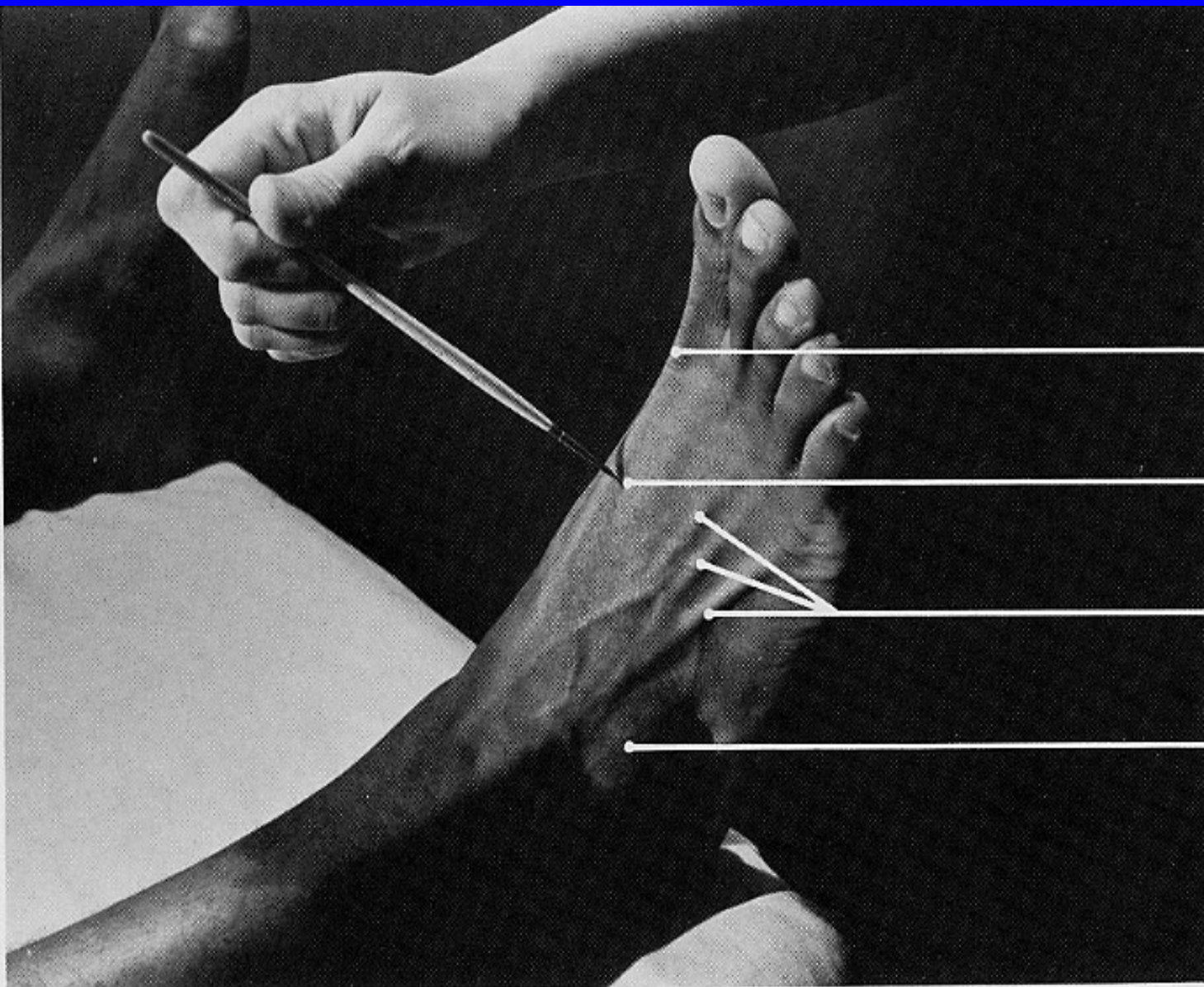
**INSERTION:** lateral side of base of proximal phalanx of little toe.

**ACTION:** abducts little toe, assists in flexing it.

**NERVE:** lateral plantar.

**ROOT:** S2 at S3 mainly S2.





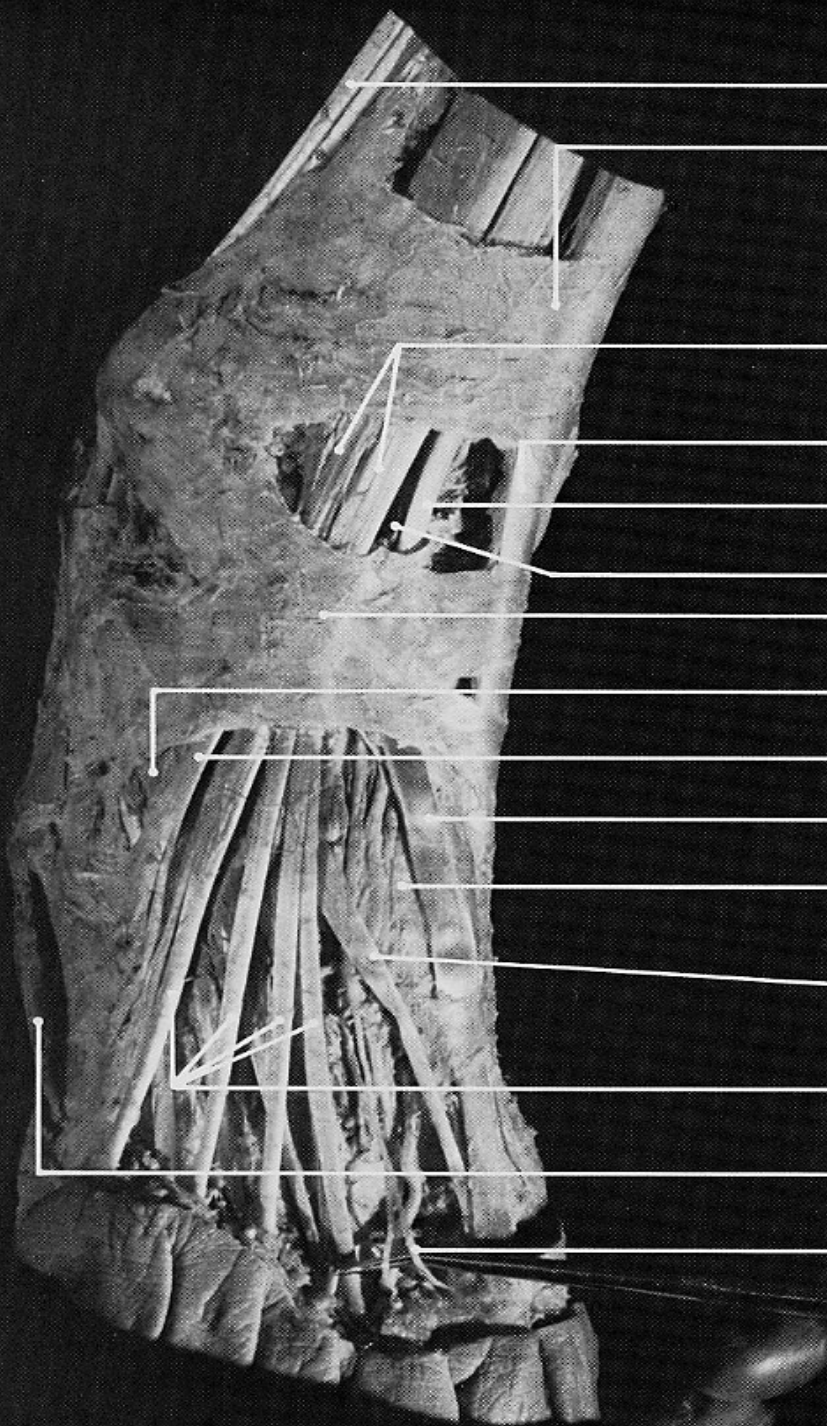
extensor hallucis longus  
(tendon)

pin insertion site for  
**first dorsal interosseous**

extensor digitorum longus  
(tendons)

extensor digitorum brevis





peroneus longus and brevis (tendons)

superior extensor retinaculum

extensor digitorum longus (tendons)

tibialis anterior (tendon)

extensor hallucis longus (tendon)

deep peroneal n.

inferior extensor retinaculum

extensor digitorum brevis (belly, largely covered by inferior extensor retinaculum)

peroneus tertius (tendon)

extensor hallucis longus (tendon)

first dorsal interosseus

extensor hallucis brevis (tendon), part of extensor digitorum brevis

extensor digitorum longus (tendons)

abductor digiti minimi

proper digital branch to big toe (from medial terminal branch of deep peroneal n.)

# DORSAL INTEROSSEI

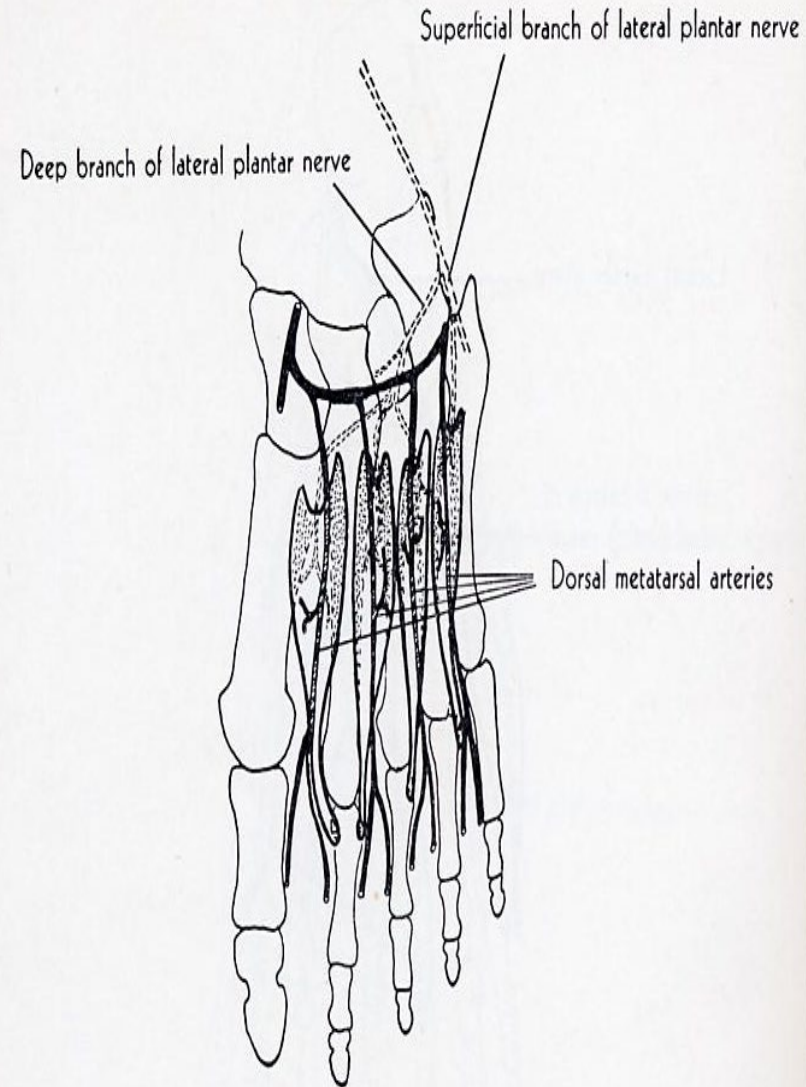
**ORIGIN:** 4 dorsal interossei, each arising by two heads from adjacent sides of metatarsal bones.

**INSERTION:** 1st into medial side of proximal phalanx of 2<sup>nd</sup> toe, 2<sup>nd</sup> into lateral side of proximal phalanx 2<sup>nd</sup> toe, 3<sup>rd</sup> into lateral side of proximal phalanx of 3<sup>rd</sup> toe, 4<sup>th</sup> into lateral side of proximal phalanx of 4<sup>th</sup> toe.

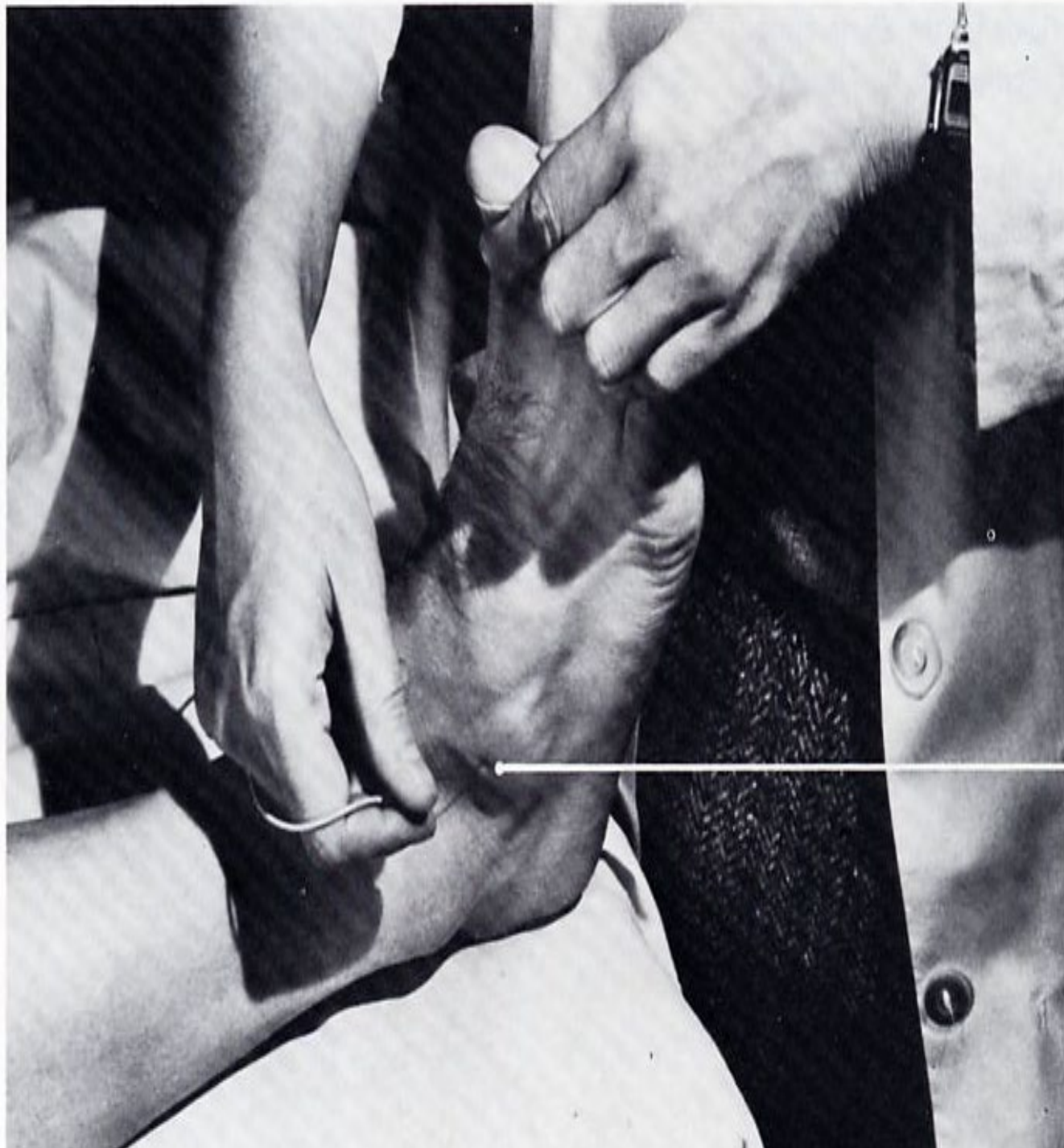**ACTION:** abducts 2<sup>nd</sup>, 3<sup>rd</sup>, 4<sup>th</sup> toes from axis of 2<sup>nd</sup> toe, assist in flexing proximal phalanges and in extending middle and distal phalanges.

**NERVE:** deep and superficial branches of lateral plantar.

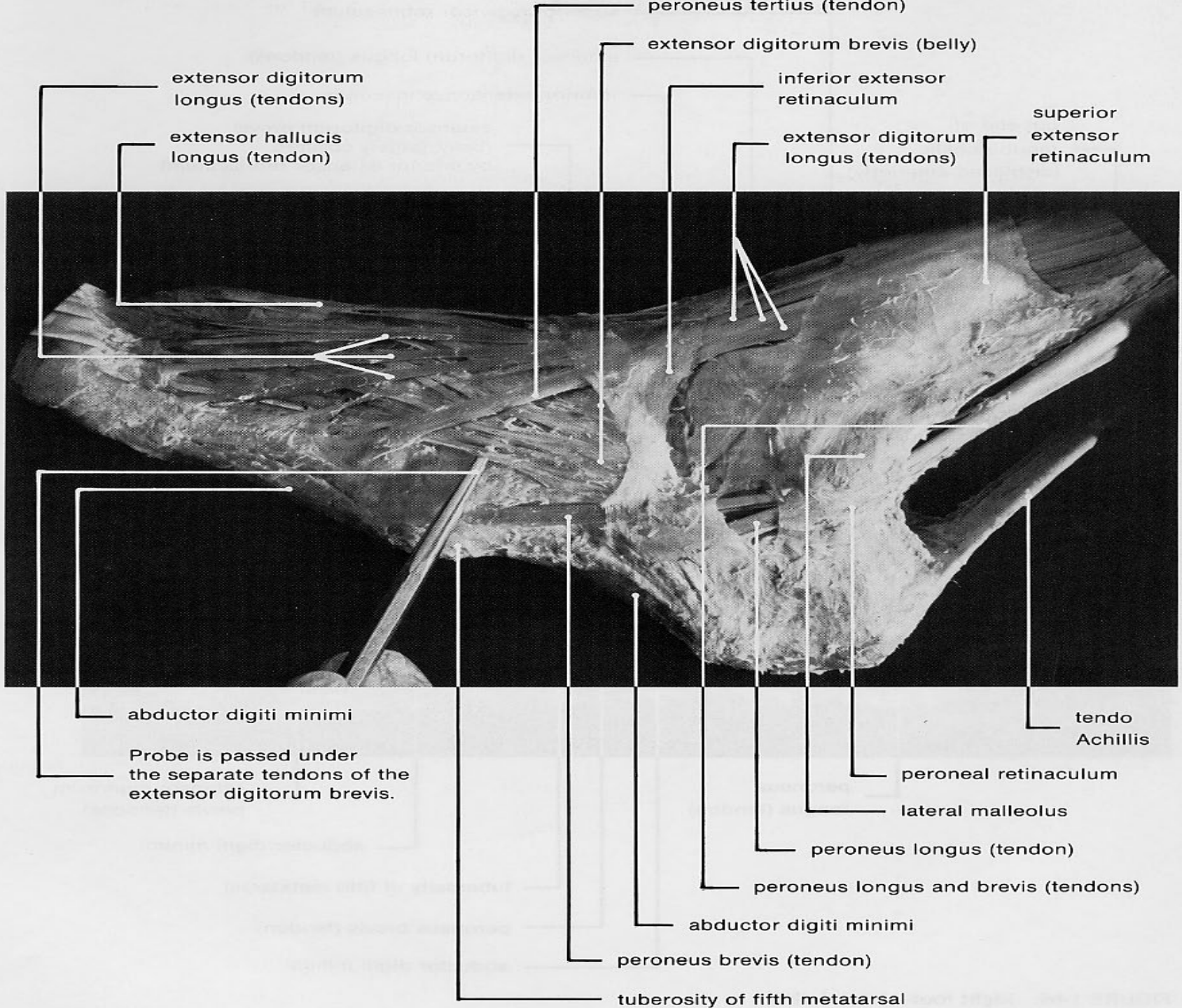
**ROOT:** S2, S3 mainly S2.







**extensor digitorum brevis**





# EXTENSOR DIGITORUM BREVIS

**ORIGIN:** forepart of upper and lateral surface of calcaneus, lateral talocalcaneal ligament, cruciate crural ligament.

**INSERTION:** 1<sup>st</sup> tendon into dorsal surface of base of proximal phalanx of great toe and remaining three tendons into lateral sides of tendons of extensor digitorum longus.

**ACTION:** extends phalanges of four medial toes.

**NERVE:** deep peroneal.

**ROOT:** L5, S1 mainly L5.

