

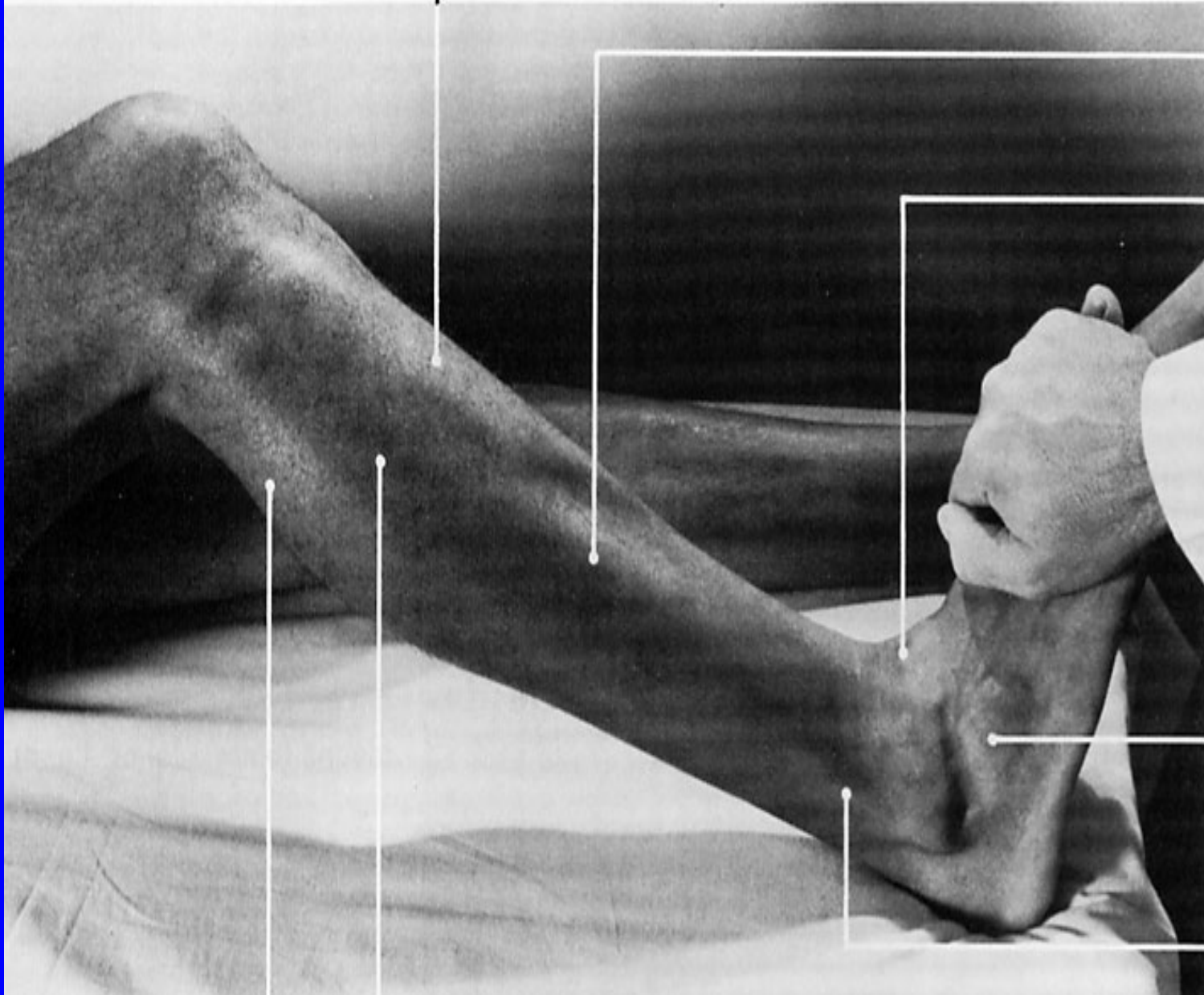
**tibialis anterior
(belly)**

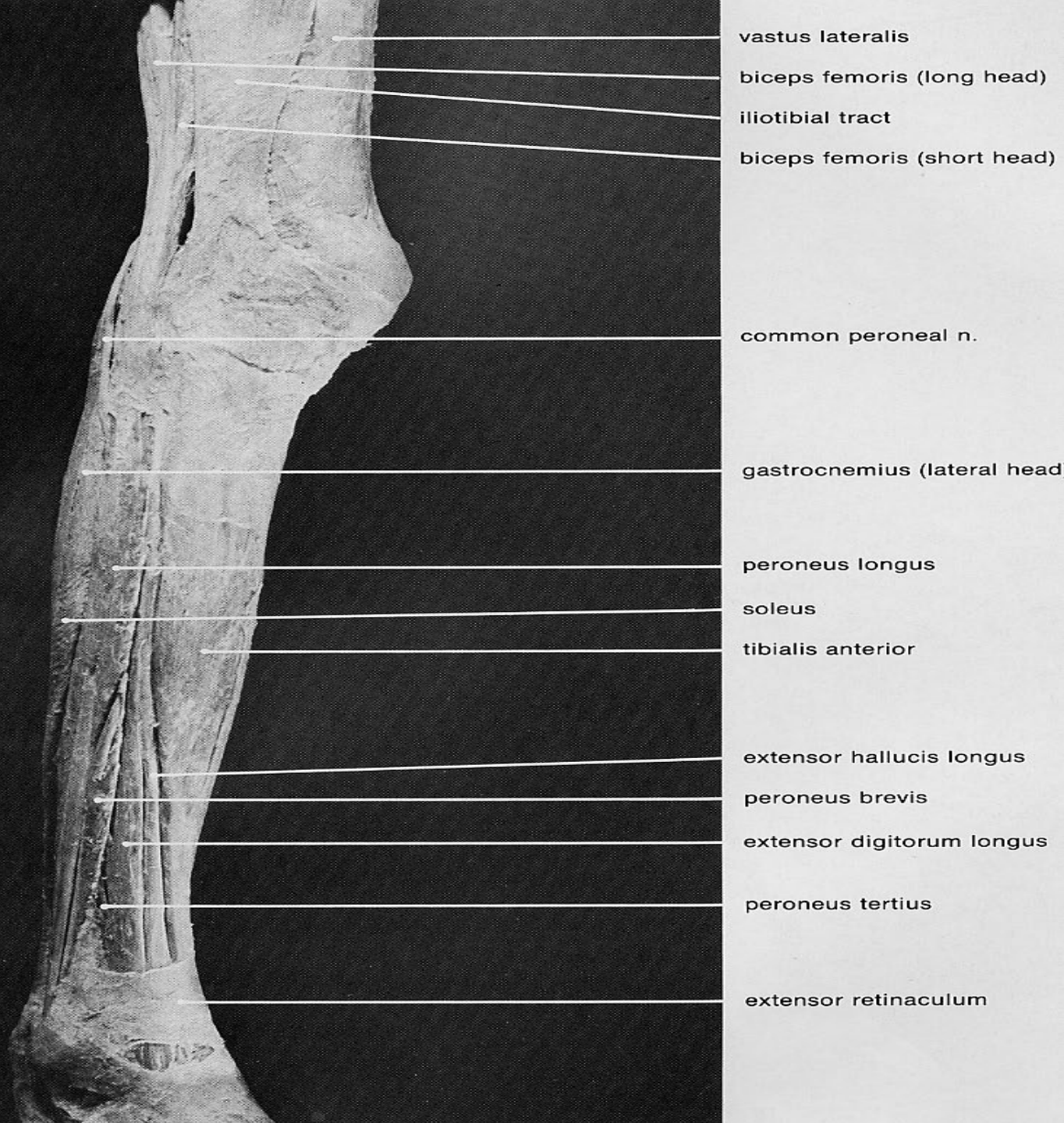**extensor digitorum
longus**

**tibialis anterior
(tendon)**

**extensor digitorum
brevis**

**peroneus longus
(tendon)**





vastus lateralis

biceps femoris (long head)

iliotibial tract

biceps femoris (short head)

common peroneal n.

gastrocnemius (lateral head)

peroneus longus

soleus

tibialis anterior

extensor hallucis longus

peroneus brevis

extensor digitorum longus

peroneus tertius

extensor retinaculum

TIBIALIS ANTERIOR

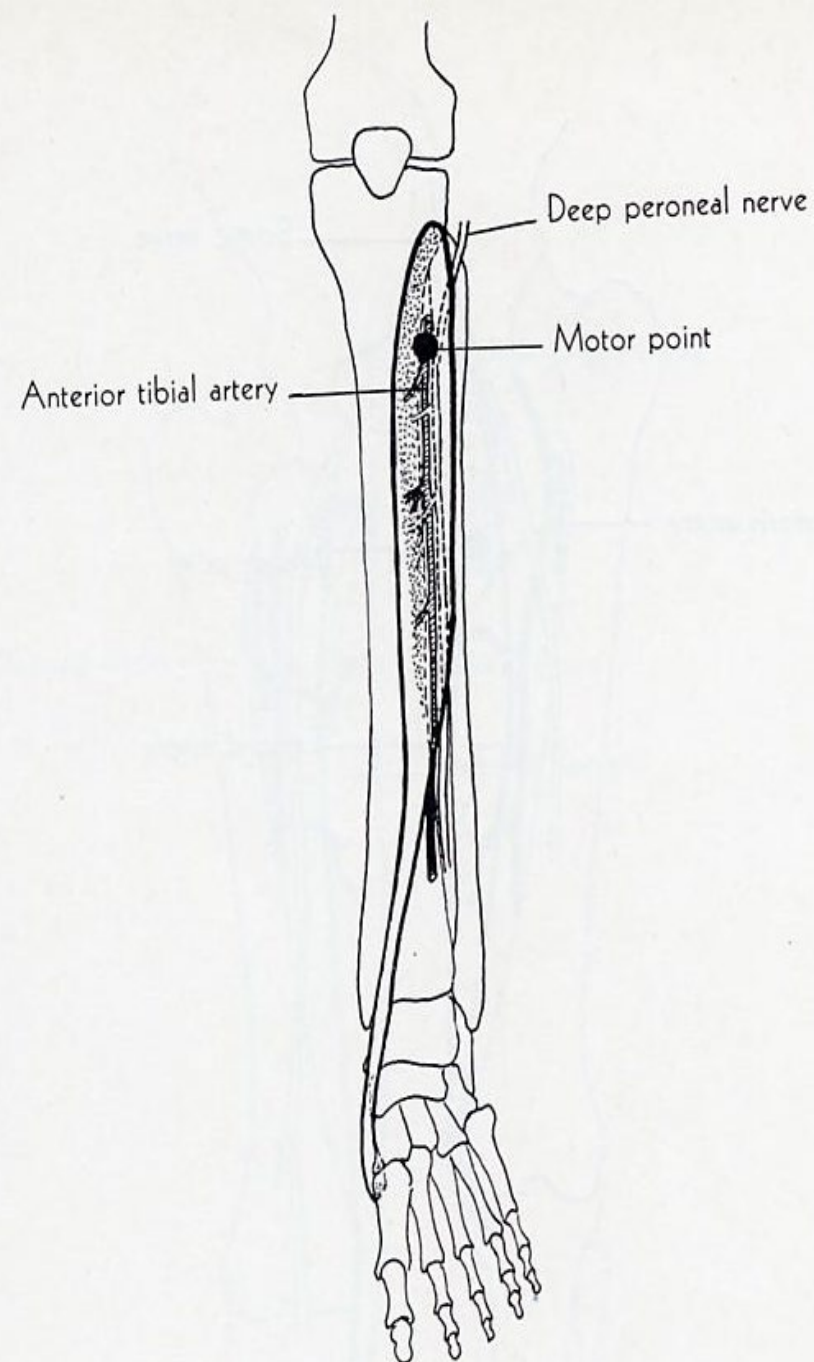
ORIGIN: lateral condyle of tibia, upper two thirds of lateral surface tibia, interosseous membrane, deep fascia, lateral intermuscular septum.

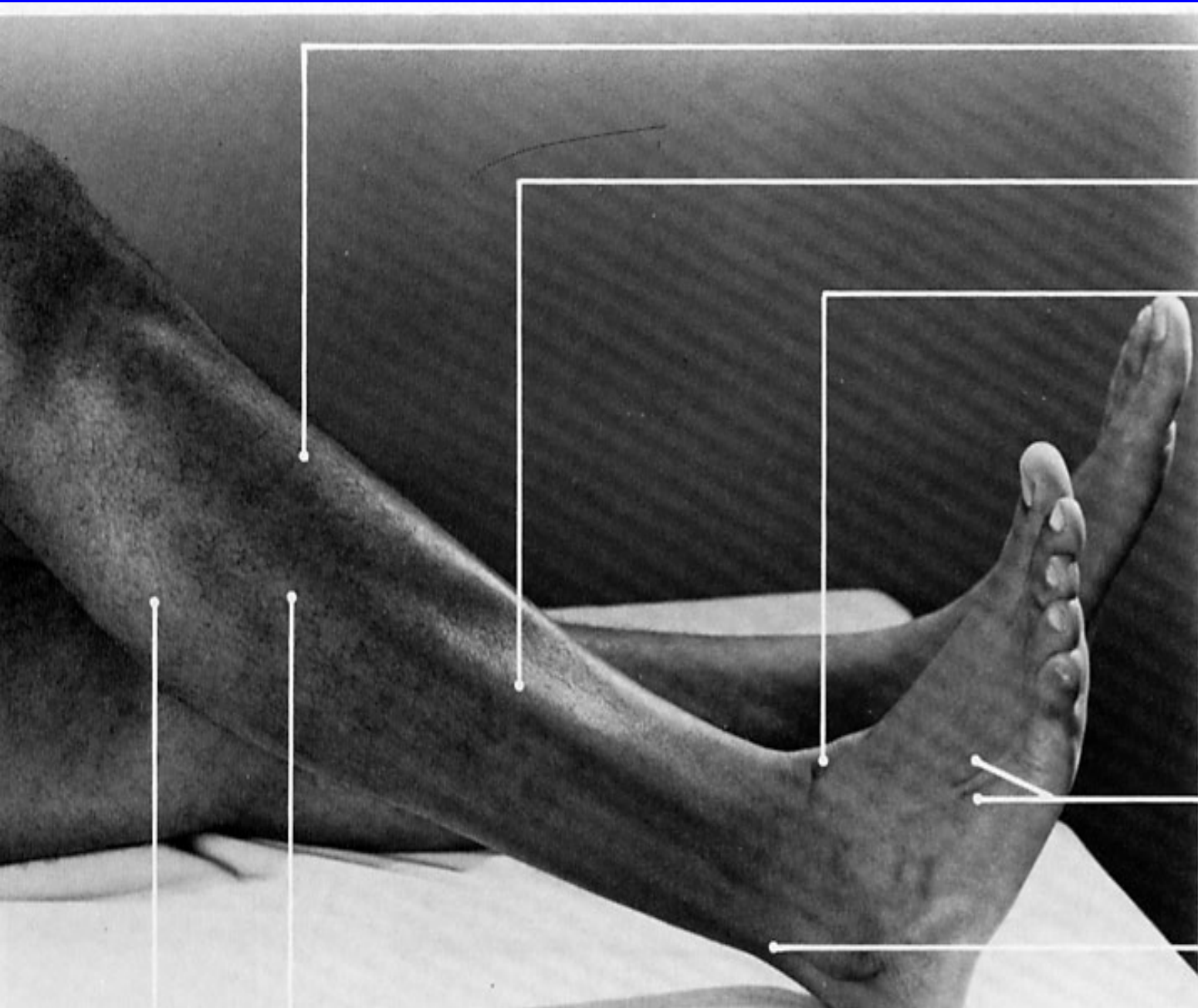
INSERTION: medial and plantar surface of medial cuneiform bone, base of 1st metatarsal bone.

ACTION: dorsiflexes foot, inverts it.

NERVE: deep peroneal

ROOT: L4, L5, mainly L5 but L4 may dominate.





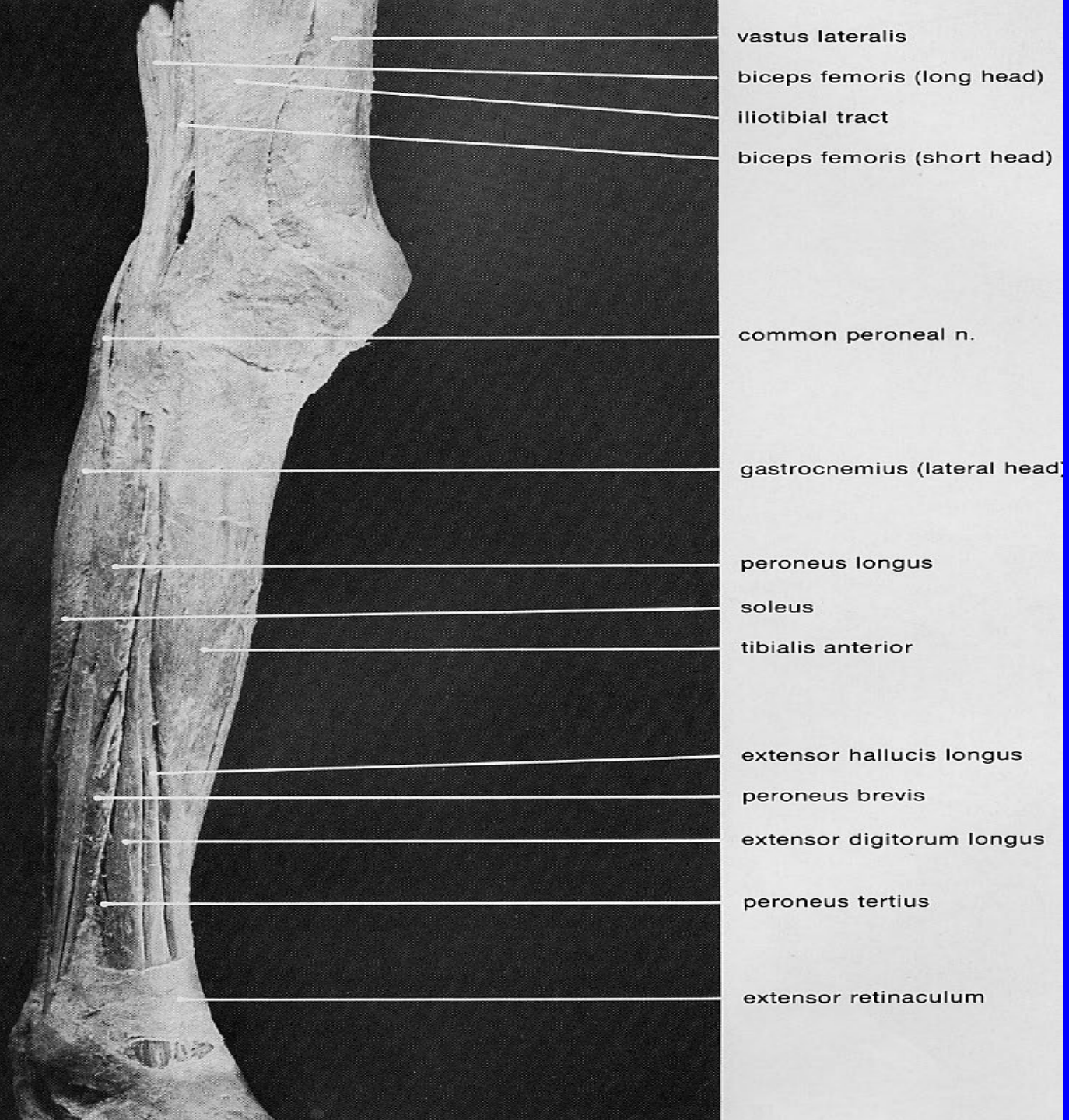
tibialis anterior
(belly)

**extensor digitorum
longus (belly)**

tibialis anterior
(tendon)

**extensor digitorum
longus (tendons)**

peroneus longus
(tendon)



vastus lateralis

biceps femoris (long head)

iliotibial tract

biceps femoris (short head)

common peroneal n.

gastrocnemius (lateral head)

peroneus longus

soleus

tibialis anterior

extensor hallucis longus

peroneus brevis

extensor digitorum longus

peroneus tertius

extensor retinaculum

EXTENSOR DIGITORUM LONGUS

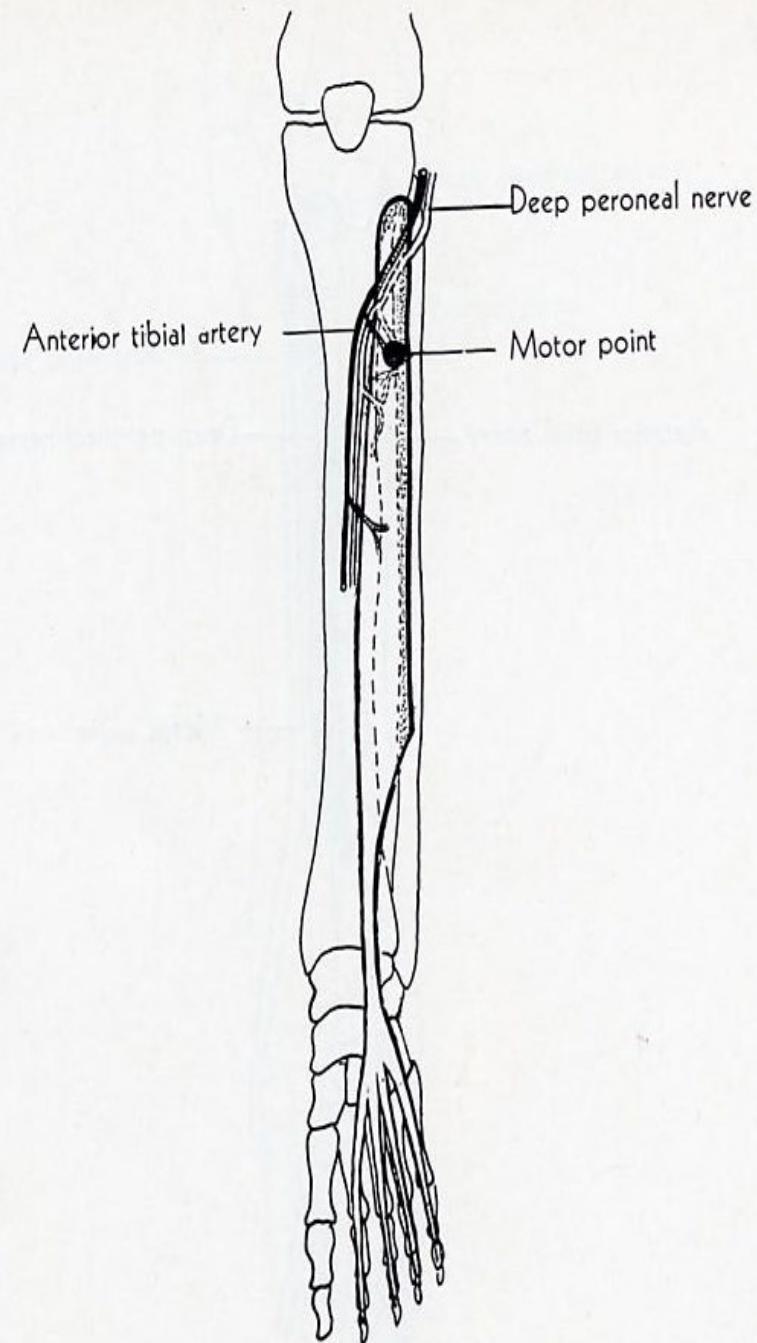
ORIGIN: lateral condyle of tibia, upper 3/4 of anterior surface fibula, interosseous membrane, deep fascia, lateral intermuscular septum.

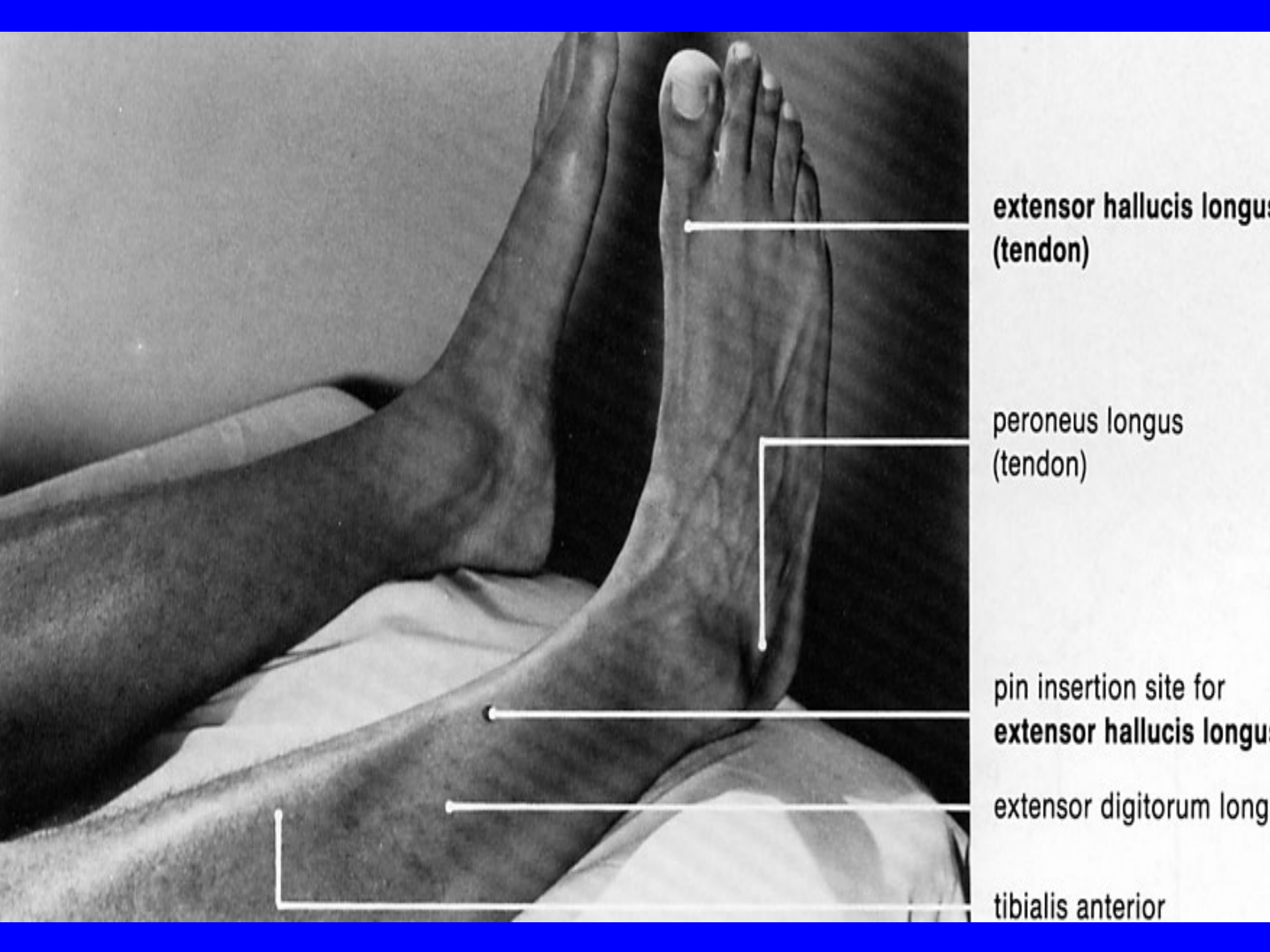
INSERTION: dorsal surface of middle and distal phalanges of 4 lateral toes.

ACTION: extends phalanges, continued action dorsiflexes foot.

NERVE: deep peroneal

ROOT: L5, S1 mainly L5.





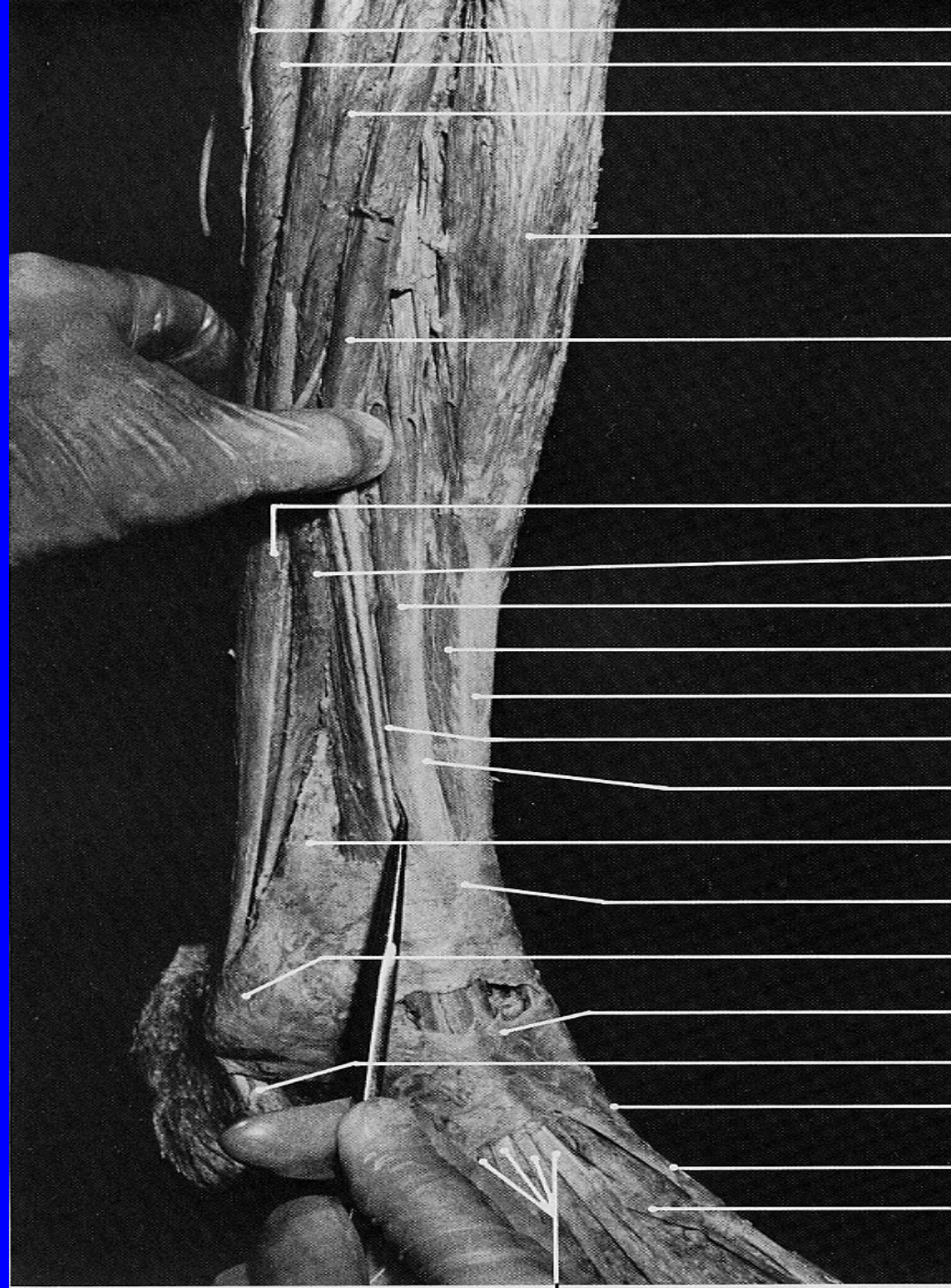**extensor hallucis longus
(tendon)**

**peroneus longus
(tendon)**

**pin insertion site for
extensor hallucis longus**

extensor digitorum longus

tibialis anterior



gastrocnemius (lateral head)

soleus (fibular origin)

peroneus longus (belly)

tibialis anterior (belly)

extensor digitorum longus
(belly, retracted laterally)

peroneus longus (tendon)

peroneus brevis

extensor hallucis longus (belly)

tibialis anterior (belly)

tibialis anterior (tendon)

deep peroneal n.

extensor hallucis longus (tendon)

fibula

superior extensor retinaculum

lateral malleolus

inferior extensor retinaculum

tendons of peroneus longus and brevis

tibialis anterior (tendon)

extensor hallucis longus (tendon)

extensor hallucis brevis (tendon)

EXTENSOR HALLUCIS LONGUS

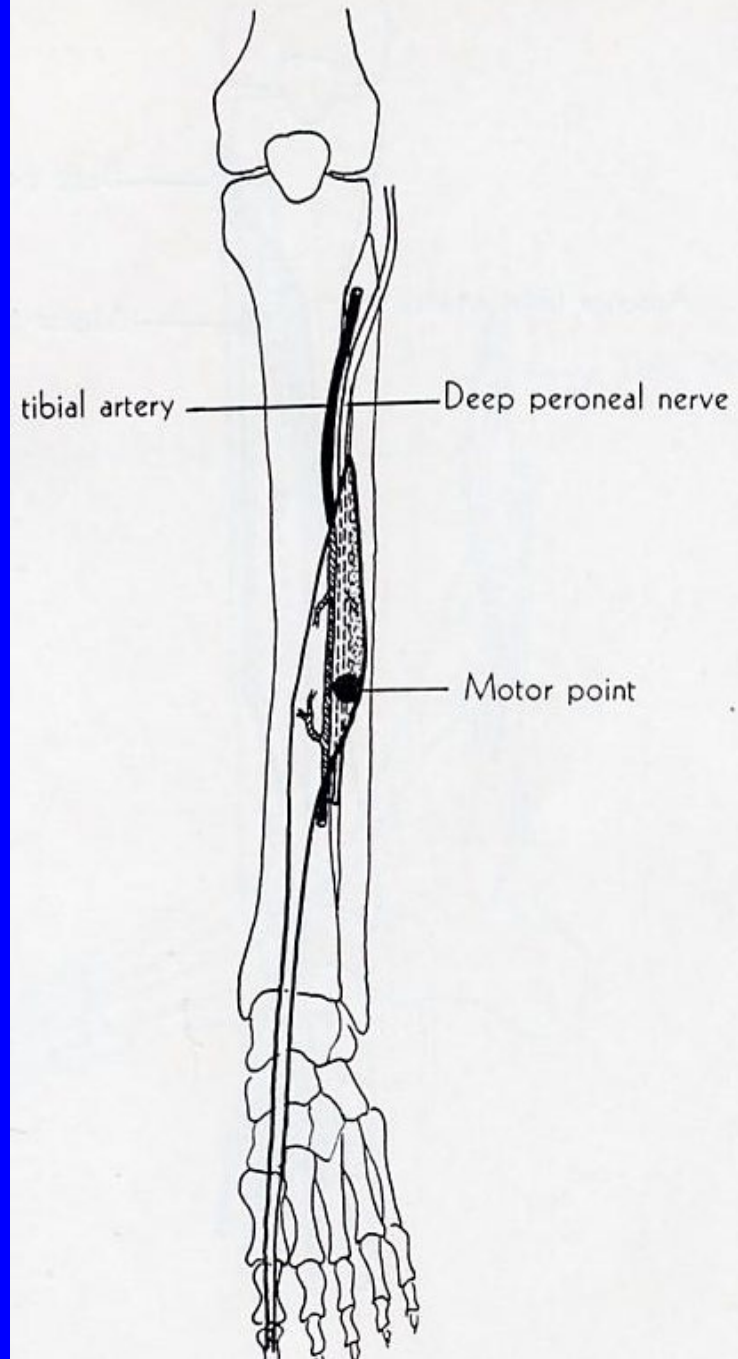
ORIGIN: middle 1/2 of anterior surface of fibula, adjacent interosseous membrane.

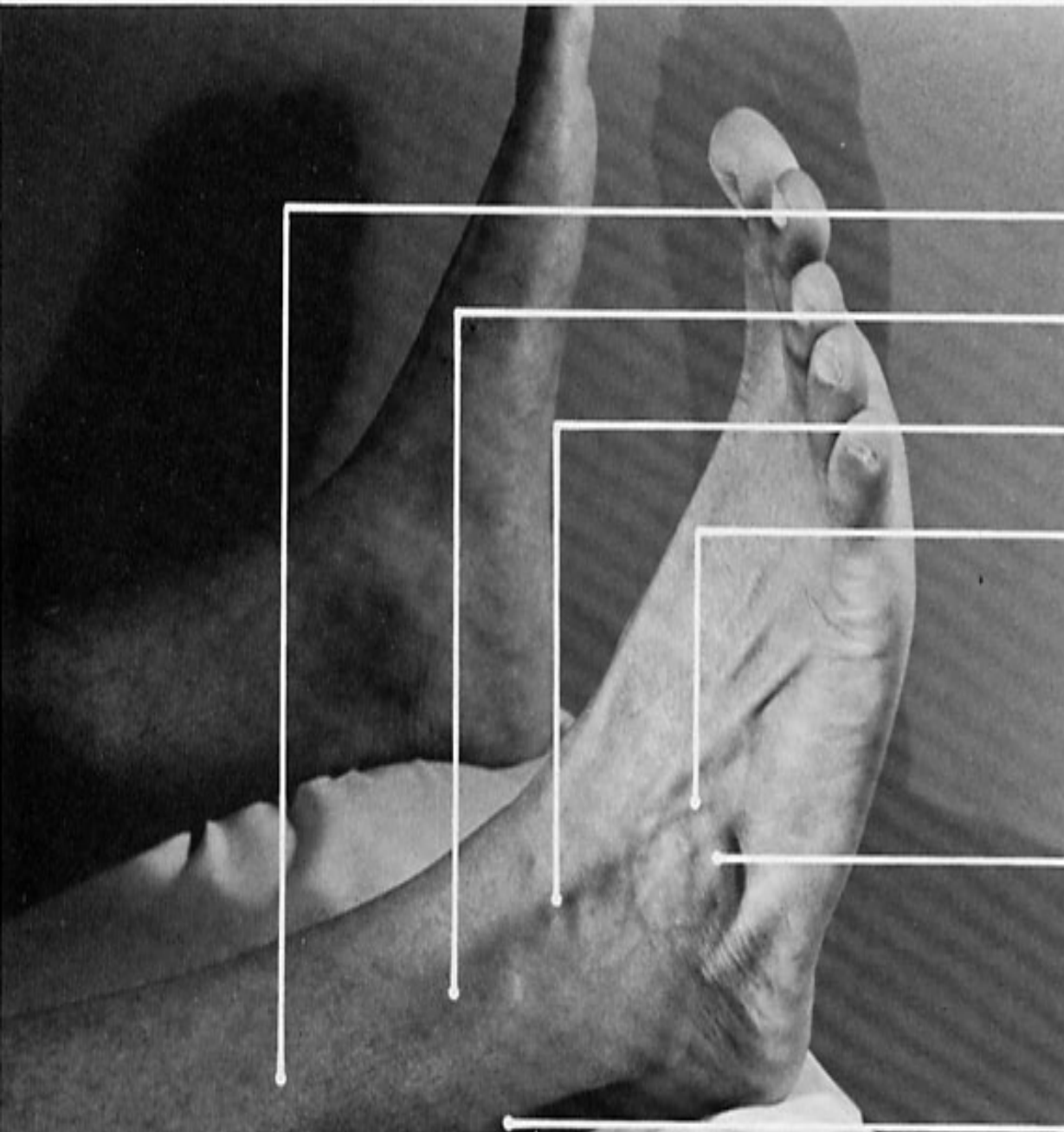
INSERTION: base of distal phalanx of great toe.

ACTION: extends great toe, foot dorsiflexion.

NERVE: deep peroneal.

ROOT: L5 and S1, especially L5





extensor digitorum longus (belly)

pin insertion site for **peroneus tertius**

extensor digitorum longus (tendons)

peroneus tertius (tendon)

extensor digitorum brevis

peroneus longus and



vastus lateralis

biceps femoris (long head)

iliotibial tract

biceps femoris (short head)

common peroneal n.

gastrocnemius (lateral head)

peroneus longus

soleus

tibialis anterior

extensor hallucis longus

peroneus brevis

extensor digitorum longus

peroneus tertius

extensor retinaculum

PERONEUS TERTIUS

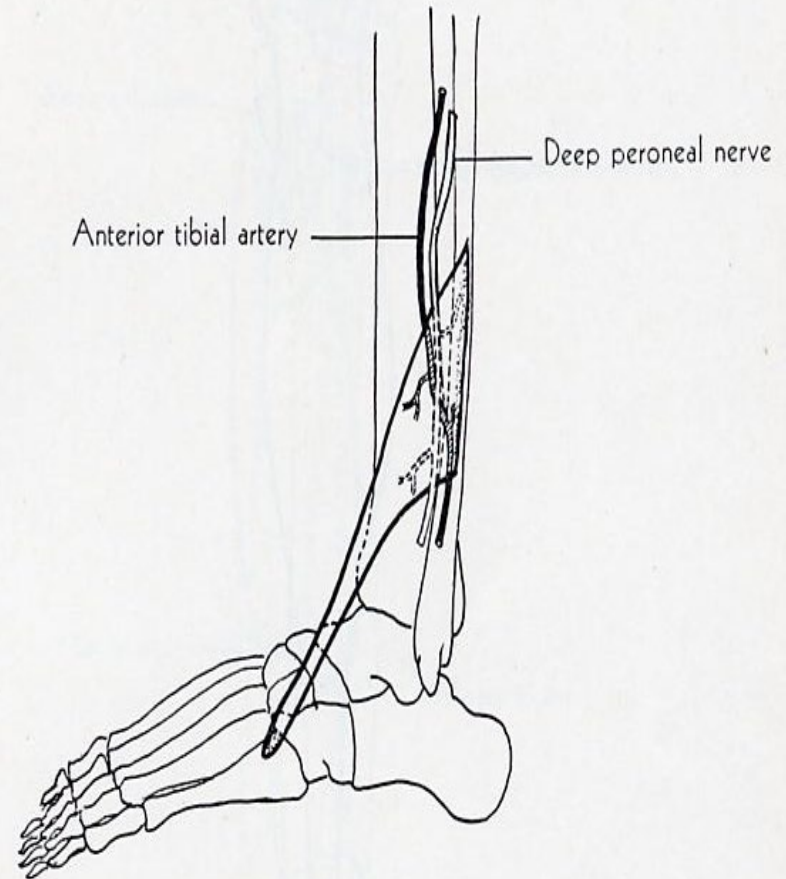
ORIGIN: commonly known as 5th tendon of EDL. Lower antero surface of fibula, intermuscular septum.

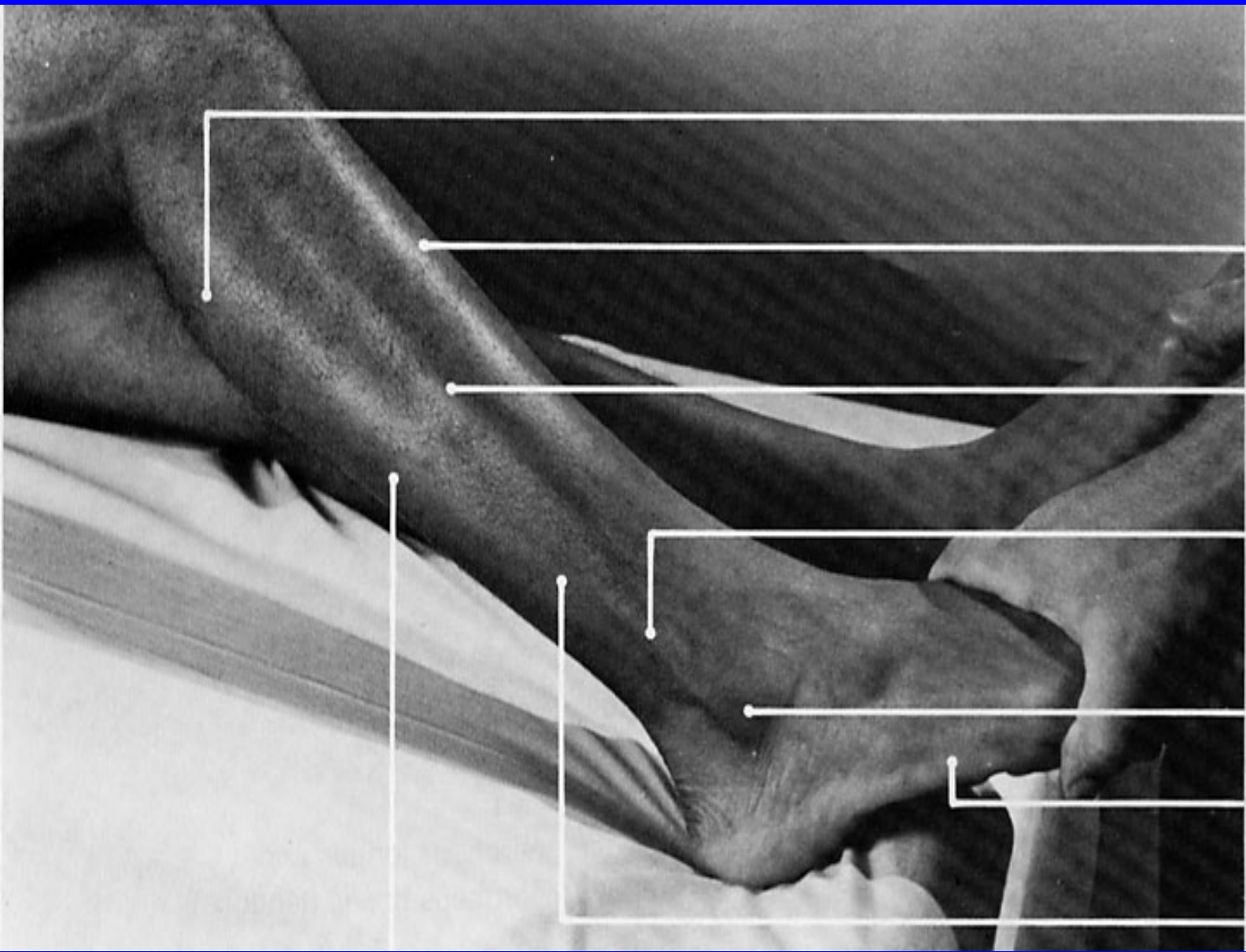
INSERTION: dorsal surface of 5th metatarsal bone.

ACTION: dorsiflexes and everts foot.

NERVE: deep peroneal.

ROOT: L5 and S1.





gastrocnemius
(lateral head)

tibialis anterior

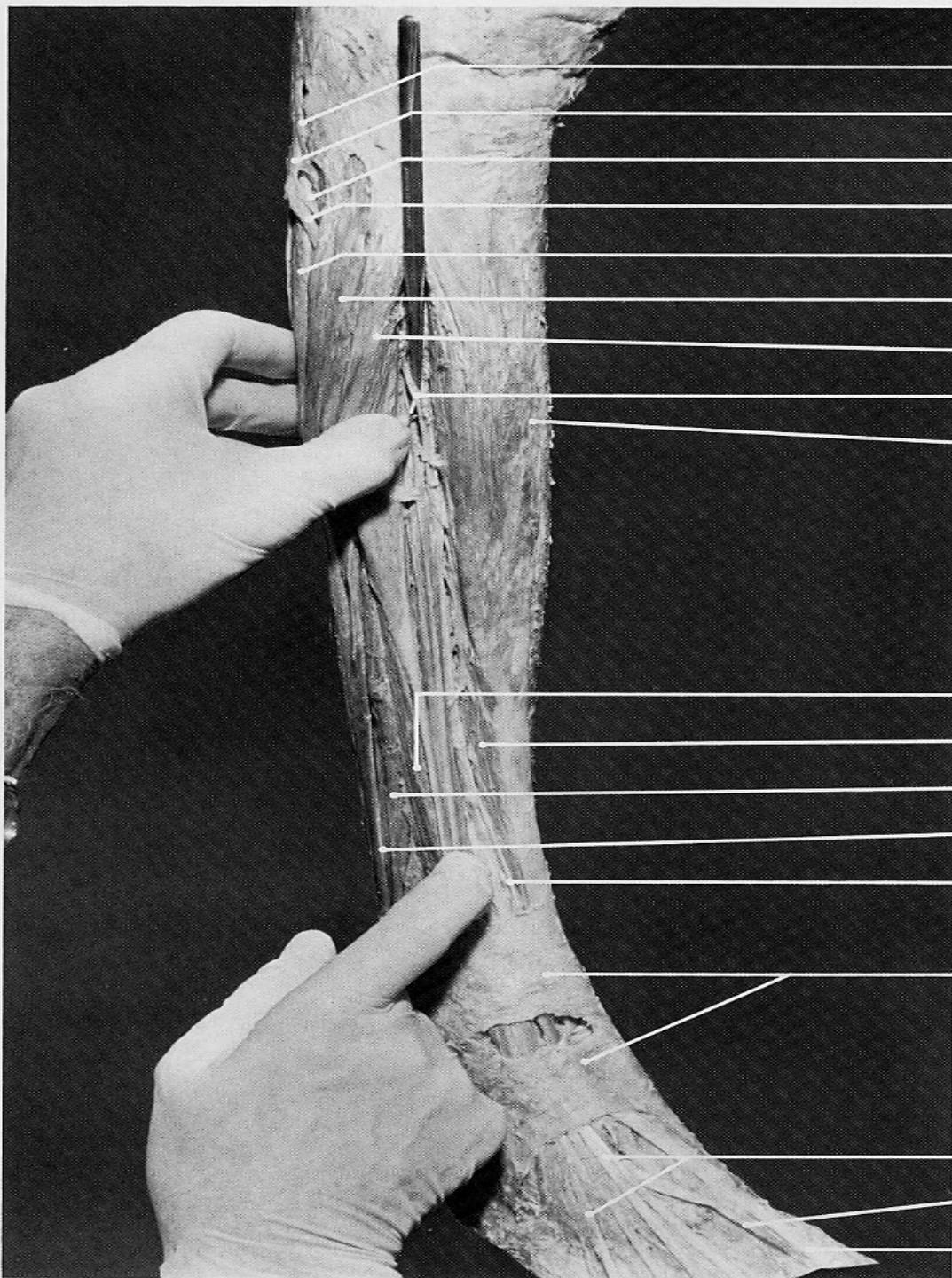
peroneus longus

**peroneus longus
(tendon) overlying
peroneus brevis
(tendon)**

lateral malleolus

abductor digiti
minimi (quinti)

peroneus brevis



biceps femoris (tendon, long head)

common peroneal n.

deep peroneal n.

superficial peroneal n.

soleus (fibular head)

peroneus longus (belly)

extensor digitorum longus (belly)

deep peroneal n.

tibialis anterior

extensor digitorum longus (belly)

tibialis anterior

peroneus brevis

peroneus longus (tendon)

deep peroneal n.

extensor retinaculum

extensor digitorum longus (tendons)

extensor hallucis brevis (tendon)

extensor hallucis longus (tendon)

PERONEUS LONGUS

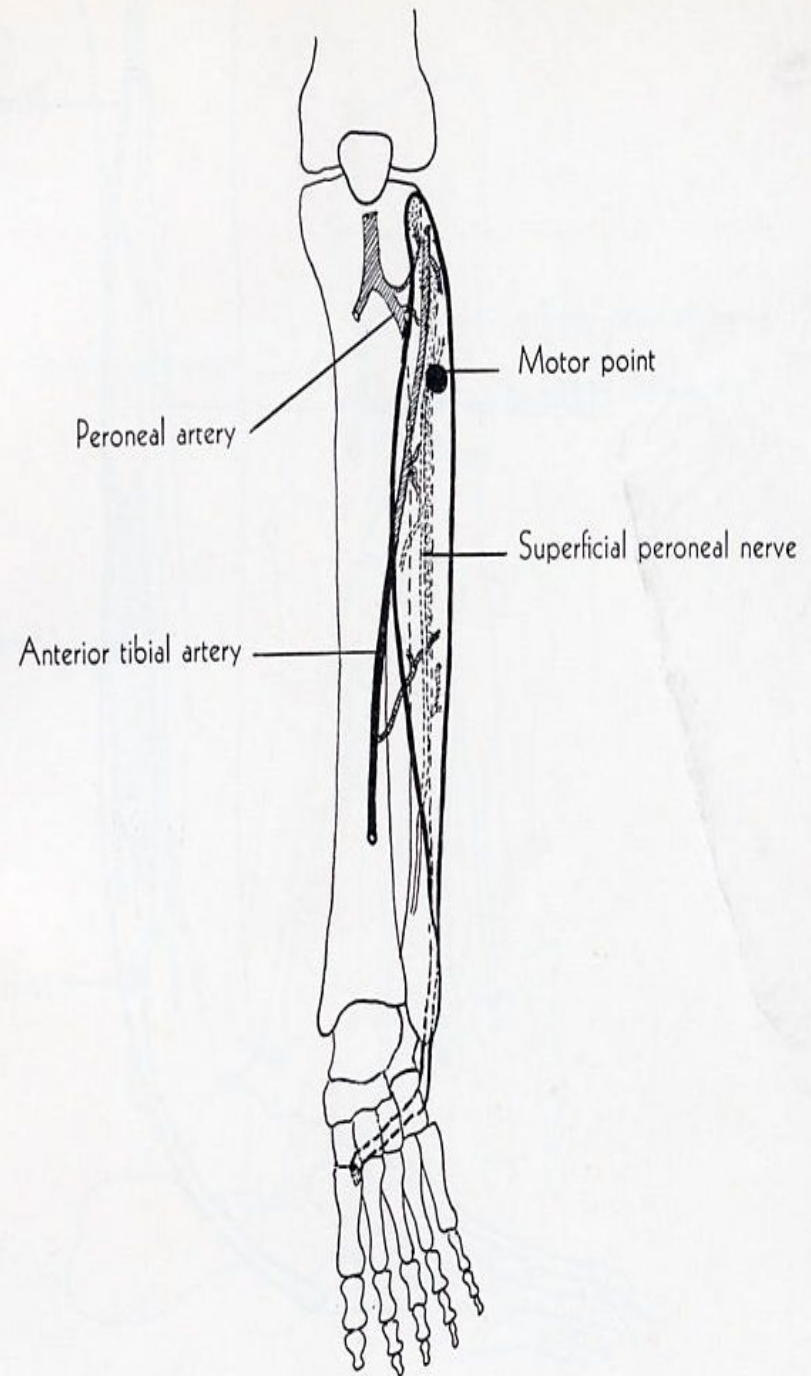
ORIGIN: lateral condyle of tibia, head and upper two-thirds of lateral surface of fibula, adjacent fascia, intermuscular septum.

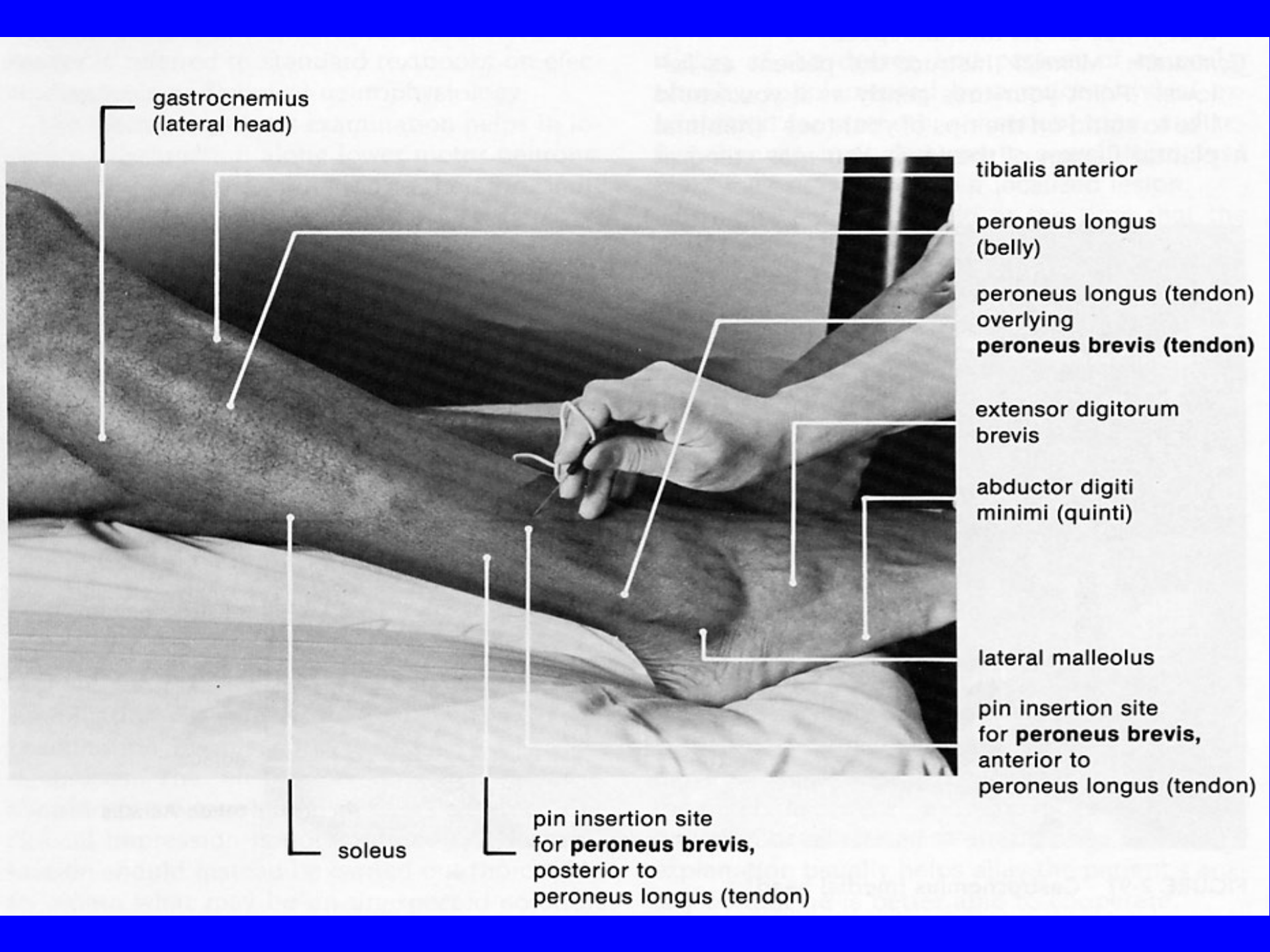
INSERTION: lateral side of medial cuneiform bone, base of 1st metatarsal bone.

ACTION: plantar flexes foot, everts it.

NERVE: superficial peroneal.

ROOT: L5 and S1, mainly S1.





gastrocnemius
(lateral head)

tibialis anterior

peroneus longus
(belly)

peroneus longus (tendon)
overlying
peroneus brevis (tendon)

extensor digitorum
brevis

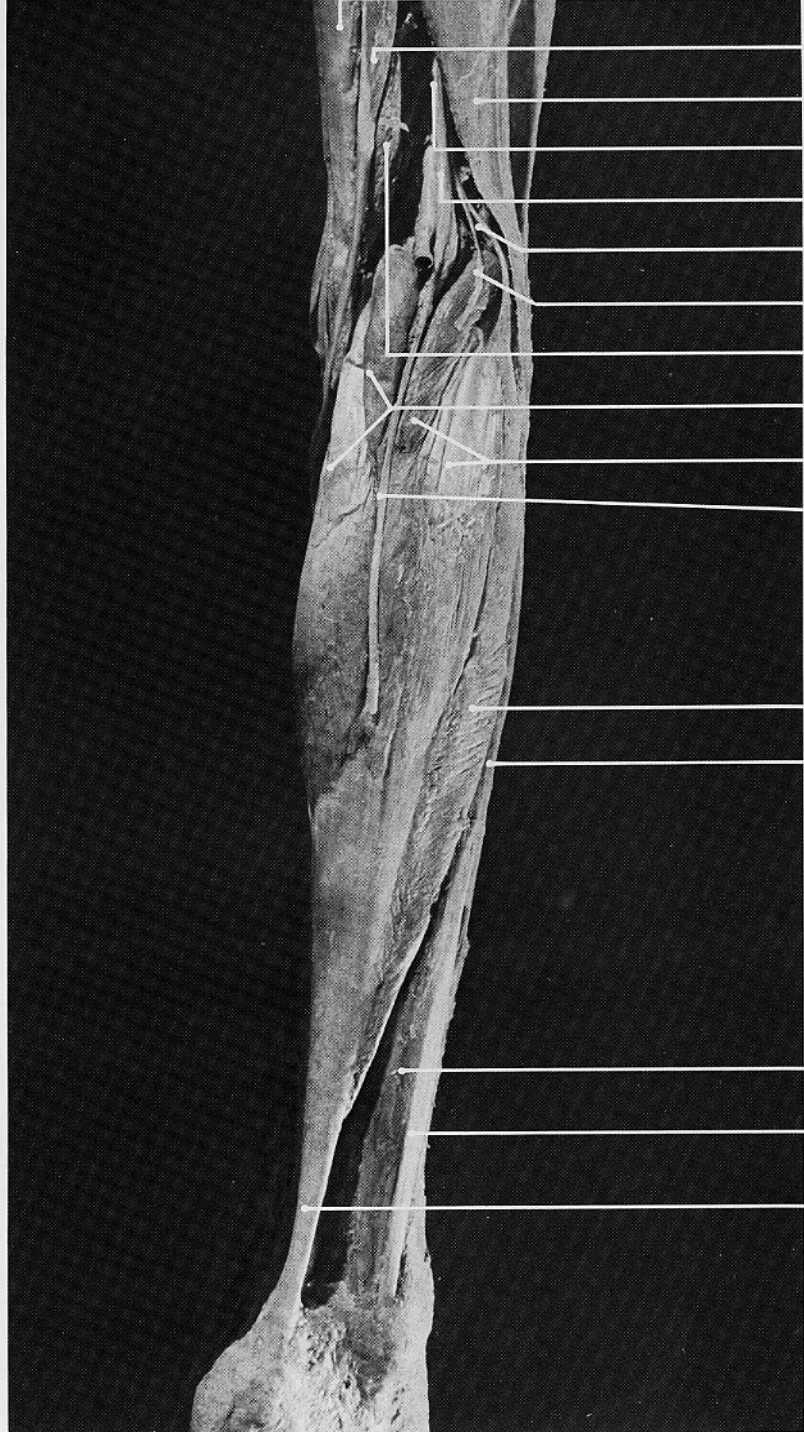
abductor digiti
minimi (quinti)

lateral malleolus

pin insertion site
for **peroneus brevis**,
anterior to
peroneus longus (tendon)

soleus

pin insertion site
for **peroneus brevis**,
posterior to
peroneus longus (tendon)



semitendinosus

biceps femoris (long head)

sciatic n.

tibial n.

common peroneal n.

lateral sural cutaneous n. (cut off)

semimembranosus

gastrocnemius (medial head)

gastrocnemius (lateral head)

medial sural cutaneous n. (cut off)

soleus (fibular origin)

peroneus longus (belly)

peroneus brevis

peroneus longus (tendon)

tendo Achillis

PERONEUS BREVIS

ORIGIN: lower two-thirds of lateral surface of fibula, adjacent intermuscular septum.

INSERTION: lateral side of base of 5th metatarsal bone.

ACTION: plantar flexes foot, everts it.

NERVE: superficial peroneal.

ROOT: L5 and S1, mainly S1.

