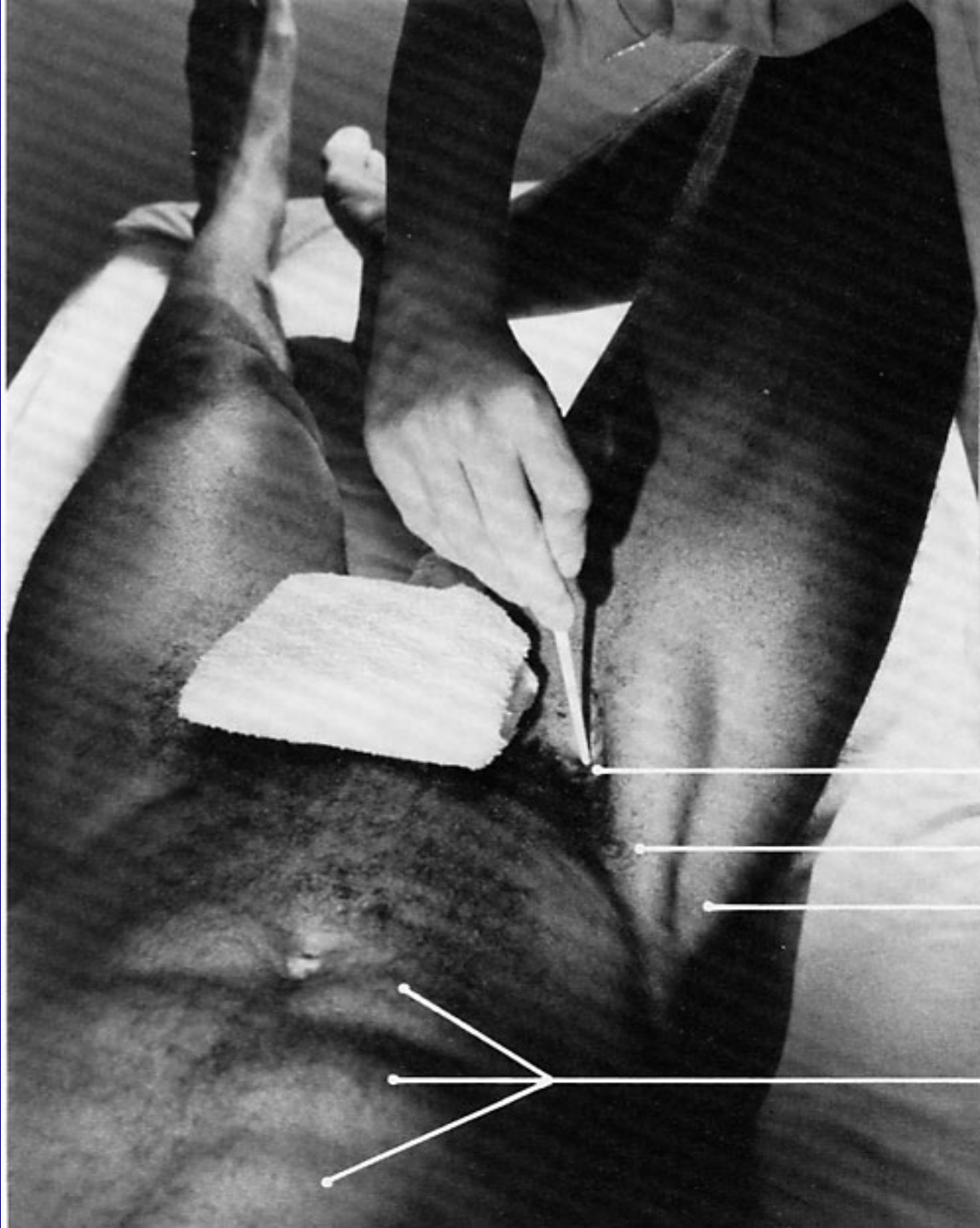


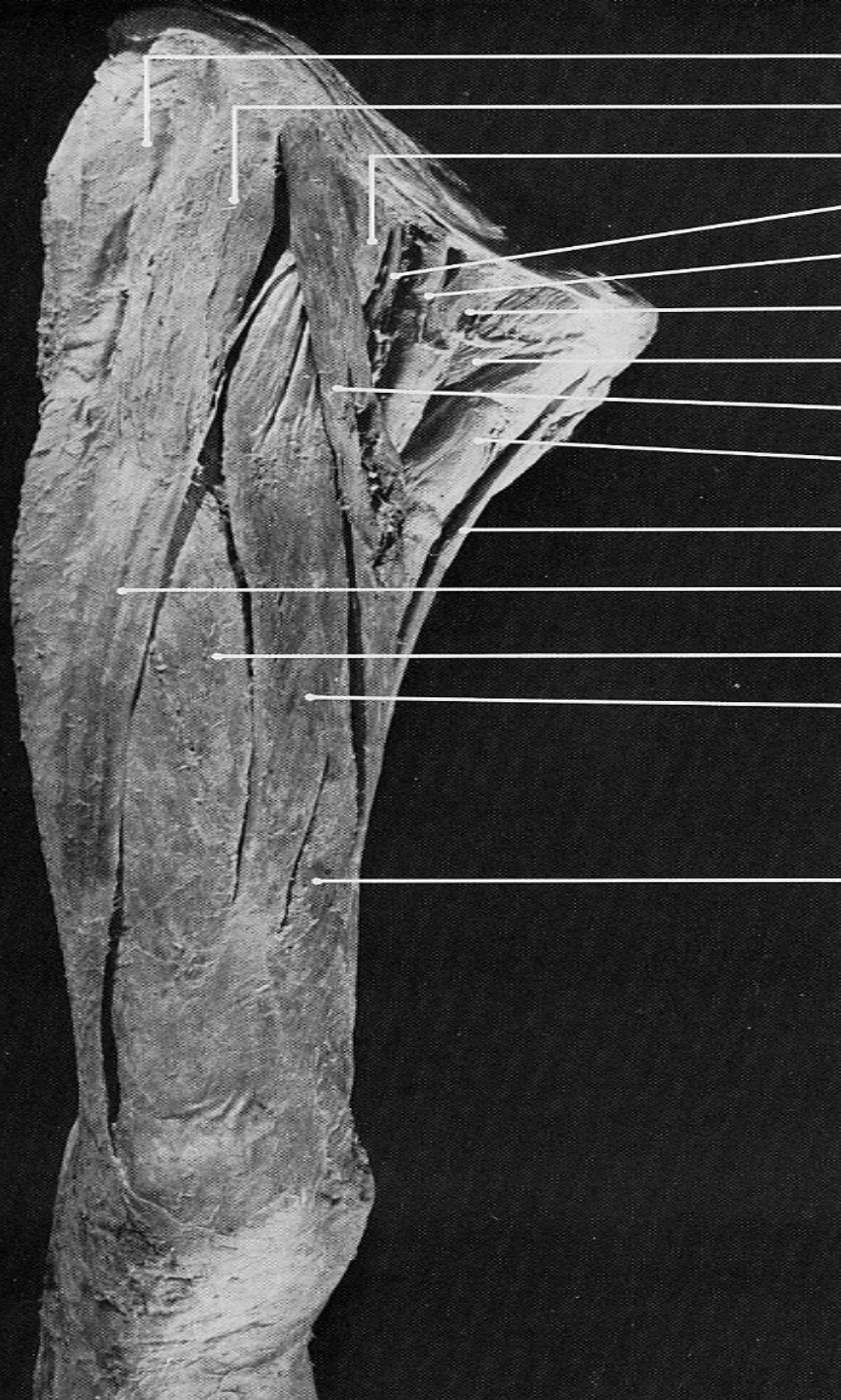
pin insertion site for iliopsoas

sartorius

tensor fasciae latae

rectus abdominis



fascia overlying gluteus medius

tensor fasciae latae

iliopsoas

femoral n.

femoral a.

femoral v.

pectineus

sartorius (damaged by embalming incision)

adductor longus

gracilis

iliotibial tract

vastus lateralis

rectus femoris

vastus medialis

PSOAS MAJOR

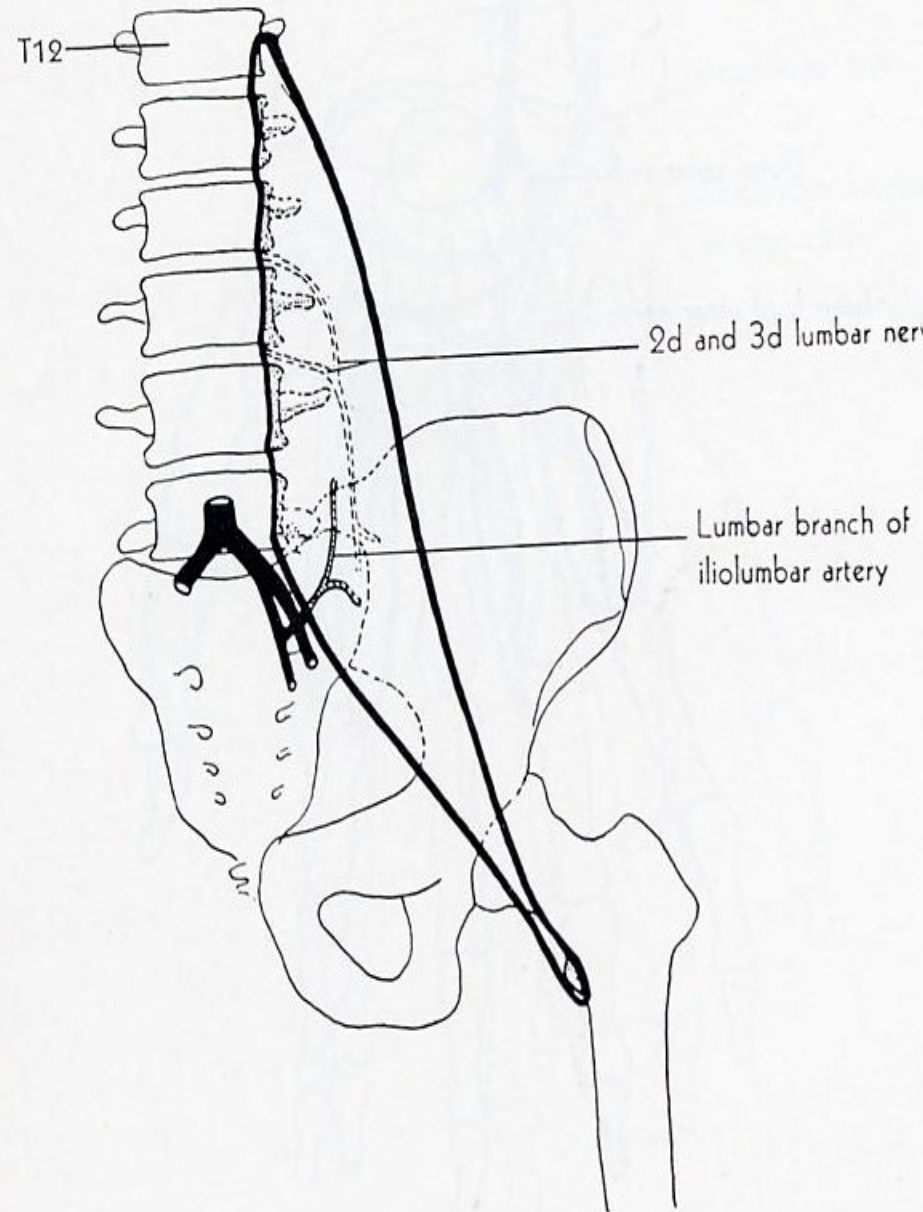
ORIGIN: anterior surface of transverse processes and bodies of lumbar vertebrae and corresponding intervertebral discs.

INSERTION: lesser trochanter of femur and with iliacus forms iliopsoas.

ACTION: flexes thigh, flexes vertebral column on pelvis when leg is fixed.

NERVE: L2 and L3 nerve.

ROOT: L2 dominant



PSOAS MAJOR

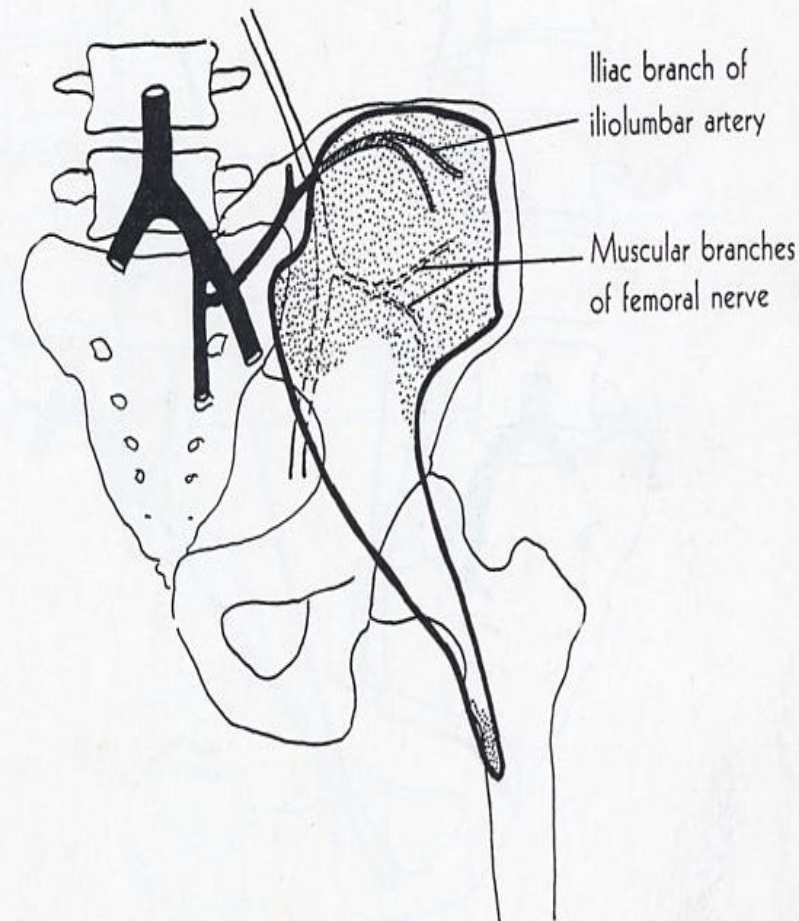
ORIGIN: upper 2/3 of iliac fossa, iliac crest, anterior sacro-iliac, LS and iliolumbar ligaments.

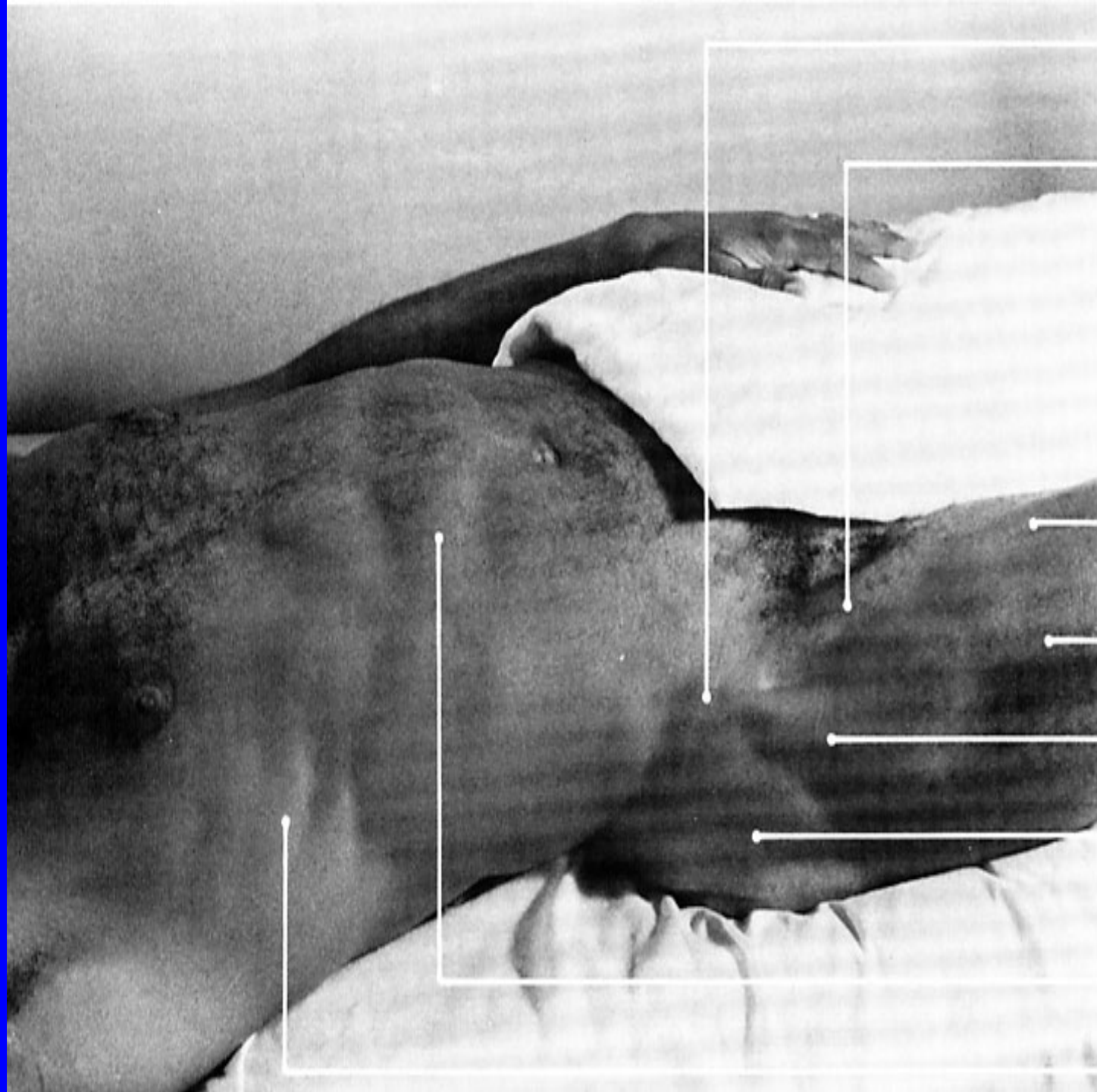
INSERTION: tendon of psoas major, lesser trochanter, capsule of hip joint, body of femur (with psoas major forms iliopsoas).

ACTION: flexes thigh, tilts pelvis forward when leg is fixed.

NERVE: femoral nerve.

ROOT: L2 dominant





anterior superior
iliac spine

sartorius

rectus femoris

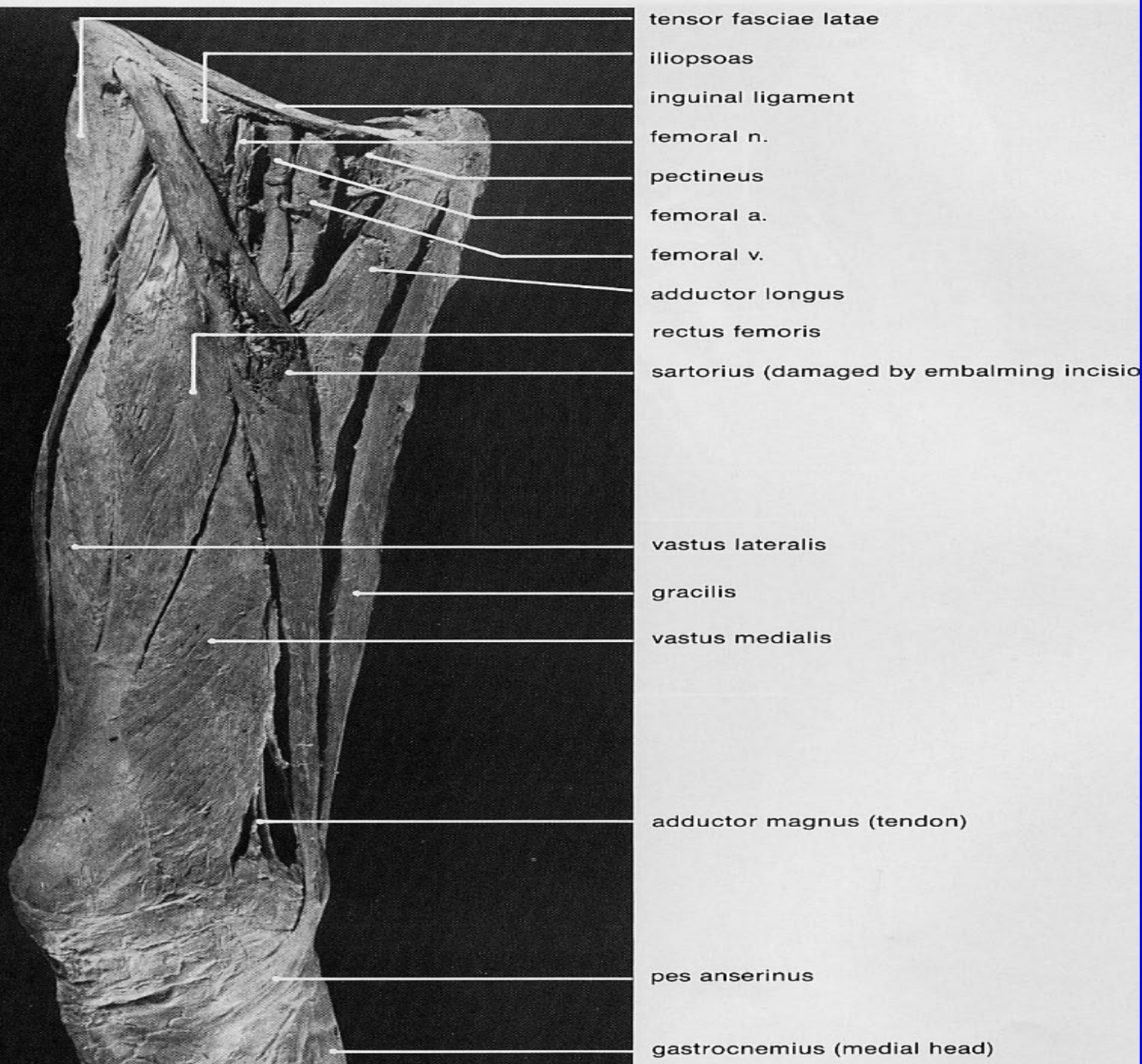
vastus lateralis

tensor fasciae latae

gluteus medius

rectus abdominis

serratus anterior



TENSOR FASCIA LATAE

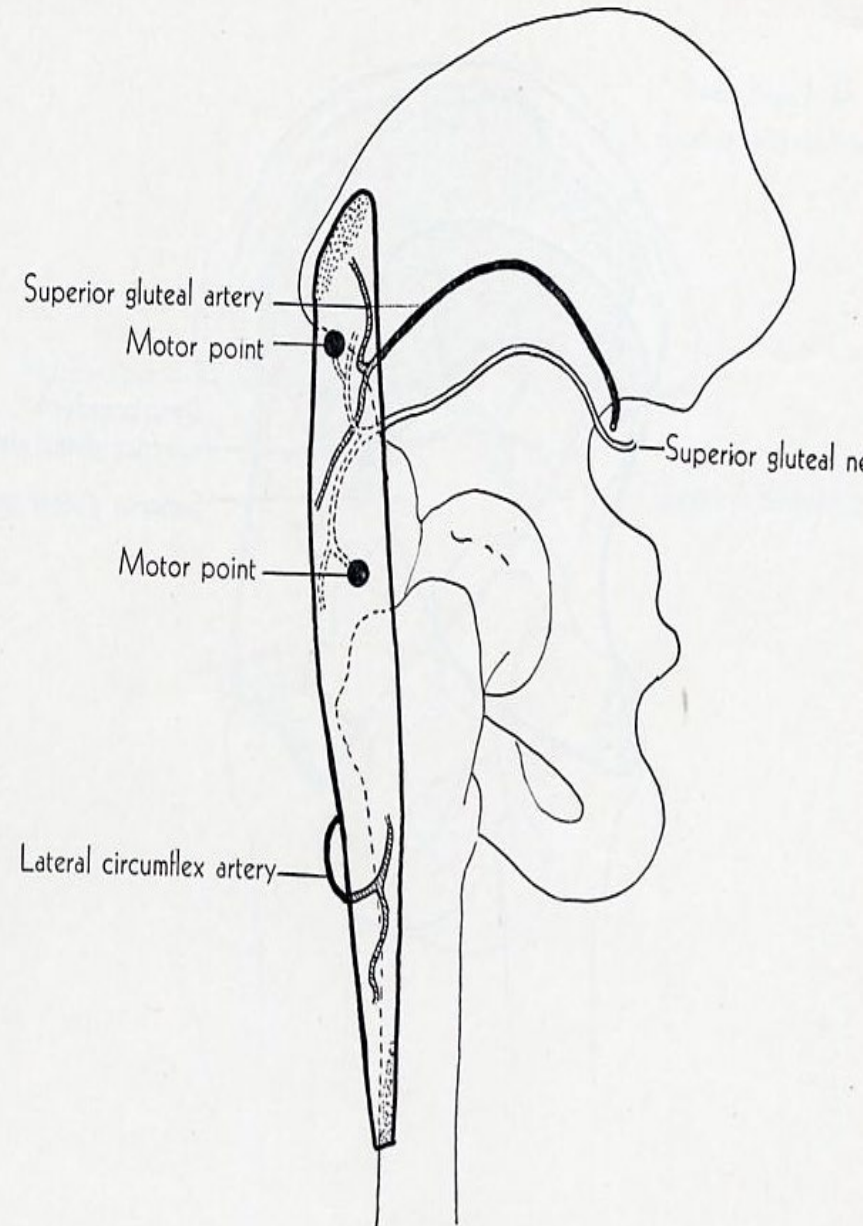
ORIGIN: anterior part of the outer lip of iliac crest, anterior border of ilium.

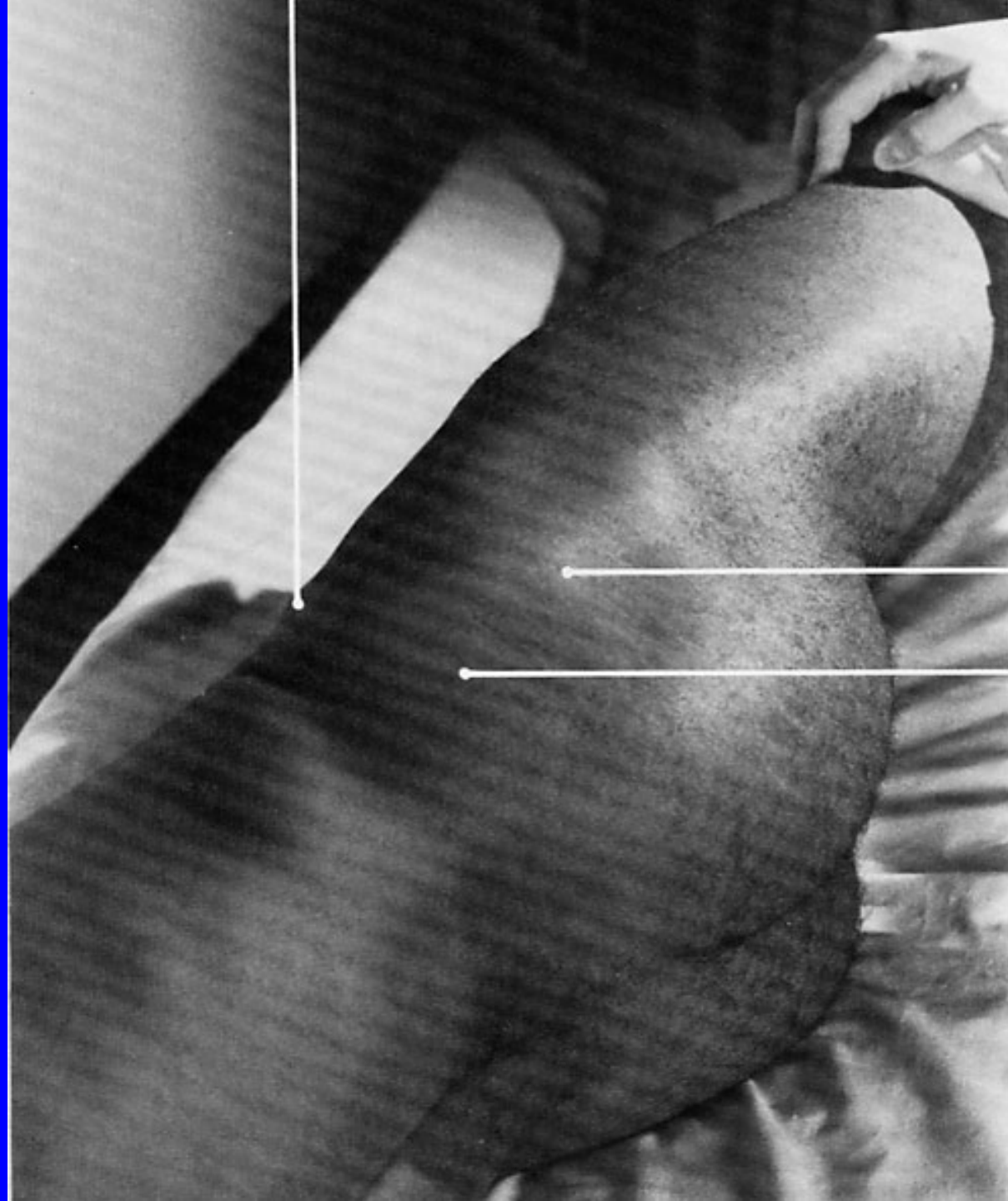
INSERTION: middle third of thigh along the iliotibial tract.

ACTION: tenses fascia lata, assist in flexion, abduction and internal rotation of the thigh.

NERVE: superior gluteal

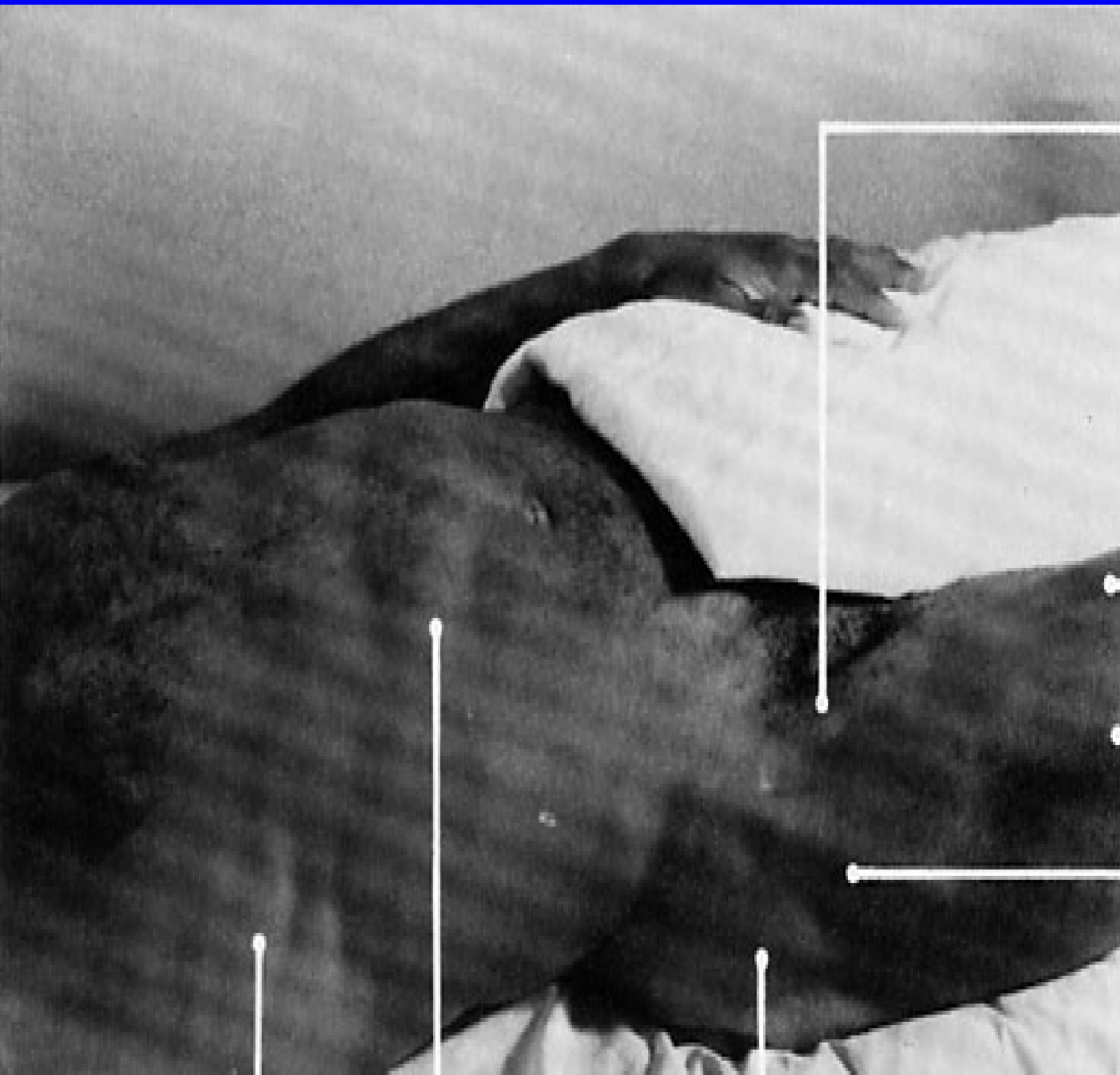
ROOT: L4,L5 mainly L5 but L4 may predominate.





greater trochanter

gluteus medius

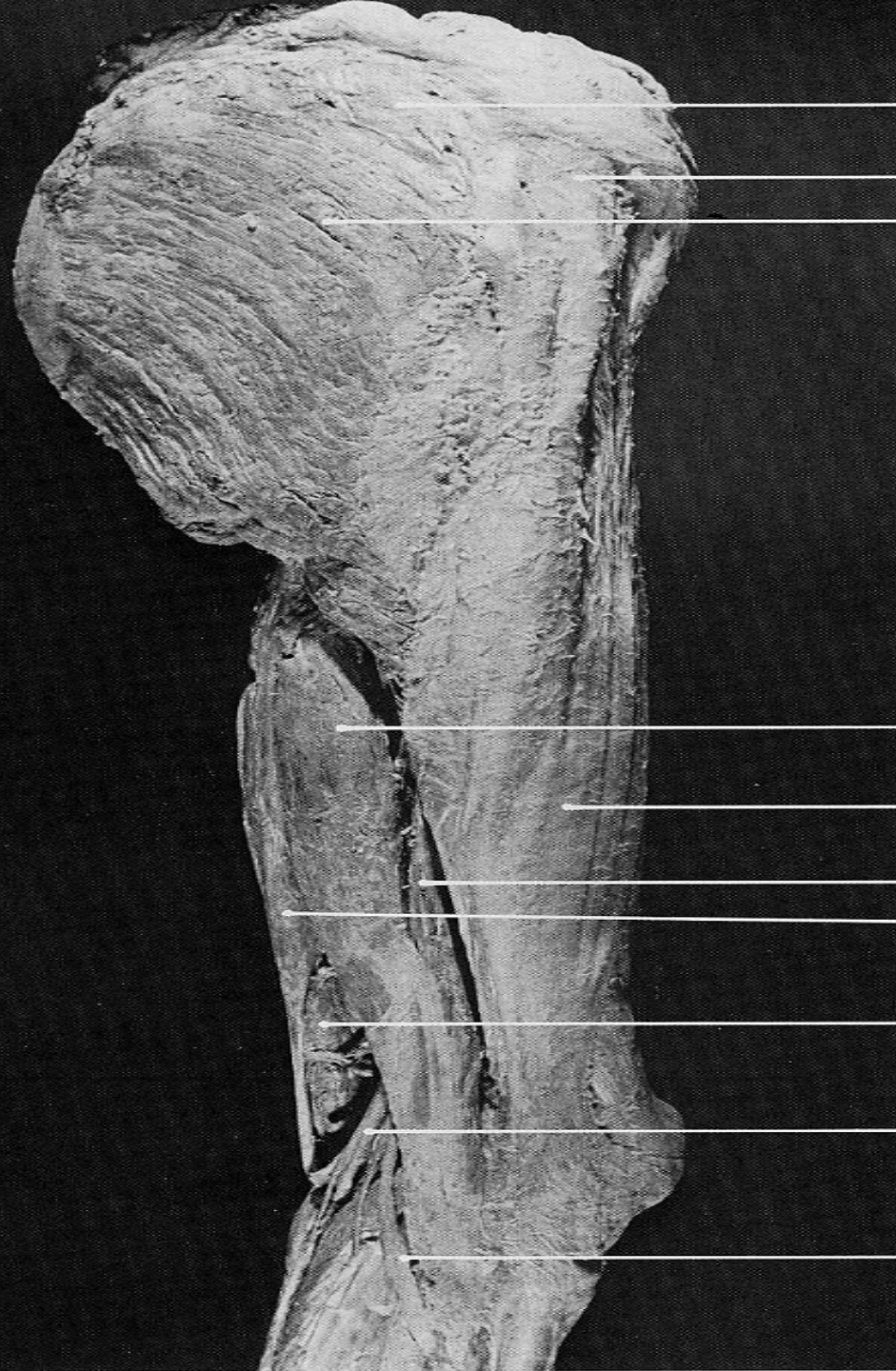


sartorius

rectus femoris

vastus lateralis

tensor fasciae latae



gluteus medius

tensor fasciae latae

gluteus maximus

biceps femoris (long head)

iliotibial tract

biceps femoris (short head)

semitendinosus

semimembranosus

tibial n.

common peroneal n.

GLUTEUS MEDIUS

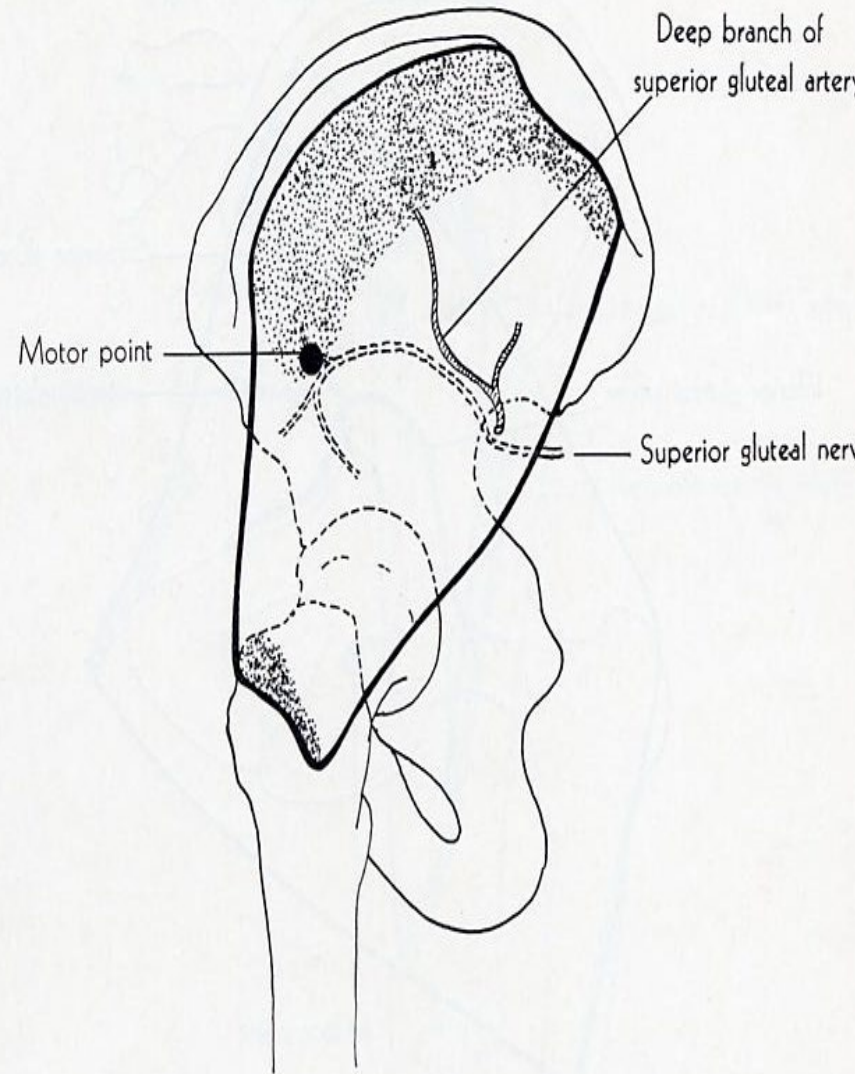
ORIGIN: outer surface of ilium from iliac crest and posterior gluteal line above, to anterior gluteal line below, and the gluteal aponeurosis.

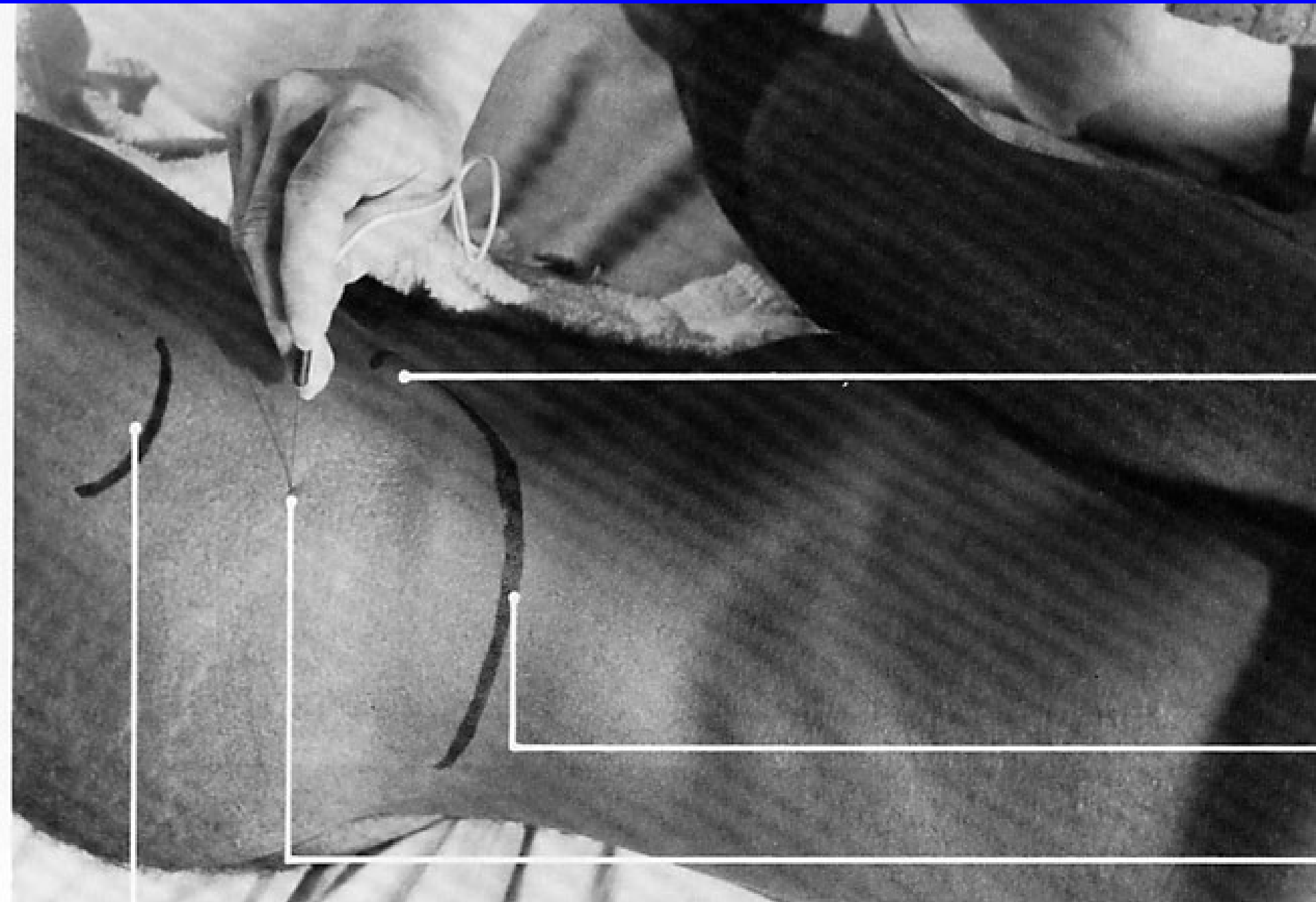INSERTION: lateral surface of greater trochanter.

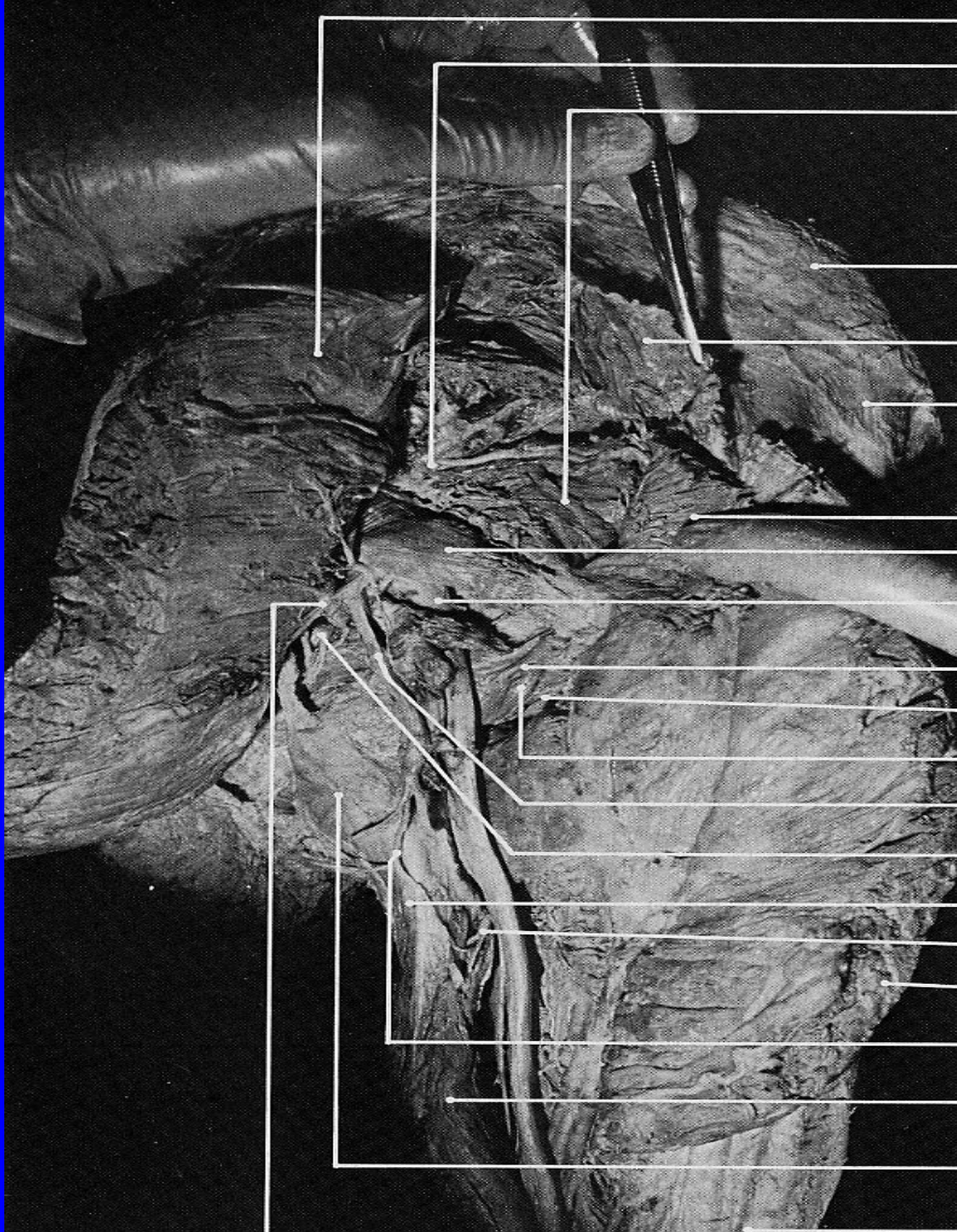
ACTION: abduction of thigh, internal rotation of thigh when the limb is extended.

NERVE: superior gluteal.

ROOT: L4, L5 and S1 mainly L5.







deep surface of gluteus maximus

superior gluteal a., v., and n.

gluteus minimus

iliac crest

deep surface of gluteus medius
(segment turned upward)

fascia over tensor fasciae latae

deep surface of gluteus medius
(segment turned downward)

piriformis

sciatic n.

superior gemellus

inferior gemellus

obturator internus (tendon)

posterior femoral cutaneous n.

pubendal n. and internal pudendal a.

common tendon of hamstrings

muscular branches from sciatic n.
to hamstrings

cut edge of gluteus maximus

perineal branch of posterior
femoral cutaneous n.

biceps femoris (long head)

ischial tuberosity

lateral intermuscular septum

GLUTEUS MINIMUS

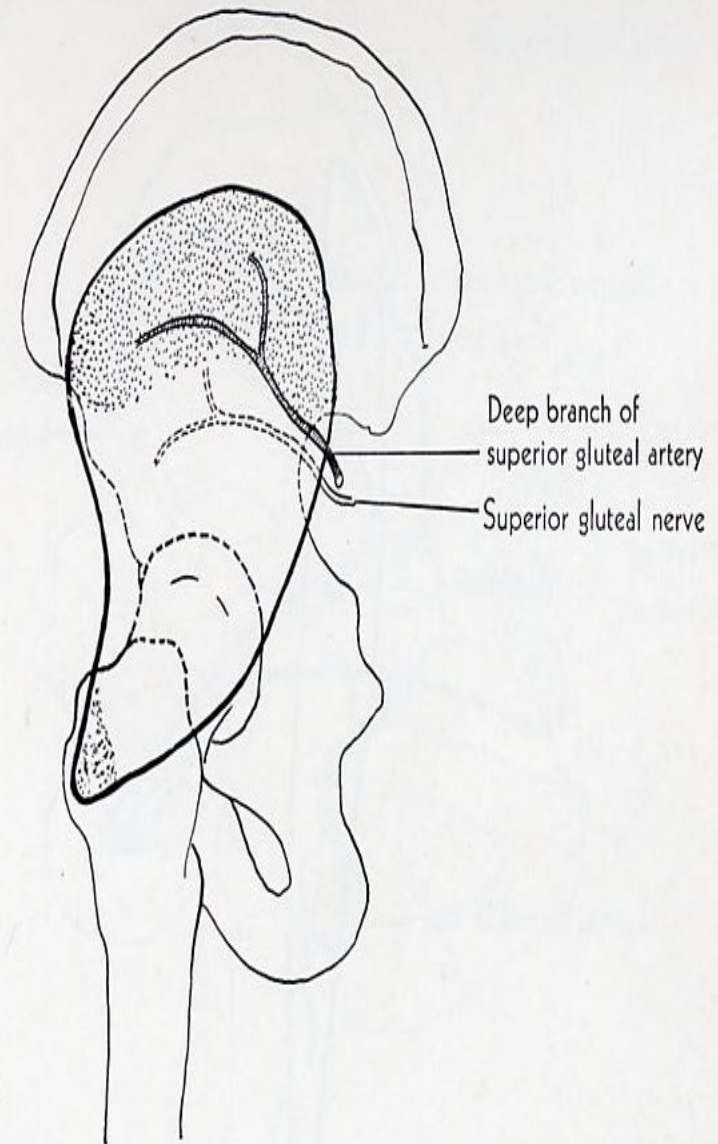
ORIGIN: outer surface of ilium from iliac crest between the anterior and inferior gluteal lines, margin of greater sciatic notch.

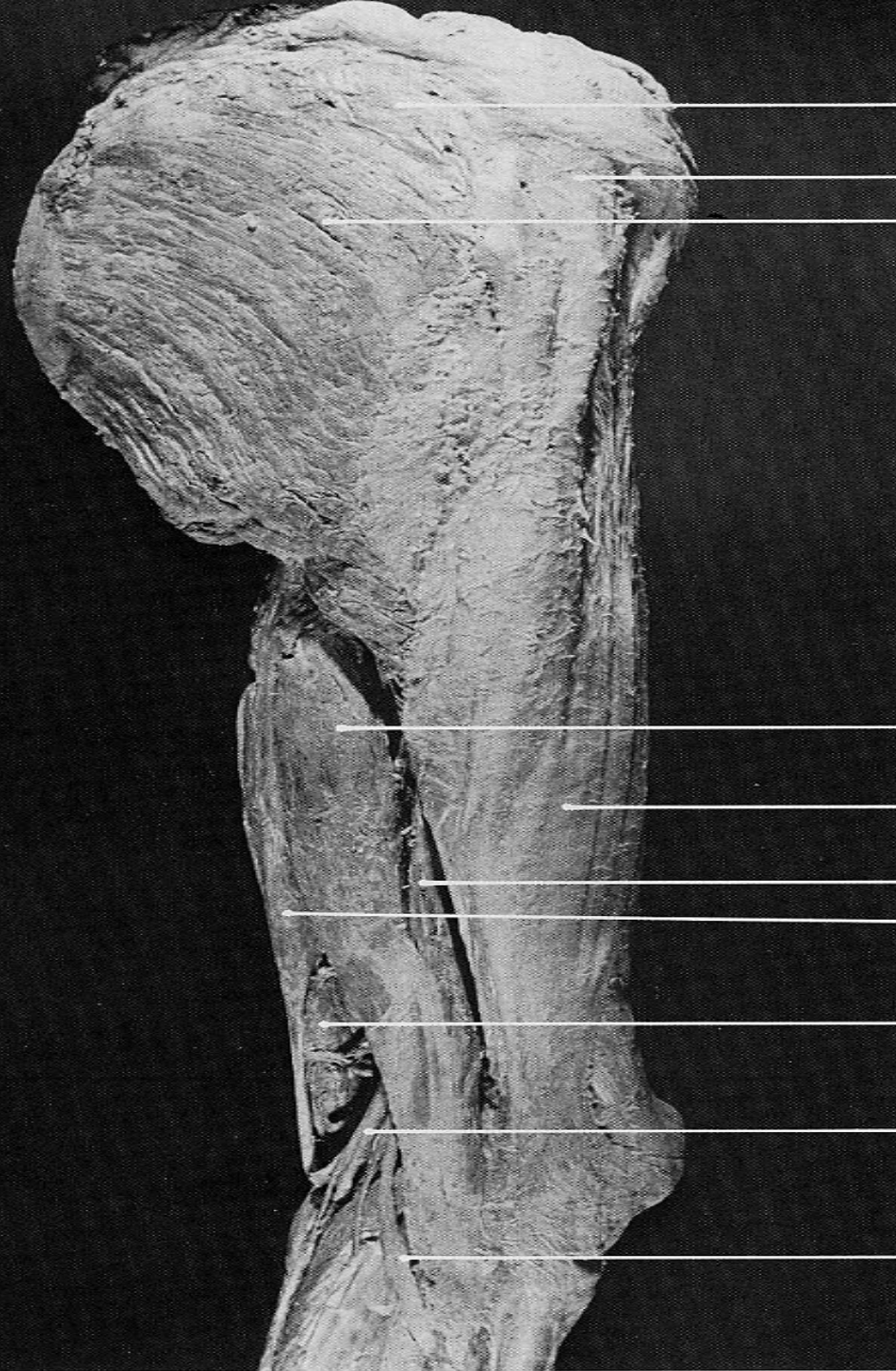
INSERTION: anterior border of greater trochanter.

ACTION: abducts thigh, rotates thigh when the limb is extended.

NERVE: superior gluteal.

ROOT: L4, L5 and S1 mainly L5.





gluteus medius

tensor fasciae latae

gluteus maximus

biceps femoris (long head)

iliotibial tract

biceps femoris (short head)

semitendinosus

semimembranosus

tibial n.

common peroneal n.

GLUTEUS MAXIMUS

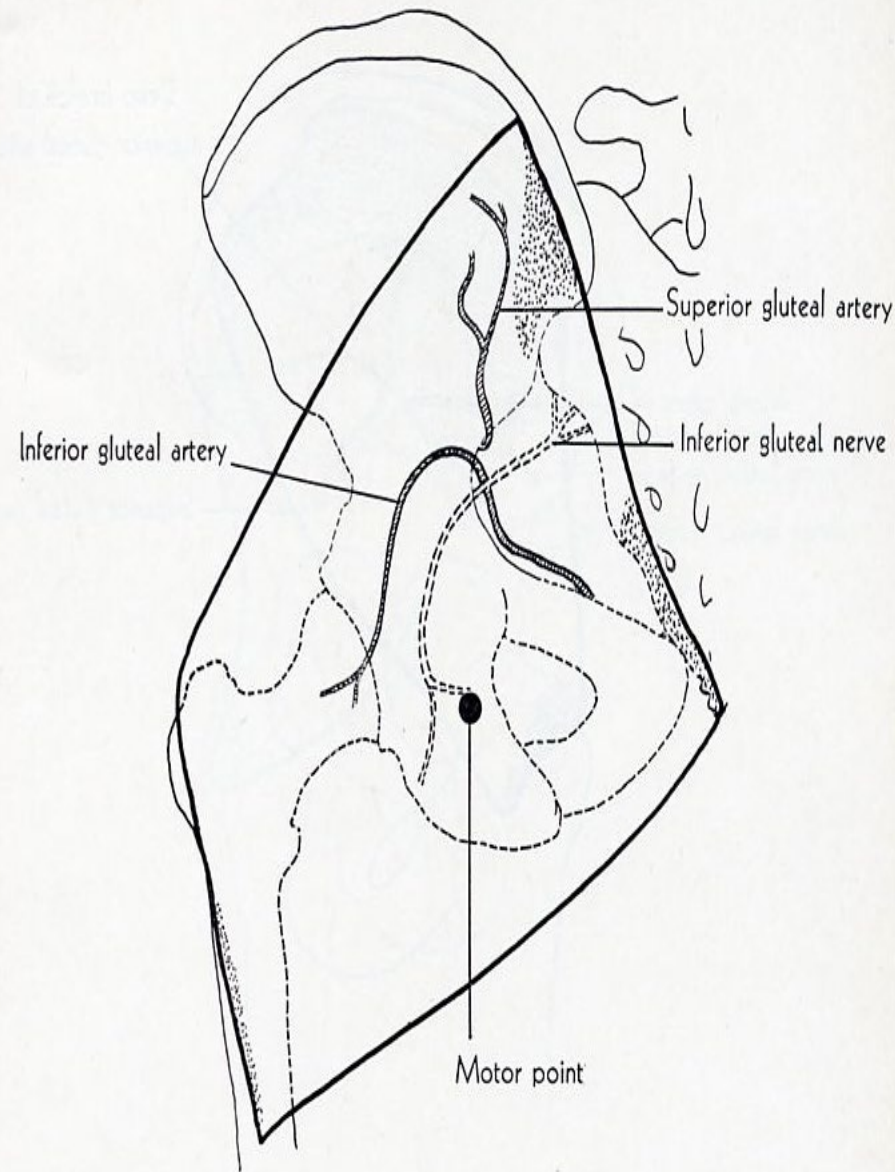
ORIGIN: posterior gluteal line, tendon of sacrospinalis, dorsal surface of sacrum and coccyx, sacro tuberos ligament.

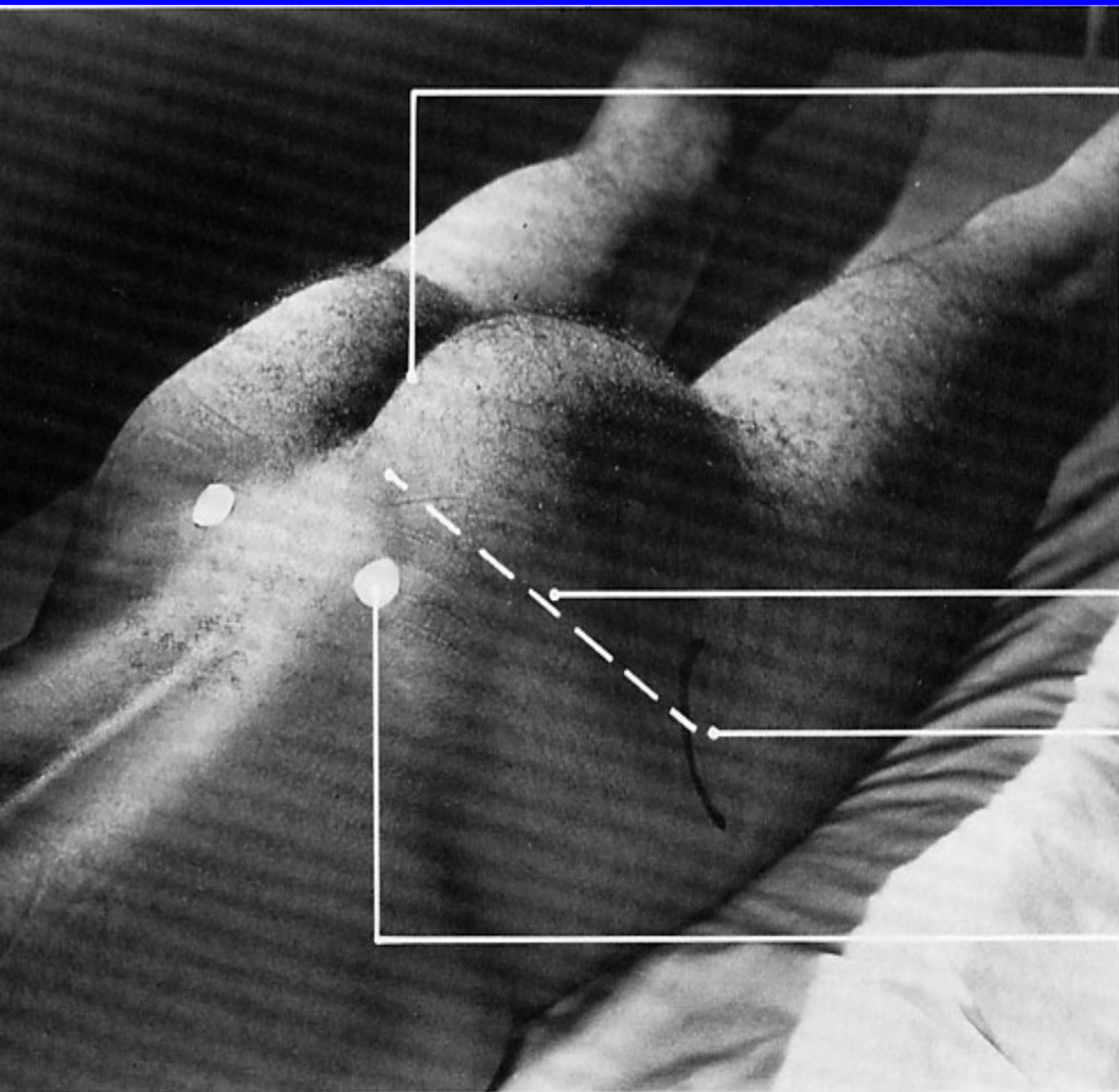
INSERTION: gluteal tuberosity of femur, iliotibial tract.

ACTION: extends the thigh, assist in adduction and external rotation. Acting from the insertion, this muscle extends the trunk.

NERVE: inferior gluteal.

ROOT: L5, S1, S2 mainly S1.



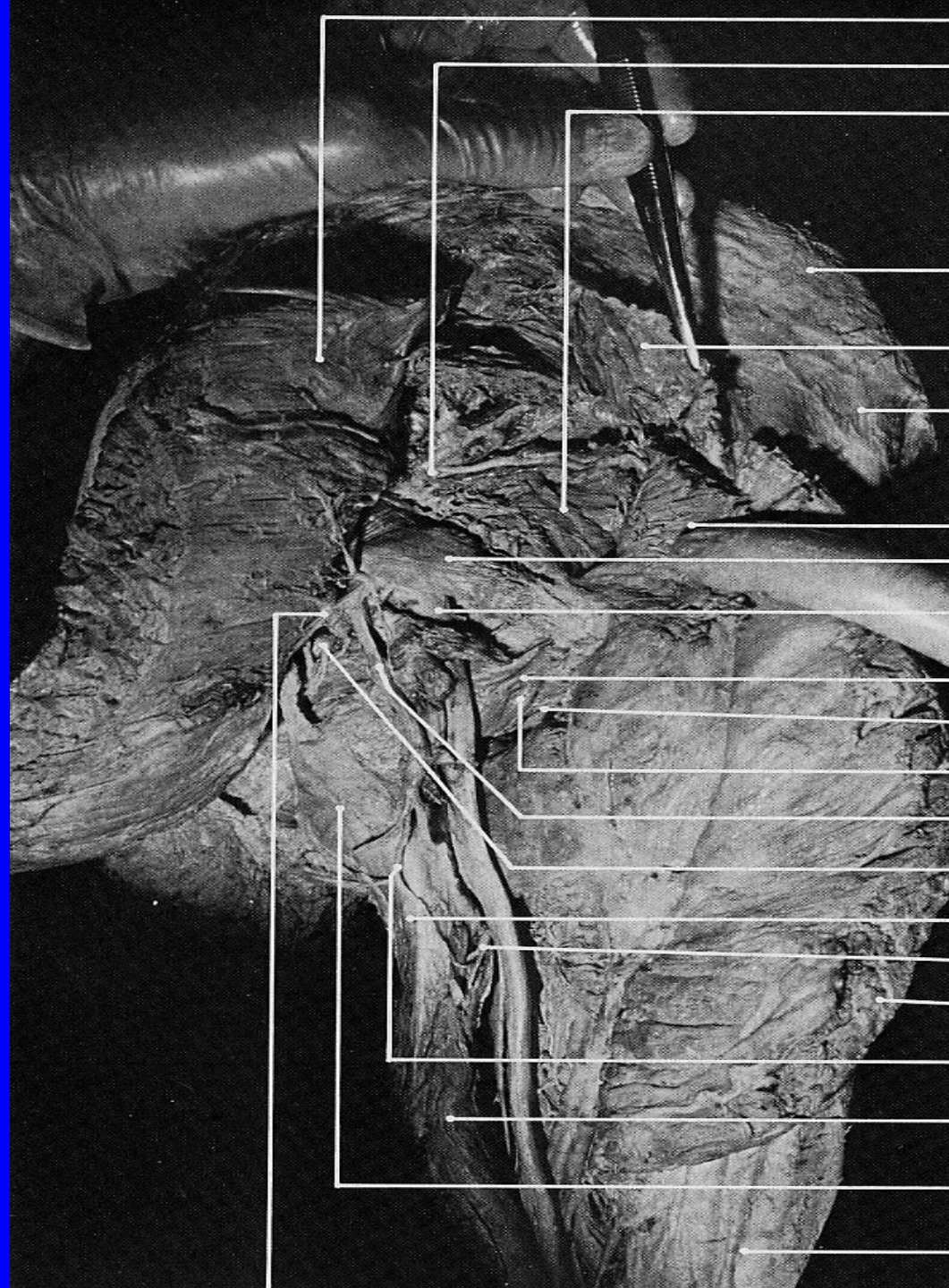


level of inferior tip of coccyx

lower border of **piriformis**

greater trochanter

posterior superior iliac spine



deep surface of gluteus maximus

superior gluteal a., v., and n.

gluteus minimus

iliac crest

deep surface of gluteus medius
(segment turned upward)

fascia over tensor fasciae latae

deep surface of gluteus medius
(segment turned downward)

piriformis

sciatic n.

superior gemellus

inferior gemellus

obturator internus (tendon)

posterior femoral cutaneous n.

pudendal n. and internal pudendal a.

common tendon of hamstrings

muscular branches from sciatic n.
to hamstrings

cut edge of gluteus maximus

perineal branch of posterior
femoral cutaneous n.

biceps femoris (long head)

ischial tuberosity

lateral intermuscular septum

PIRIFORMIS

ORIGIN: pelvic surface of sacrum between anterior sacral foramina, margin of greater sciatic foramen, sacrotuberous ligament.

INSERTION: upper border of greater trochanter of femur.

ACTION: external rotation of the hip, abducts thigh when hip is flexed.

NERVE: ventral rami of L5, S1 and S2.

ROOT: L5, S1, S2 mainly S1.

