



Human Anatomy in Motion: Anterolateral Leg Muscles

Jennifer Chu, M.D.

**Electrodiagnosis: An Anatomical and Clinical Approach
Lippincott, Phila, 1986**


Copyright © Jennifer Chu, M.D.

Chu-Andrews
Johnson

Electrodiagnosis
An Anatomical and Clinical Approach

Electrodiagnosis

An Anatomical and Clinical Approach



Jennifer Chu-Andrews • Robert J. Johnson



Elsevier



Sponsoring Editor: Sanford J. Robinson
Manuscript Editor: Lee Henderson
Indexer: Ann Cassar
Design Director: Tracy Baldwin
Designer: Arlene Putterman
Production Supervisor: J. Corey Gray
Production Assistant: Kathleen R. Diamond
Compositor: Ruttle, Shaw & Wetherill, Inc.
Printer/Binder: Halliday Lithograph

Copyright © 1986, by Jennifer Chu-Andrews.
All rights reserved. No part of this book may be
used or reproduced in any manner whatsoever
without written permission except for brief
quotations embodied in critical articles and
reviews. Printed in the United States of
America. For information write J. B. Lippincott
Company, East Washington Square,
Philadelphia, Pennsylvania 19105.

6 5 4 3 2 1

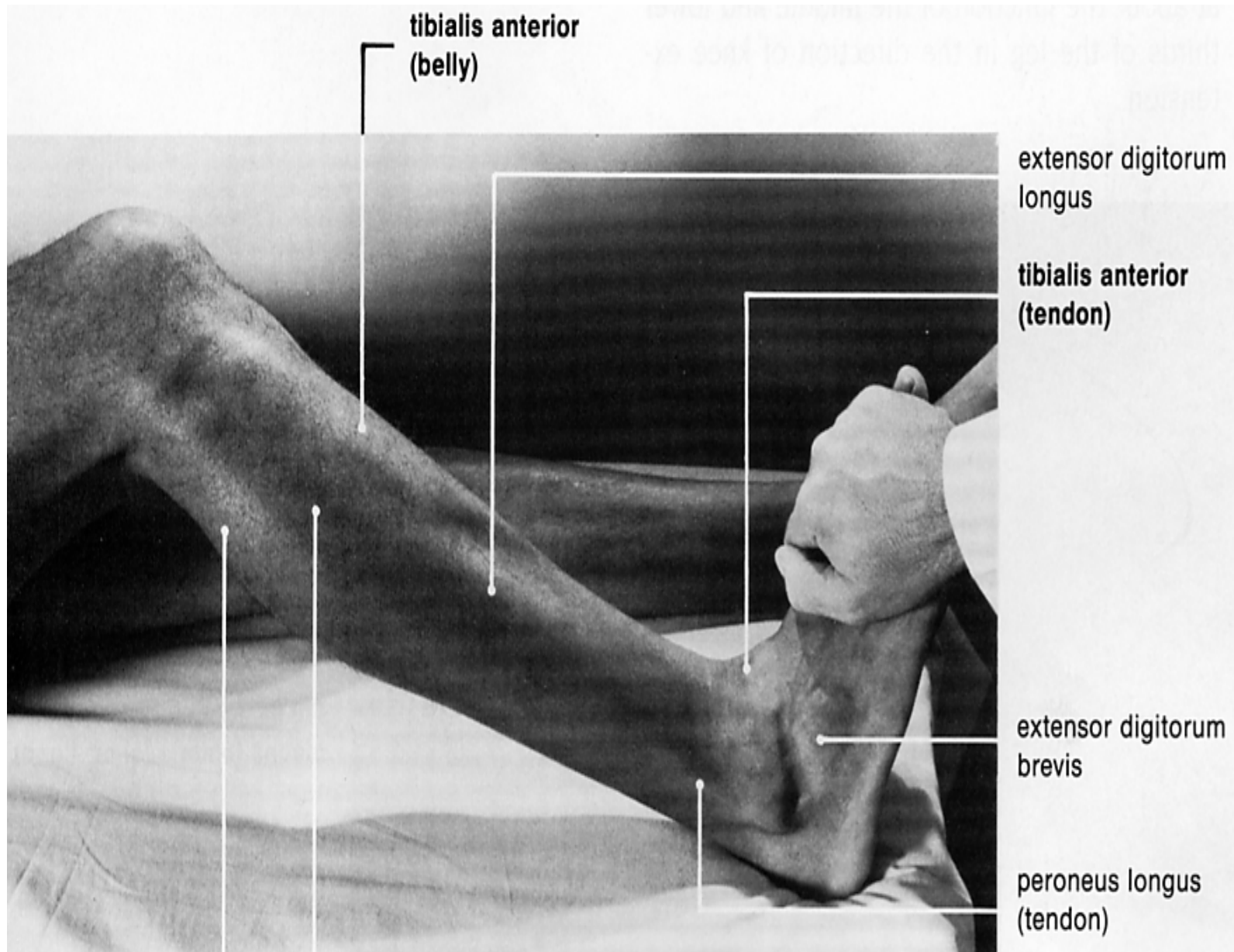
**Library of Congress Cataloging-in-
Publication Data**

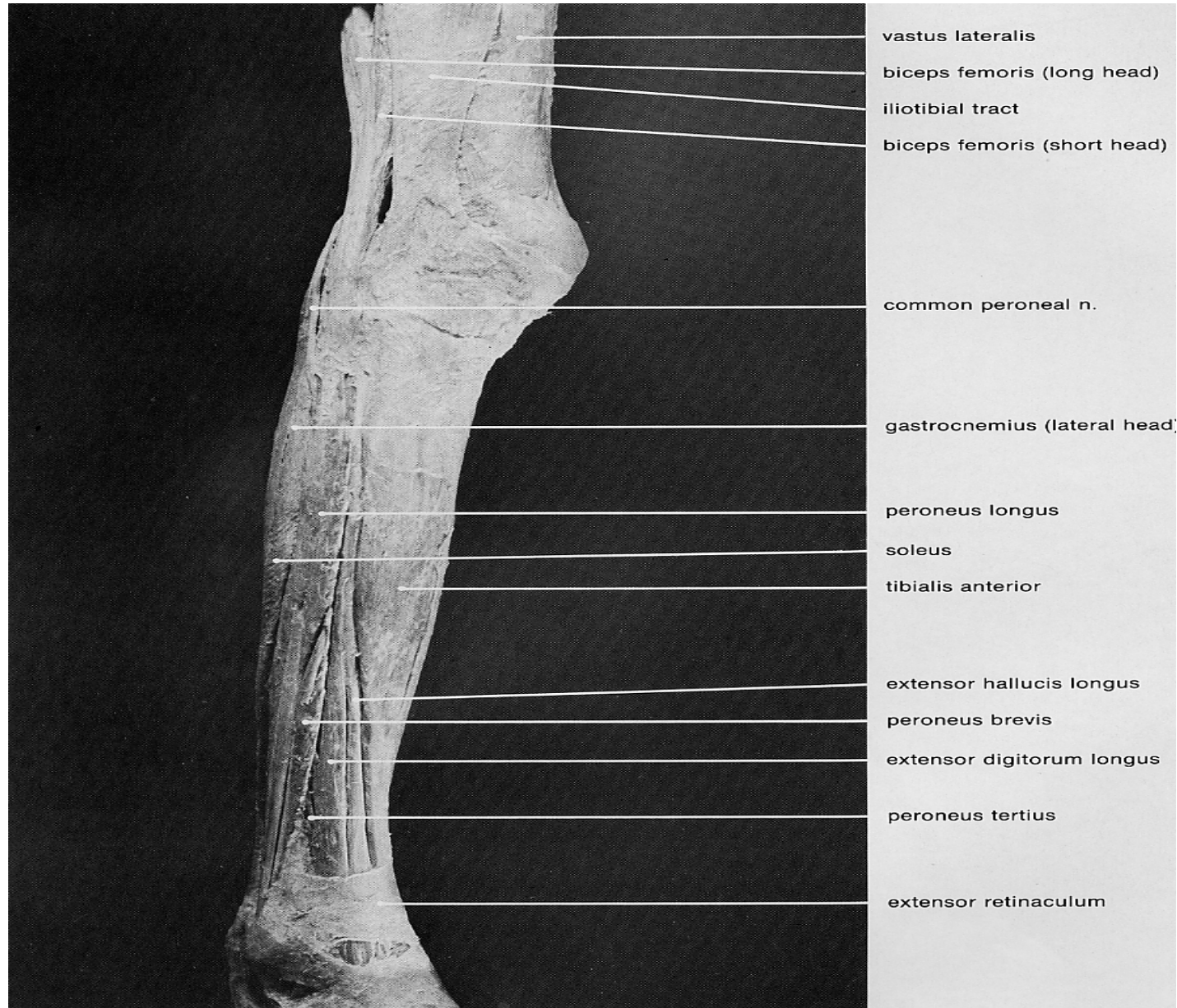
Chu-Andrews, Jennifer.
Electrodiagnosis: an anatomical and clinical
approach.

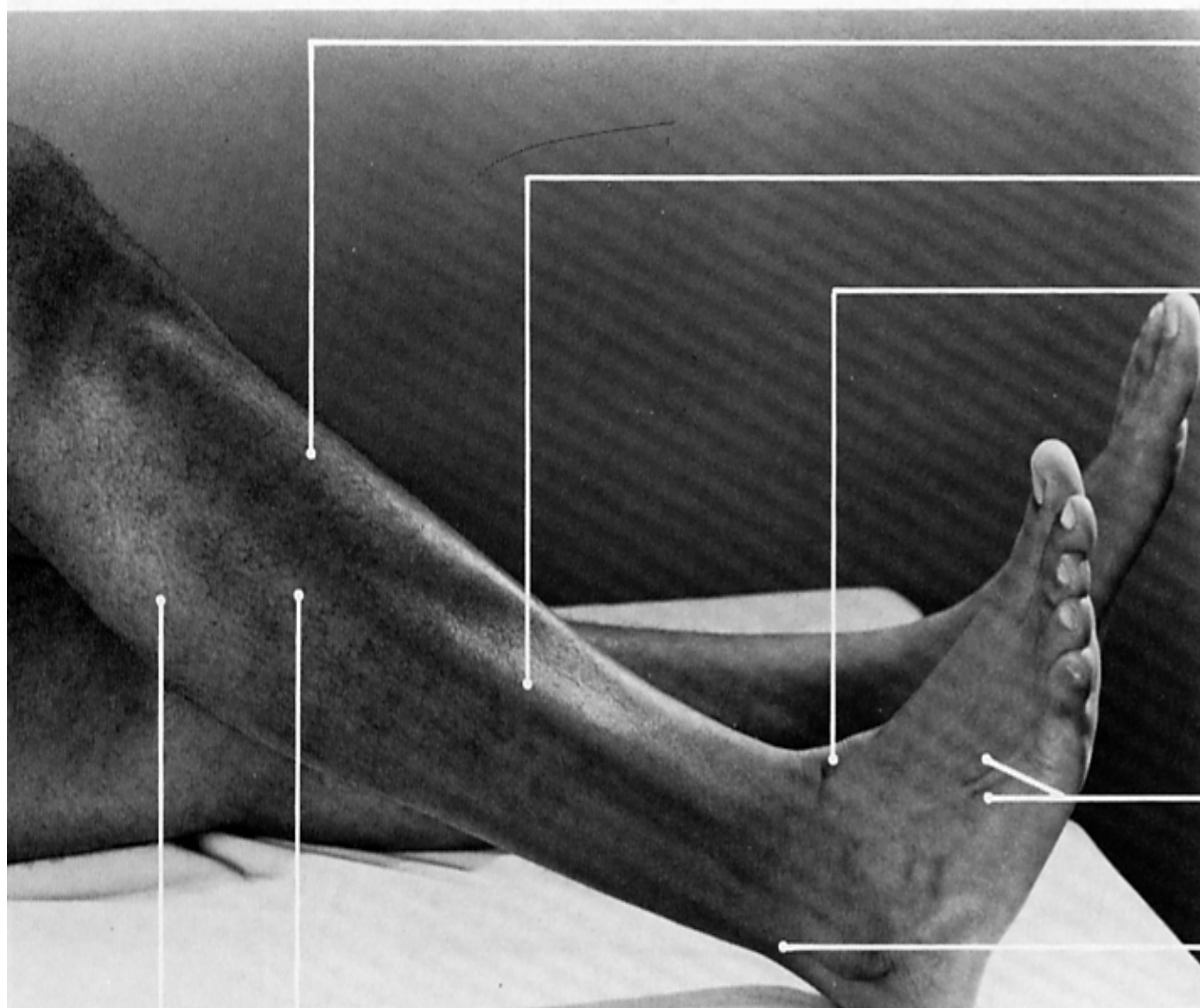
Includes bibliographies and index.

I. Neuromuscular diseases—Diagnosis. 2.
Electrodiagnosis. 3. Electromyography. I.
Johnson, Robert J. (Robert Joseph), DATE. II.
Title. [DNLM: 1. Anatomy. 2. Electrodiagnosis.
WB 141 C5587e]

RC925.7.C48 1986 616.7'4'07547 85-19884
ISBN 0-397-50687-2







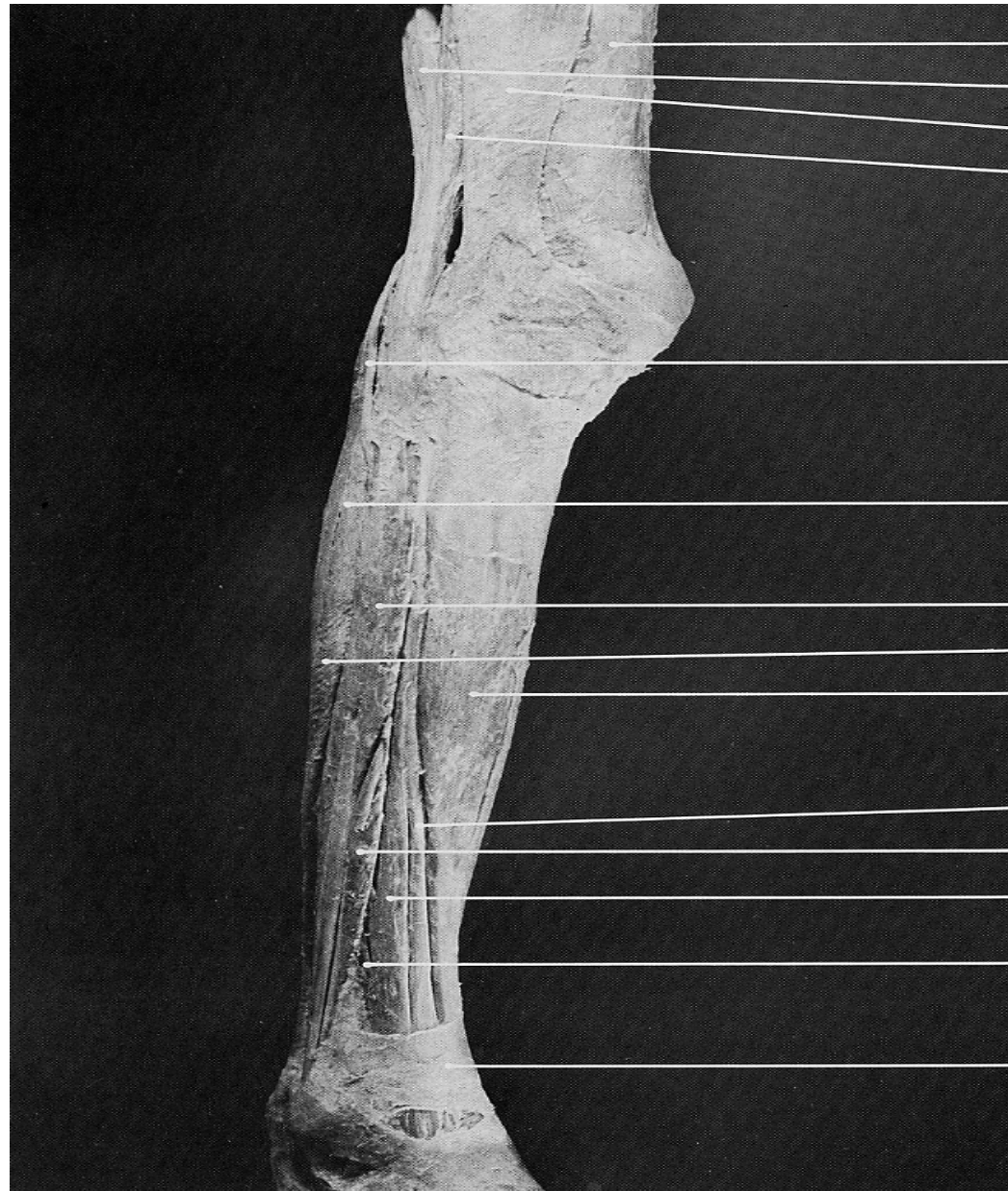tibialis anterior
(belly)

extensor digitorum
longus (belly)

tibialis anterior
(tendon)

extensor digitorum
longus (tendons)

peroneus longus
(tendon)



vastus lateralis

biceps femoris (long head)

iliotibial tract

biceps femoris (short head)

common peroneal n.

gastrocnemius (lateral head)

peroneus longus

soleus

tibialis anterior

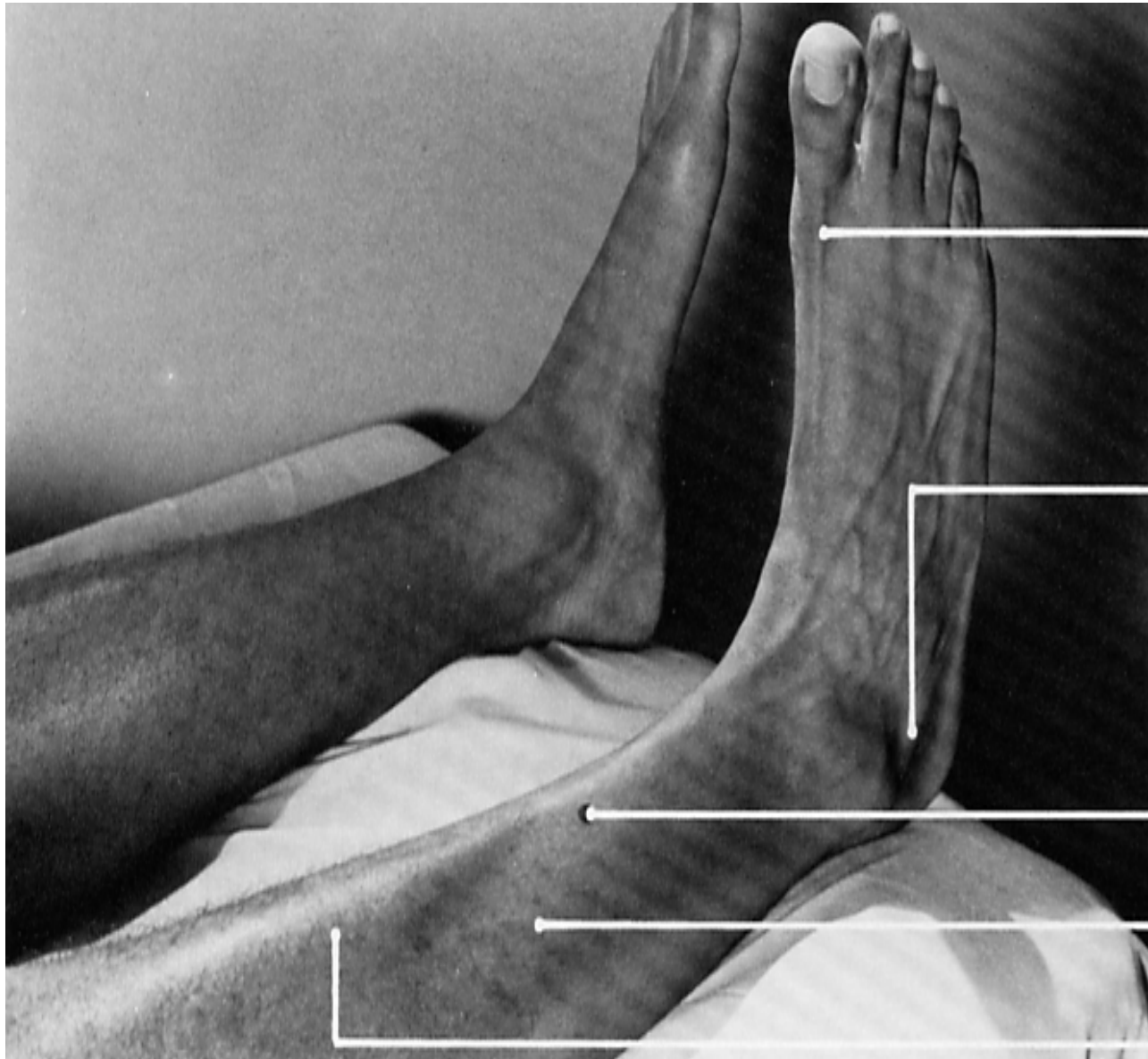extensor hallucis longus

peroneus brevis

extensor digitorum longus

peroneus tertius

extensor retinaculum



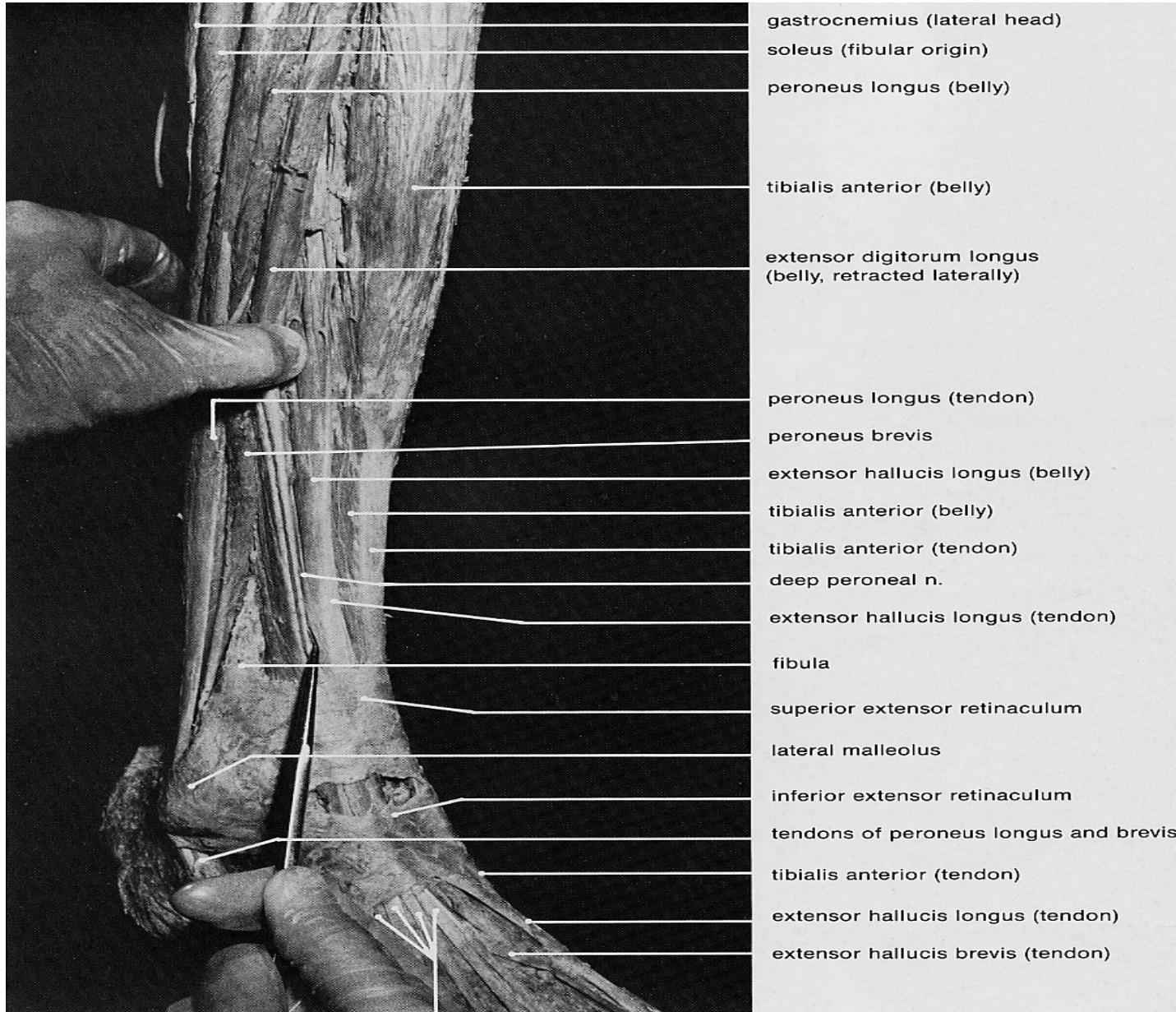
**extensor hallucis longus
(tendon)**

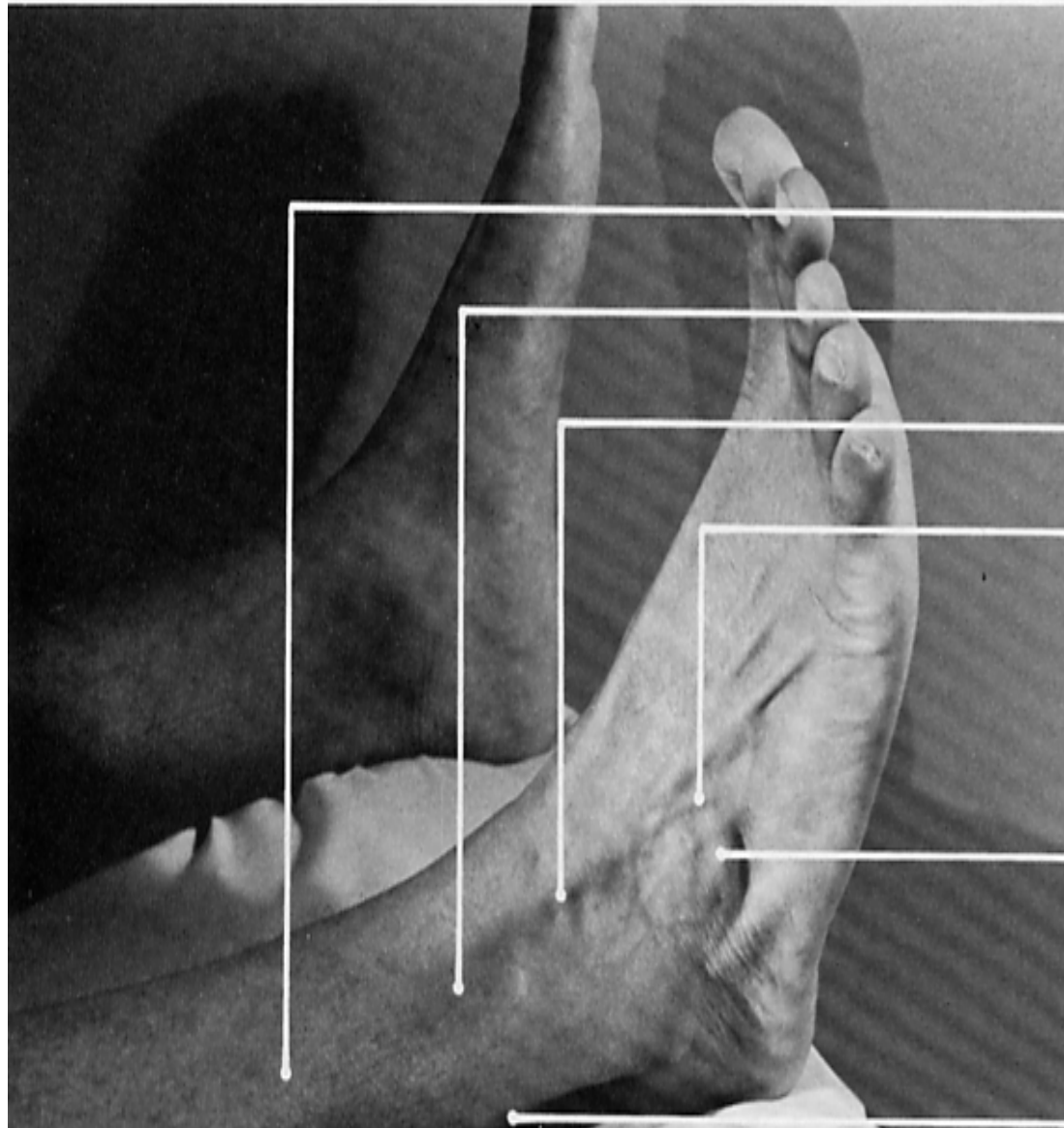
**peroneus longus
(tendon)**

**pin insertion site for
extensor hallucis longus**

extensor digitorum longus

tibialis anterior





extensor digitorum longus (belly)

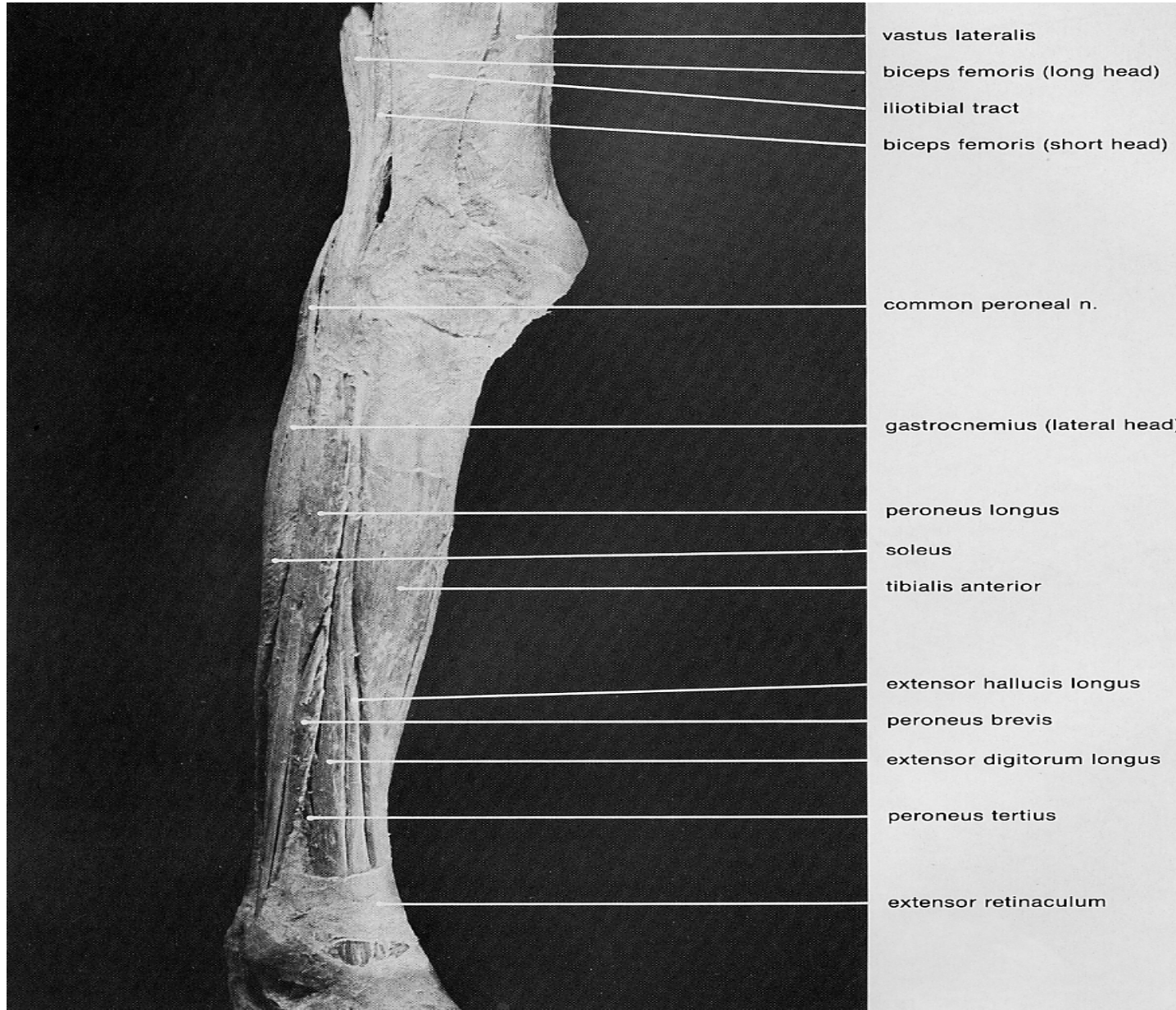
pin insertion site for **peroneus tertius**

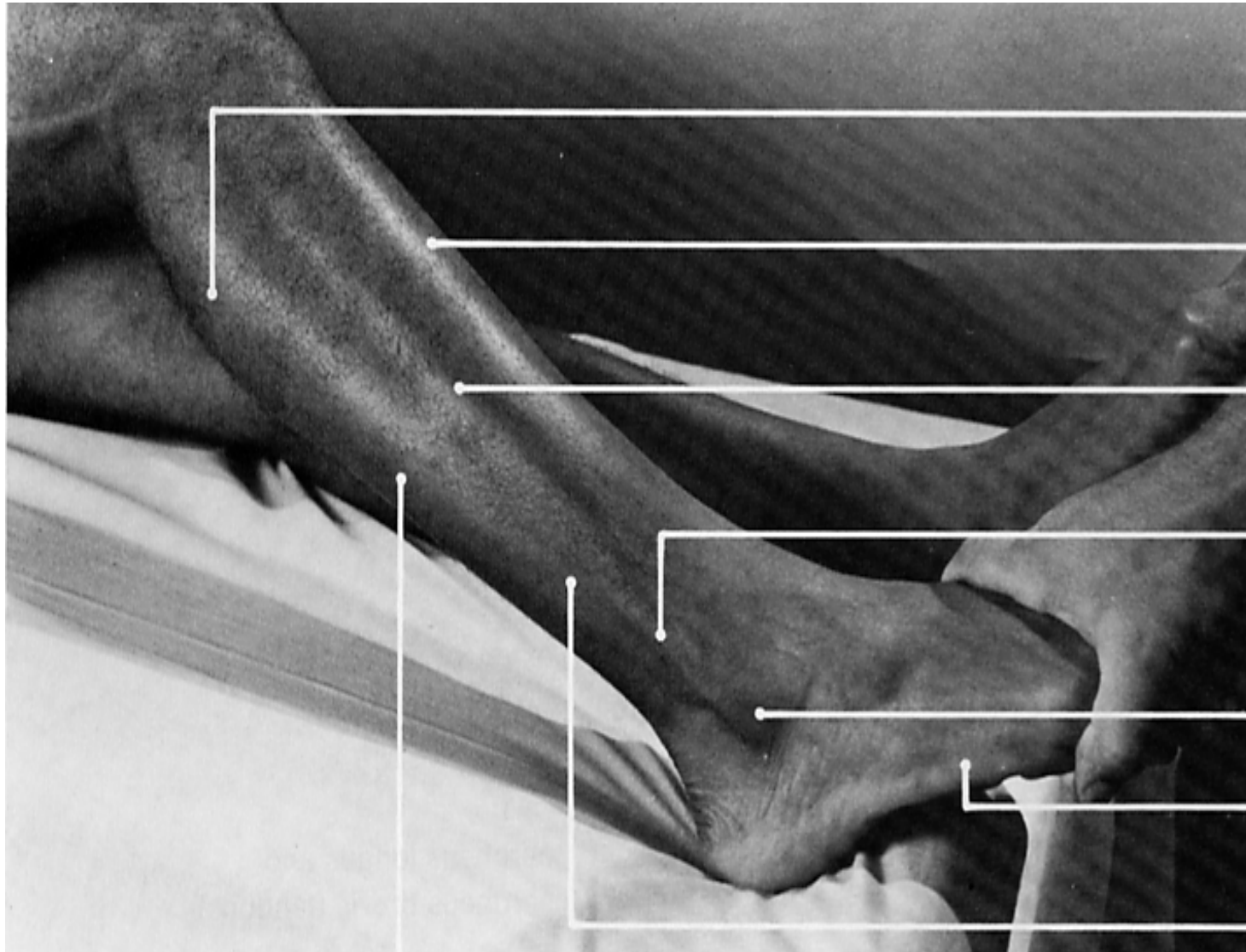extensor digitorum longus (tendons)

peroneus tertius (tendon)

extensor digitorum brevis

peroneus longus and





gastrocnemius
(lateral head)

tibialis anterior

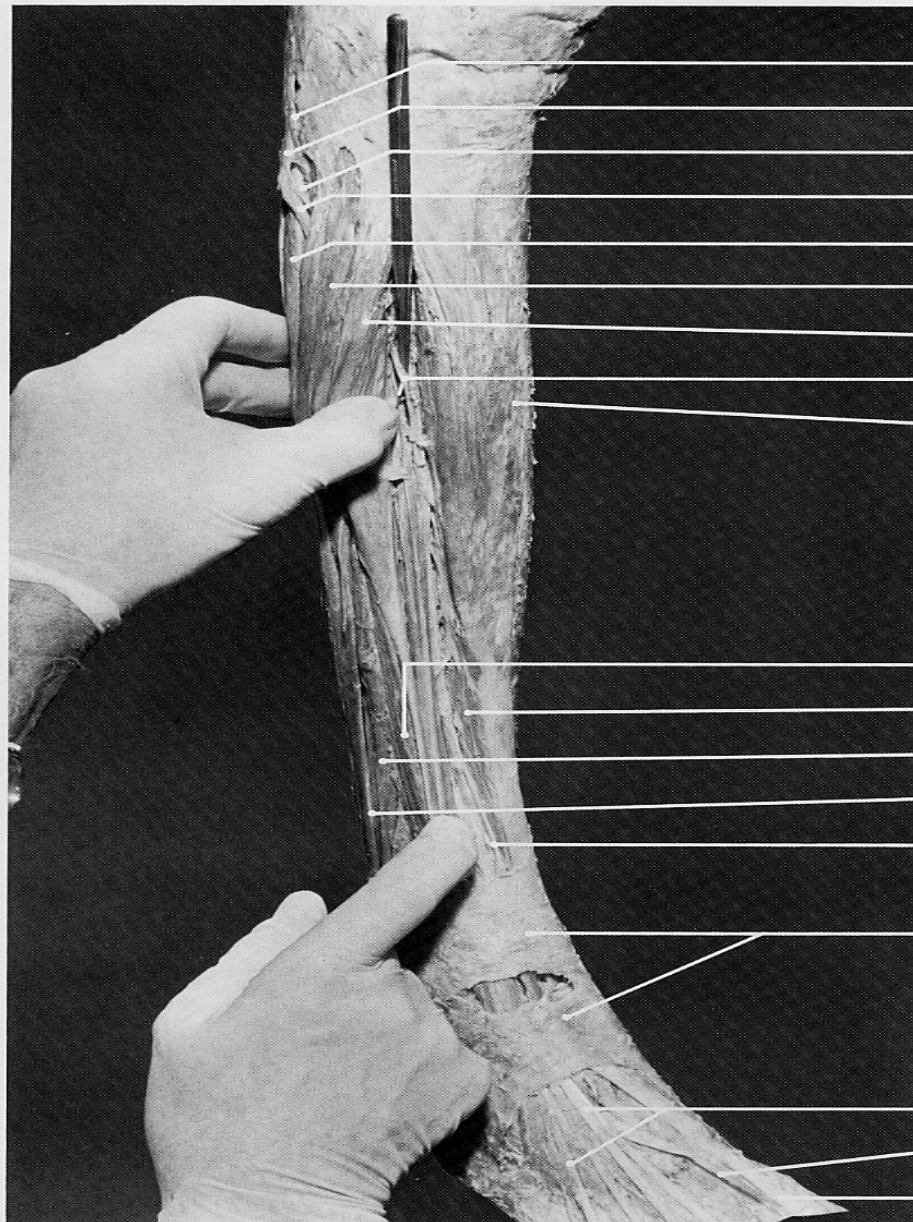
peroneus longus

**peroneus longus
(tendon) overlying**
peroneus brevis
(tendon)

lateral malleolus

abductor digiti
minimi (quinti)

peroneus brevis



biceps femoris (tendon, long head)

common peroneal n.

deep peroneal n.

superficial peroneal n.

soleus (fibular head)

peroneus longus (belly)

extensor digitorum longus (belly)

deep peroneal n.

tibialis anterior

extensor digitorum longus (belly)

tibialis anterior

peroneus brevis

peroneus longus (tendon)

deep peroneal n.

extensor retinaculum

extensor digitorum longus (tendons)

extensor hallucis brevis (tendon)

extensor hallucis longus (tendon)

