



Human Anatomy in Motion: Anterior & Medial Thigh Muscles

**Jennifer Chu, M.D.
Electrodiagnosis: An Anatomical and Clinical Approach
Lippincott, Phila, 1986**


Copyright © Jennifer Chu, M.D.

Chu-Andrews
Johnson

Electrodiagnosis
An Anatomical and Clinical Approach

Electrodiagnosis

An Anatomical and Clinical Approach



Jennifer Chu-Andrews • Robert J. Johnson



elsevier



Sponsoring Editor: Sanford J. Robinson
Manuscript Editor: Lee Henderson
Indexer: Ann Cassar
Design Director: Tracy Baldwin
Designer: Arlene Putterman
Production Supervisor: J. Corey Gray
Production Assistant: Kathleen R. Diamond
Compositor: Ruttle, Shaw & Wetherill, Inc.
Printer/Binder: Halliday Lithograph

Copyright © 1986, by Jennifer Chu-Andrews.
All rights reserved. No part of this book may be
used or reproduced in any manner whatsoever
without written permission except for brief
quotations embodied in critical articles and
reviews. Printed in the United States of
America. For information write J. B. Lippincott
Company, East Washington Square,
Philadelphia, Pennsylvania 19105.

6 5 4 3 2 1

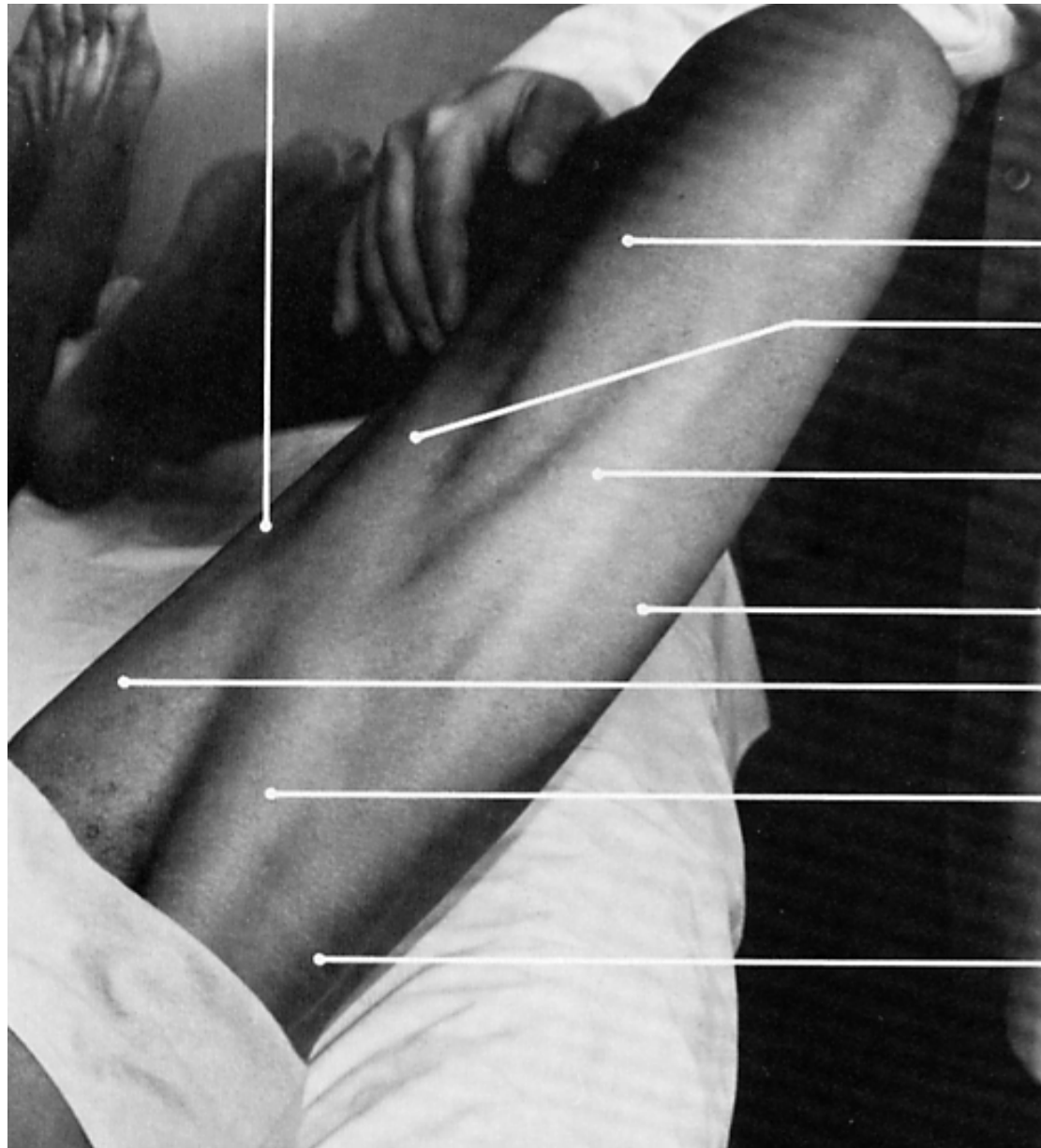
Library of Congress Cataloging-in- Publication Data

Chu-Andrews, Jennifer.
Electrodiagnosis: an anatomical and clinical
approach.

Includes bibliographies and index.

I. Neuromuscular diseases—Diagnosis. 2.
Electrodiagnosis. 3. Electromyography. I.
Johnson, Robert J. (Robert Joseph), DATE. II.
Title. [DNLM: 1. Anatomy. 2. Electrodiagnosis.
WB 141 C5587e]

RC925.7.C48 1986 616.7'4'07547 85-19884
ISBN 0-397-50687-2



vastus medialis

sartorius

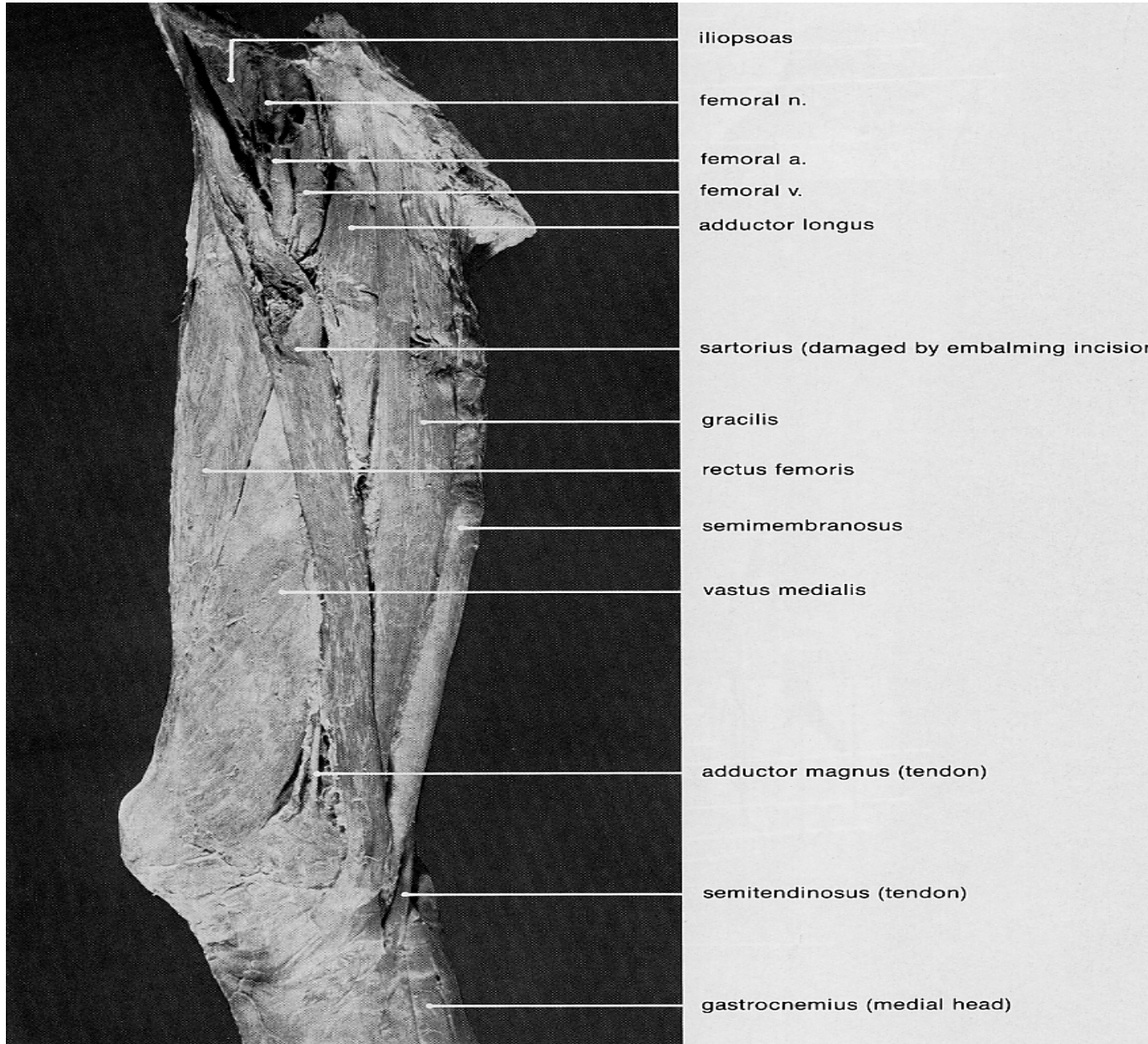
rectus femoris

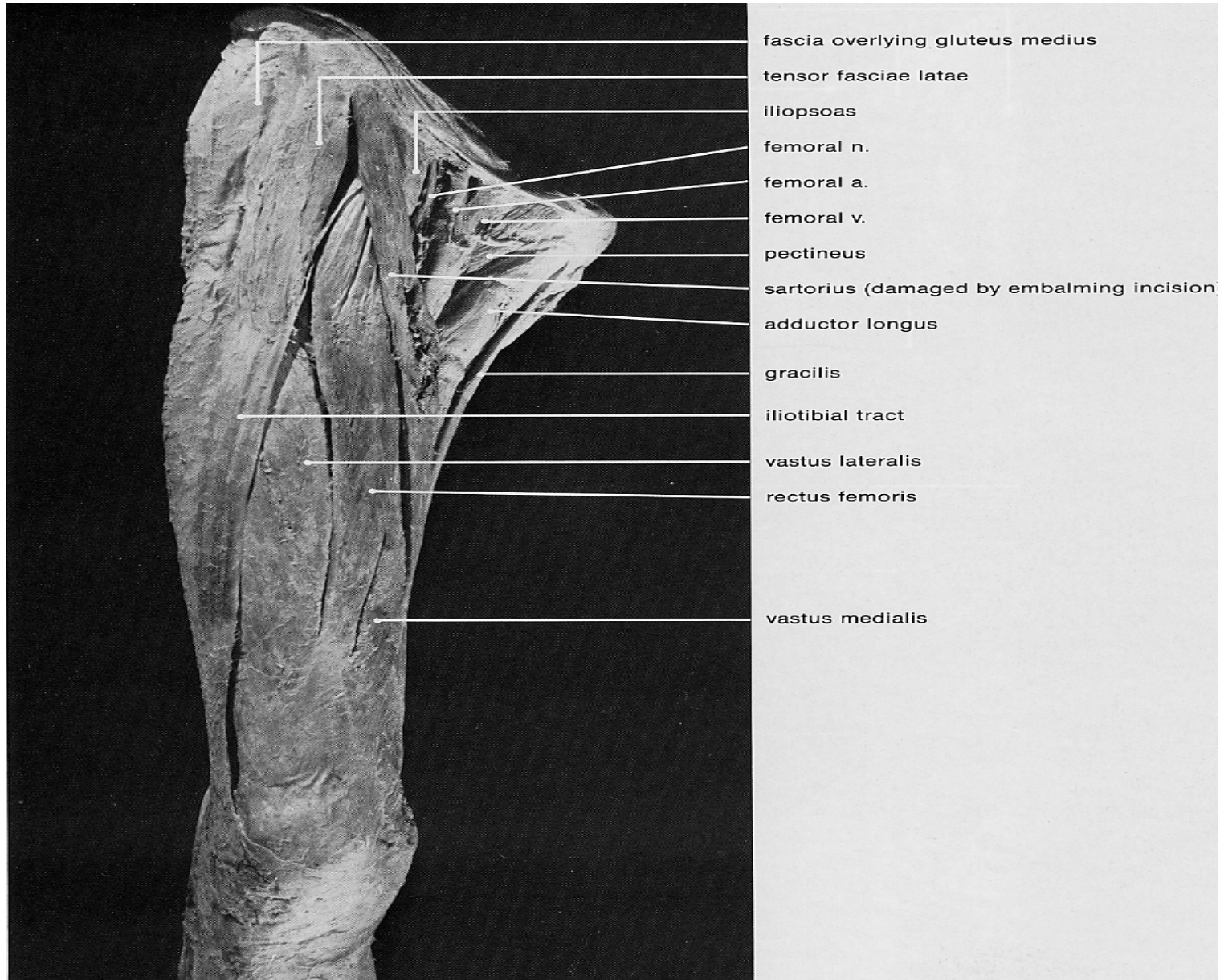
vastus lateralis

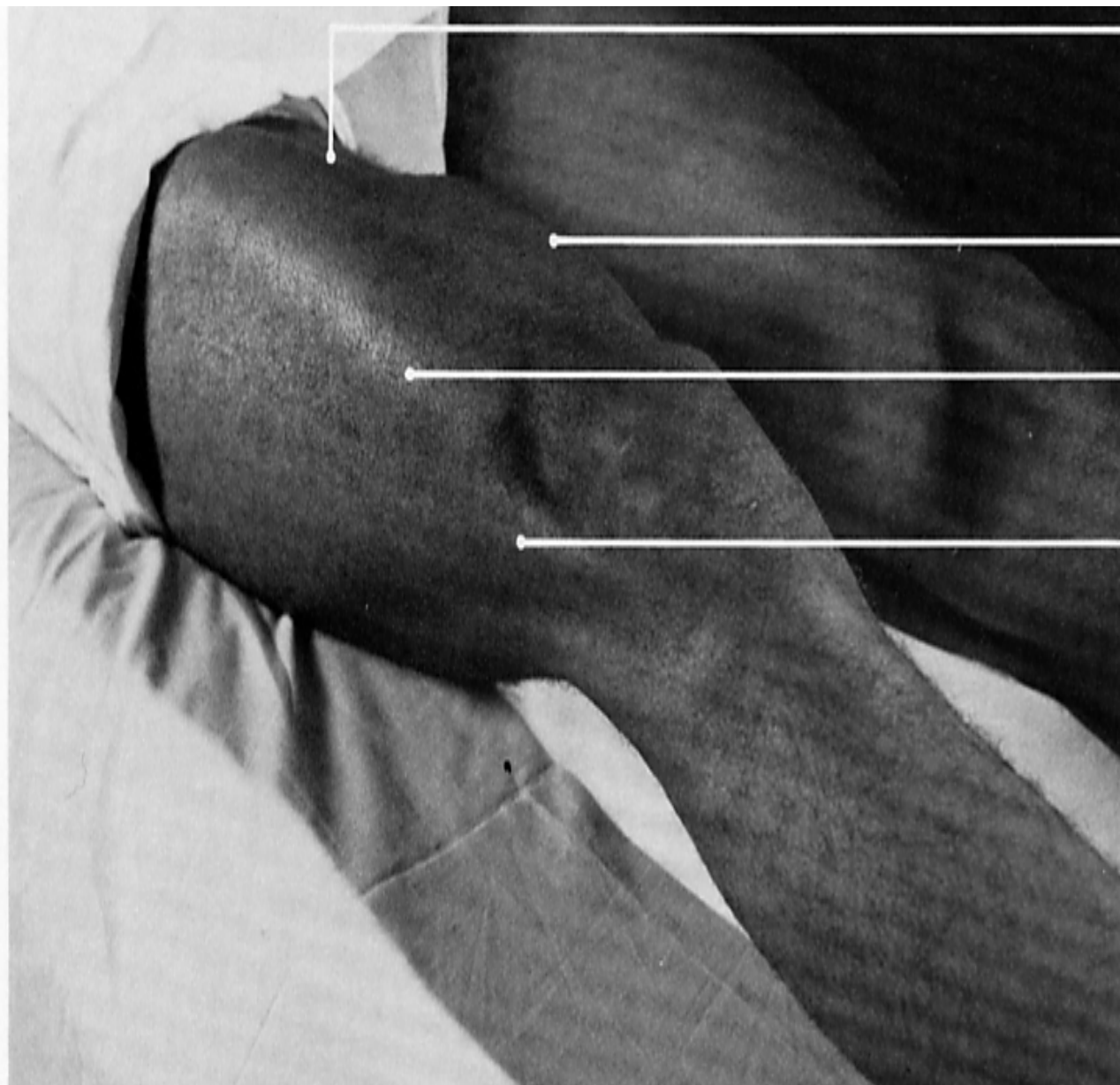
adductor longus

sartorius

tensor fasciae latae





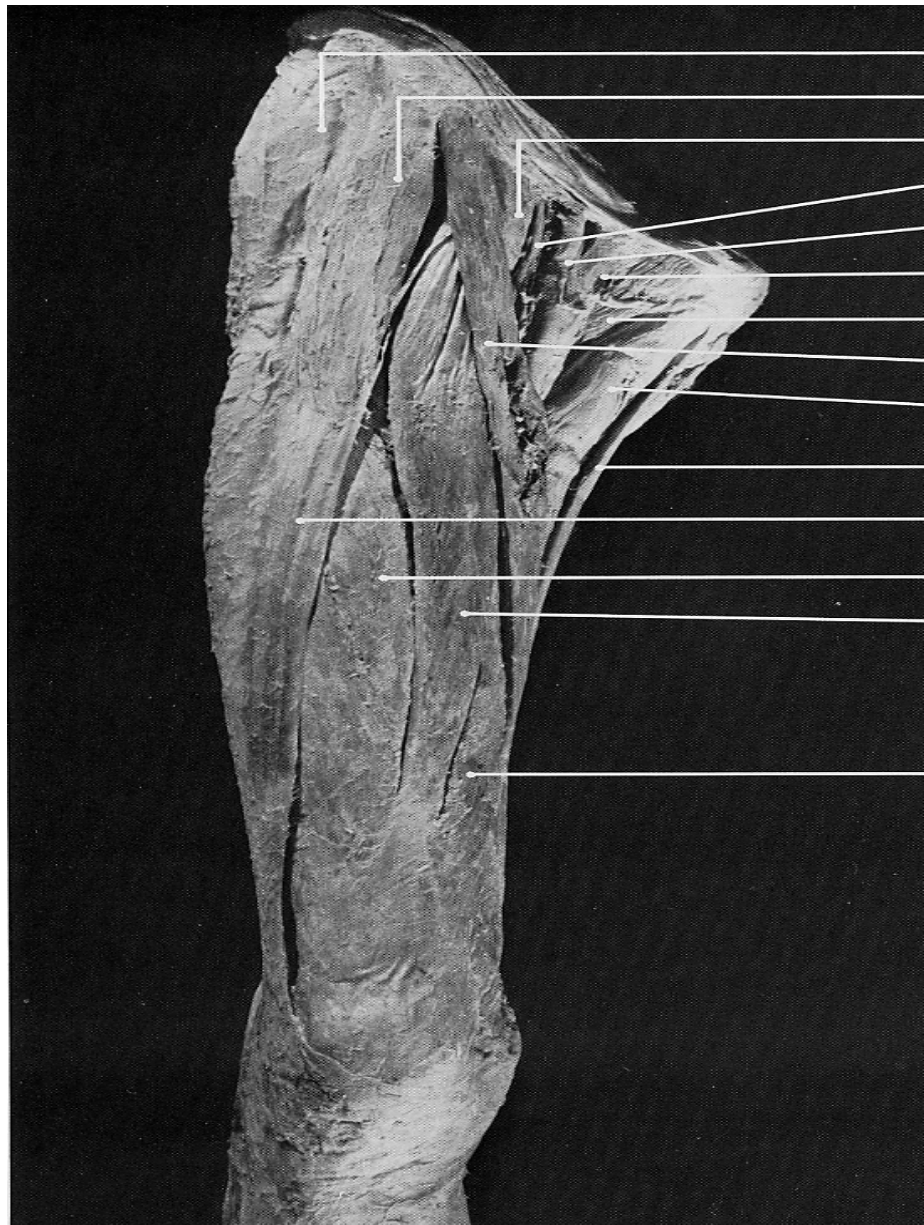


rectus femoris

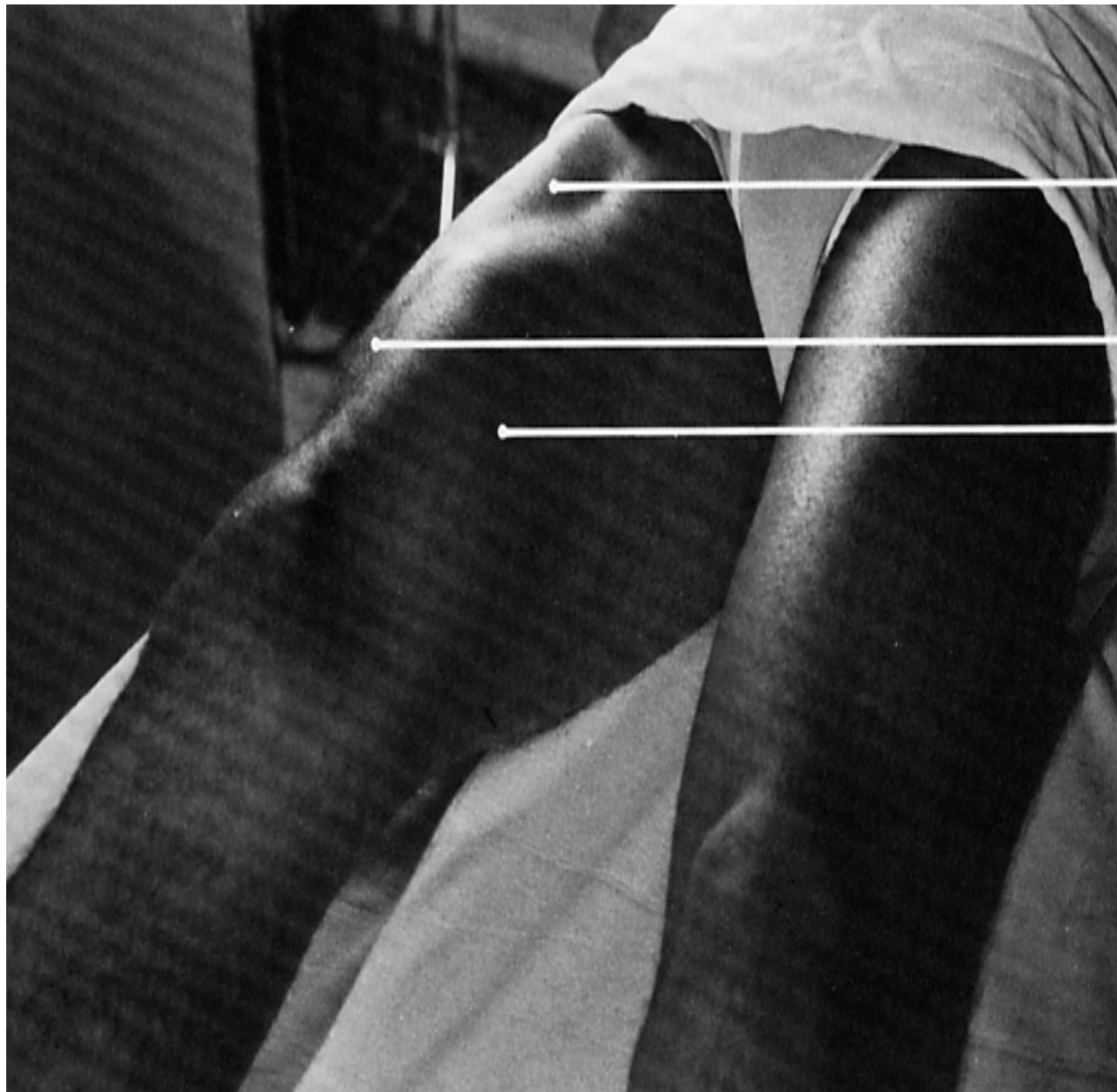
vastus medialis

vastus lateralis

iliotibial tract



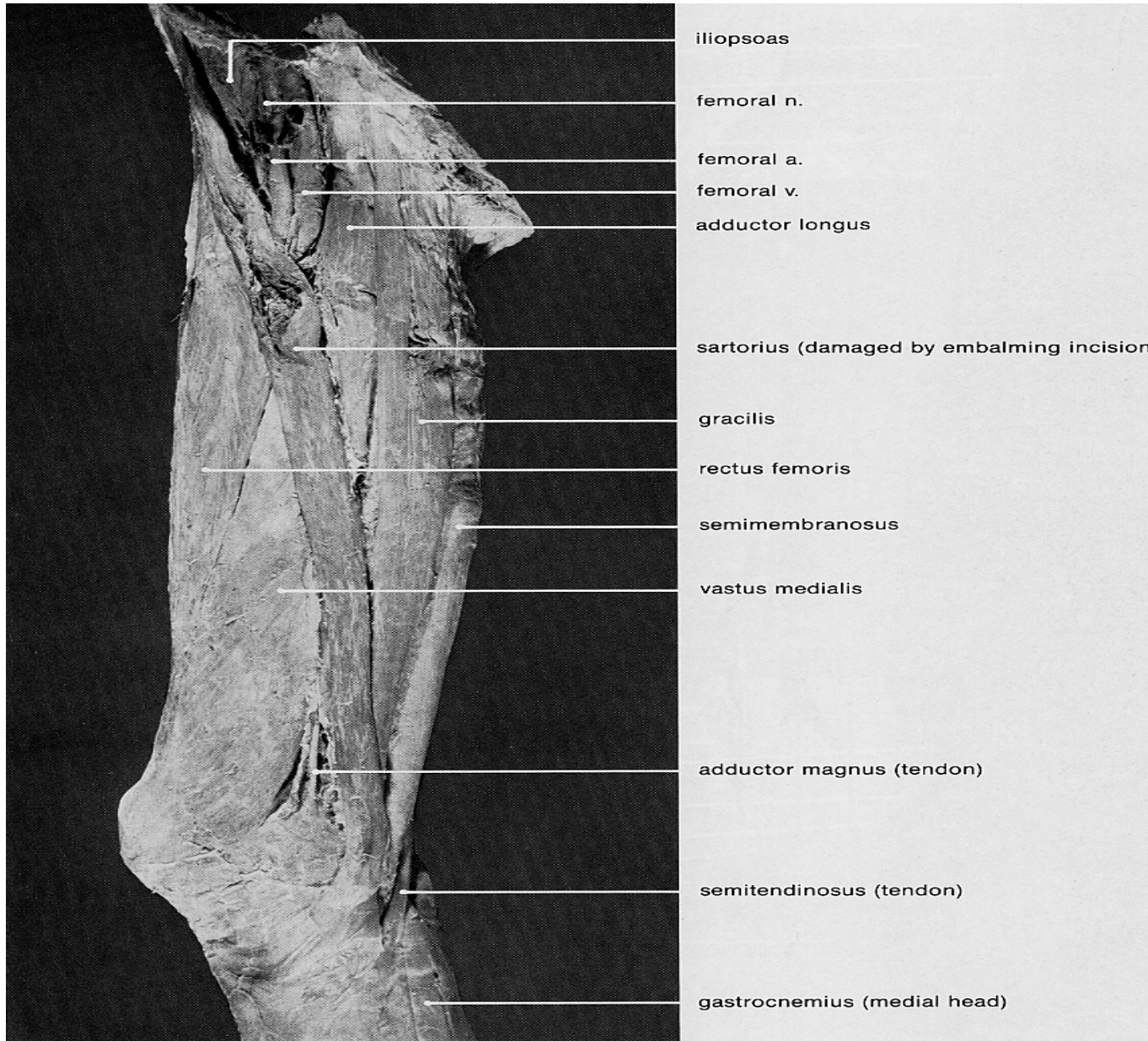
- fascia overlying gluteus medius
- tensor fasciae latae
- iliopsoas
- femoral n.
- femoral a.
- femoral v.
- pectineus
- sartorius (damaged by embalming incision)
- adductor longus
- gracilis
- iliotibial tract
- vastus lateralis
- rectus femoris
- vastus medialis

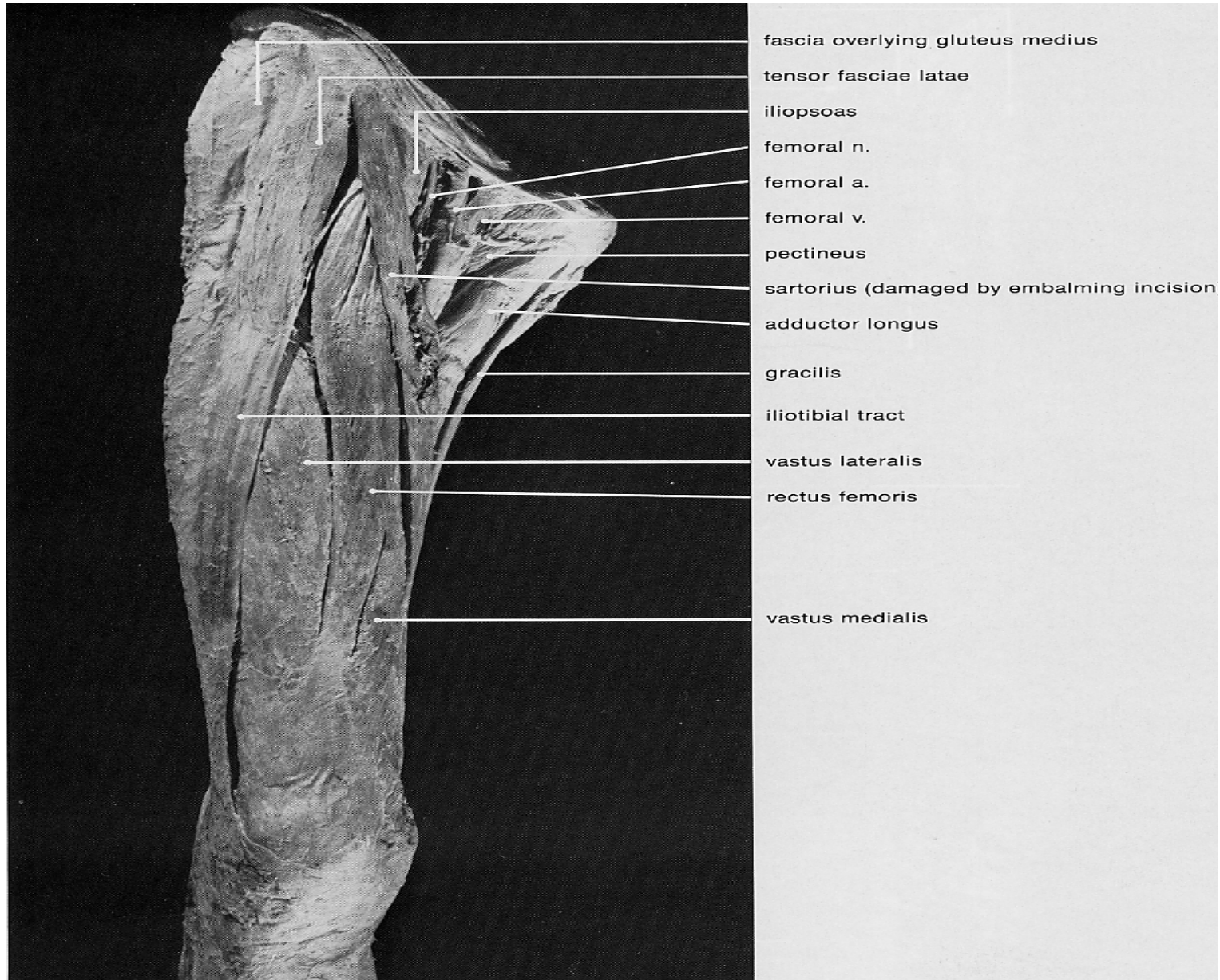


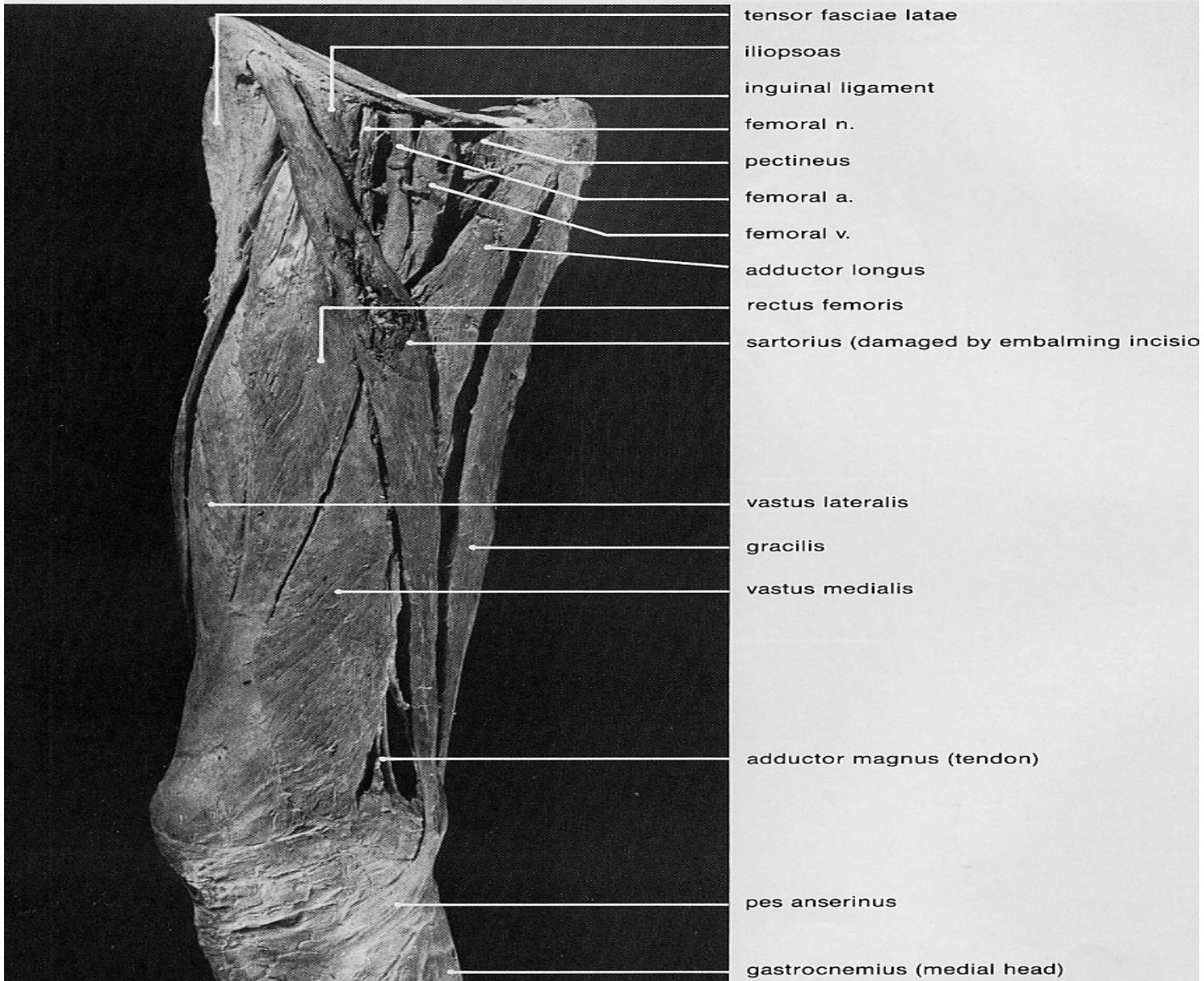
rectus femoris


vastus lateralis

vastus medialis









rectus femoris

vastus medialis

gracilis

semitendinosus

