



Human Anatomy in Motion: Shoulder Muscles

**Jennifer Chu, M.D.
Electrodiagnosis: An Anatomical and Clinical Approach
Lippincott, Phila, 1986**


Copyright © Jennifer Chu, M.D.

Chu-Andrews
Johnson

Electrodiagnosis
An Anatomical and Clinical Approach

Electrodiagnosis

An Anatomical and Clinical Approach



Jennifer Chu-Andrews • Robert J. Johnson



elsevier



Sponsoring Editor: Sanford J. Robinson
Manuscript Editor: Lee Henderson
Indexer: Ann Cassar
Design Director: Tracy Baldwin
Designer: Arlene Putterman
Production Supervisor: J. Corey Gray
Production Assistant: Kathleen R. Diamond
Compositor: Ruttle, Shaw & Wetherill, Inc.
Printer/Binder: Halliday Lithograph

Copyright © 1986, by Jennifer Chu-Andrews.
All rights reserved. No part of this book may be
used or reproduced in any manner whatsoever
without written permission except for brief
quotations embodied in critical articles and
reviews. Printed in the United States of
America. For information write J. B. Lippincott
Company, East Washington Square,
Philadelphia, Pennsylvania 19105.


6 5 4 3 2 1

**Library of Congress Cataloging-in-
Publication Data**

Chu-Andrews, Jennifer.
Electrodiagnosis: an anatomical and clinical
approach.

Includes bibliographies and index.

I. Neuromuscular diseases—Diagnosis. 2.
Electrodiagnosis. 3. Electromyography. I.
Johnson, Robert J. (Robert Joseph), DATE. II.
Title. [DNLM: 1. Anatomy. 2. Electrodiagnosis.
WB 141 C5587e]
RC925.7.C48 1986 616.7'4'07547 85-19884
ISBN 0-397-50687-2



triceps
(long head)

infraspinatus

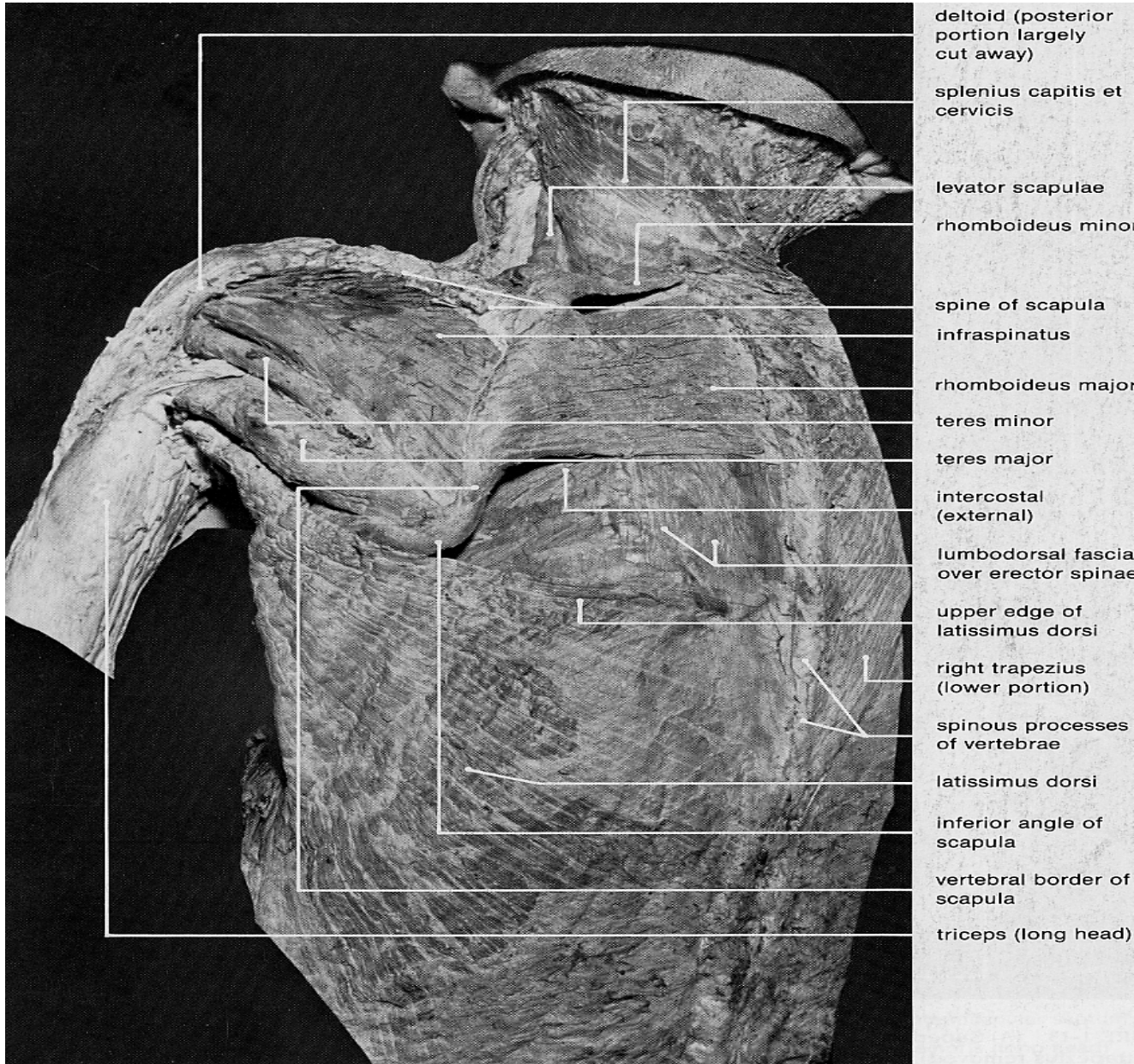
teres major


latissimus dor
(lateral border)

latissimus dor
(upper border)

trapezius
(middle portio

trapezius
(upper portior





triceps (long head)

triceps (lateral head)

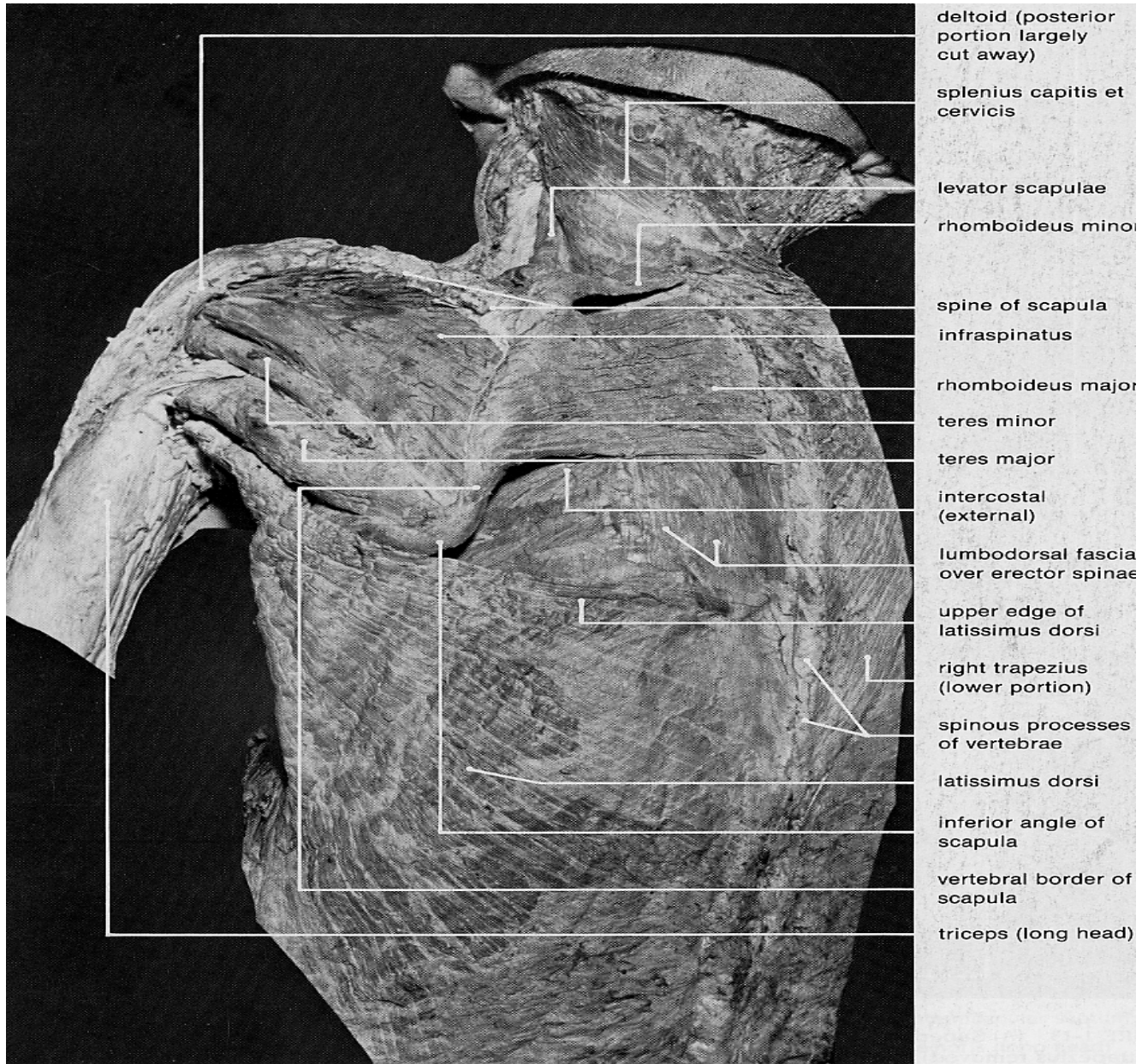
pin insertion site for **teres minor**

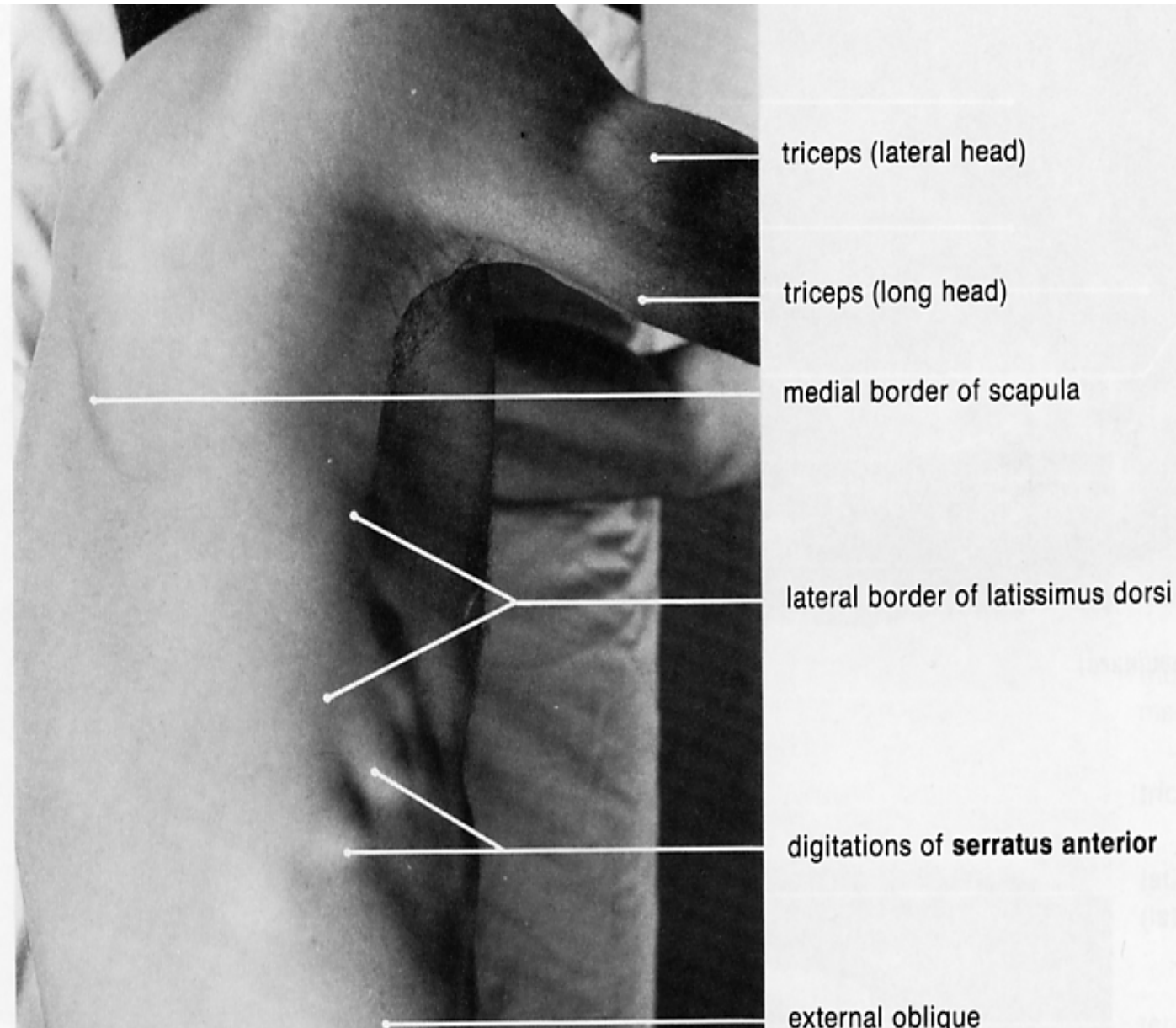
deltoid (middle portion)

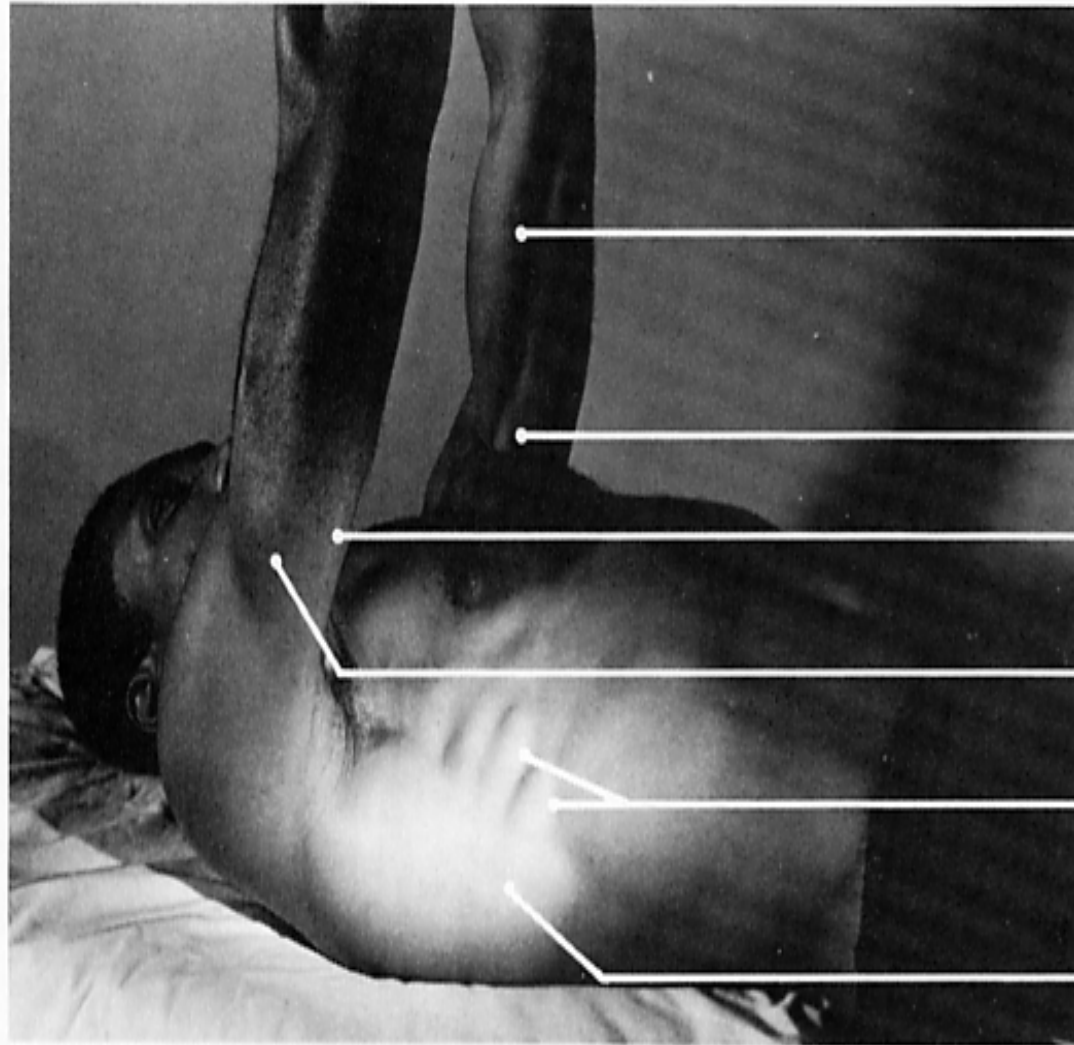
lower edge of deltoid (posterior portio

infraspinatus

teres major







biceps brachii

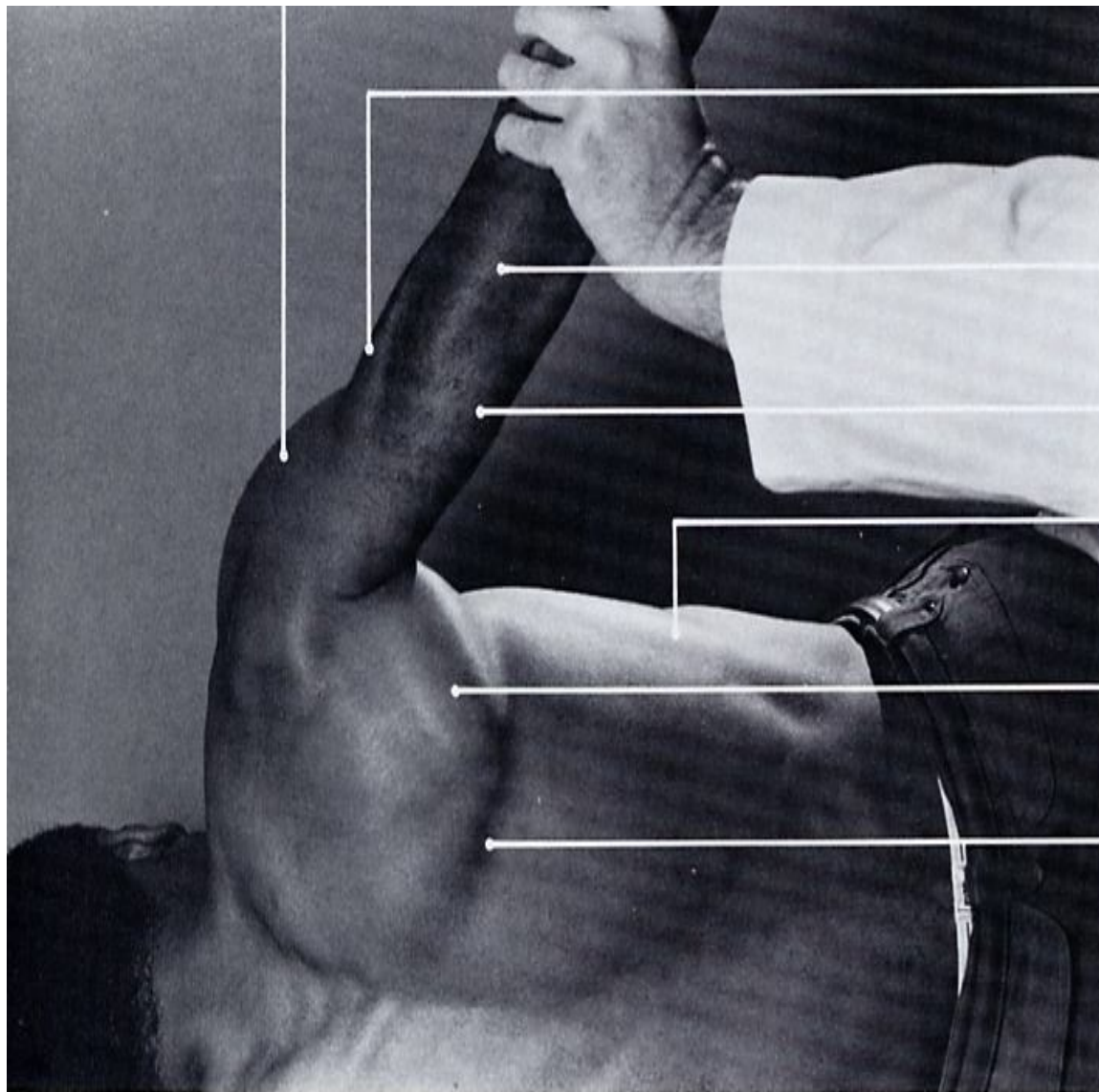
coracobrachialis

triceps (long head)

triceps (lateral head)

digitations of **serratus anterior**

latissimus dorsi



triceps (lateral head)

triceps tendon overlying
medial head of triceps

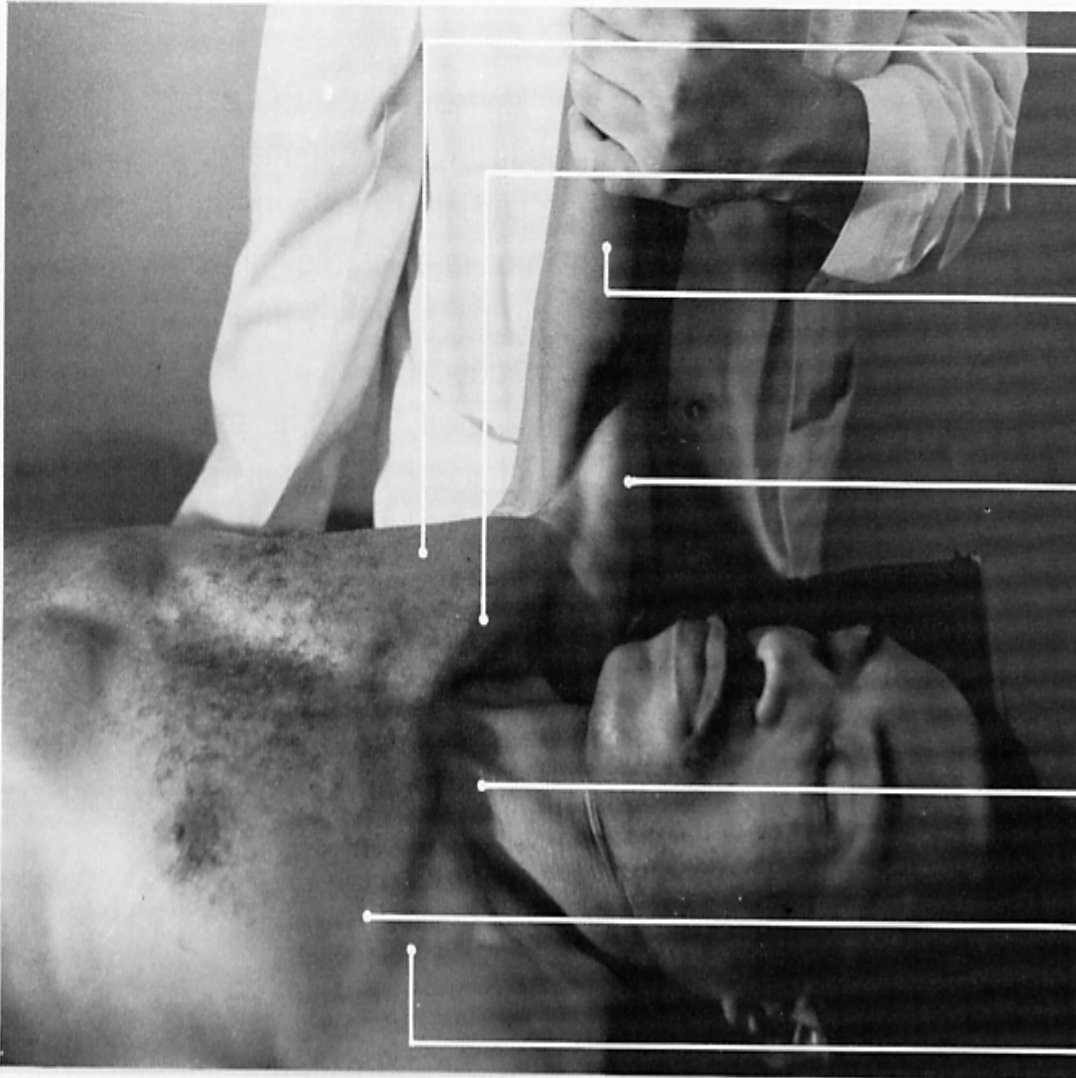triceps (long head)

**latissimus dorsi
(lateral border)**

teres major

**latissimus dorsi
(upper border)**

FIGURE 2-32 Latissimus dorsi.



pectoralis major
(sternal portion)

**pectoralis major
(clavicular portion, tensed)**

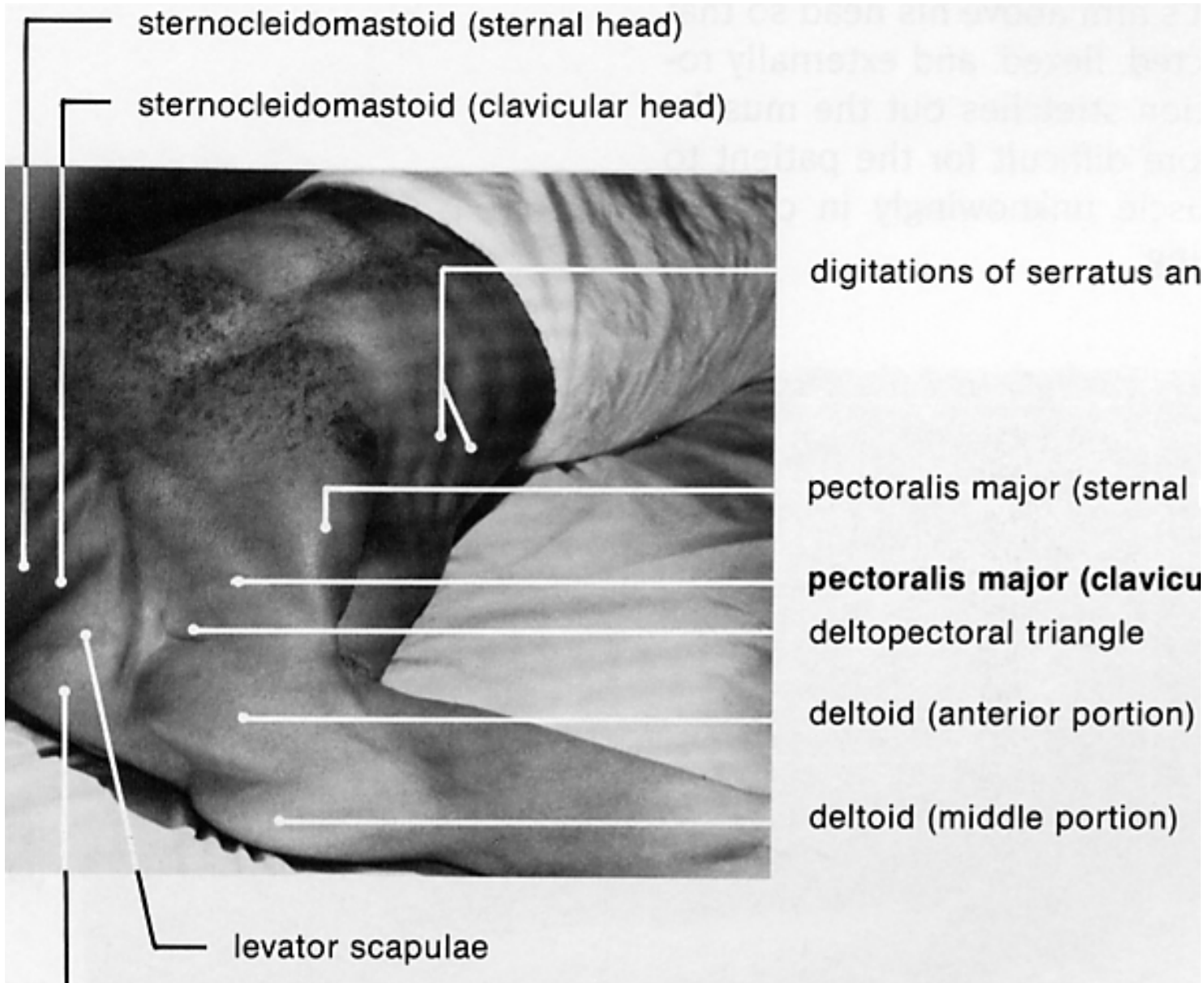
biceps brachii

deltoid
(anterior portion)

sternocleidomastoid

**pectoralis major
(clavicular portion, relaxed)**

deltopectoral triangle



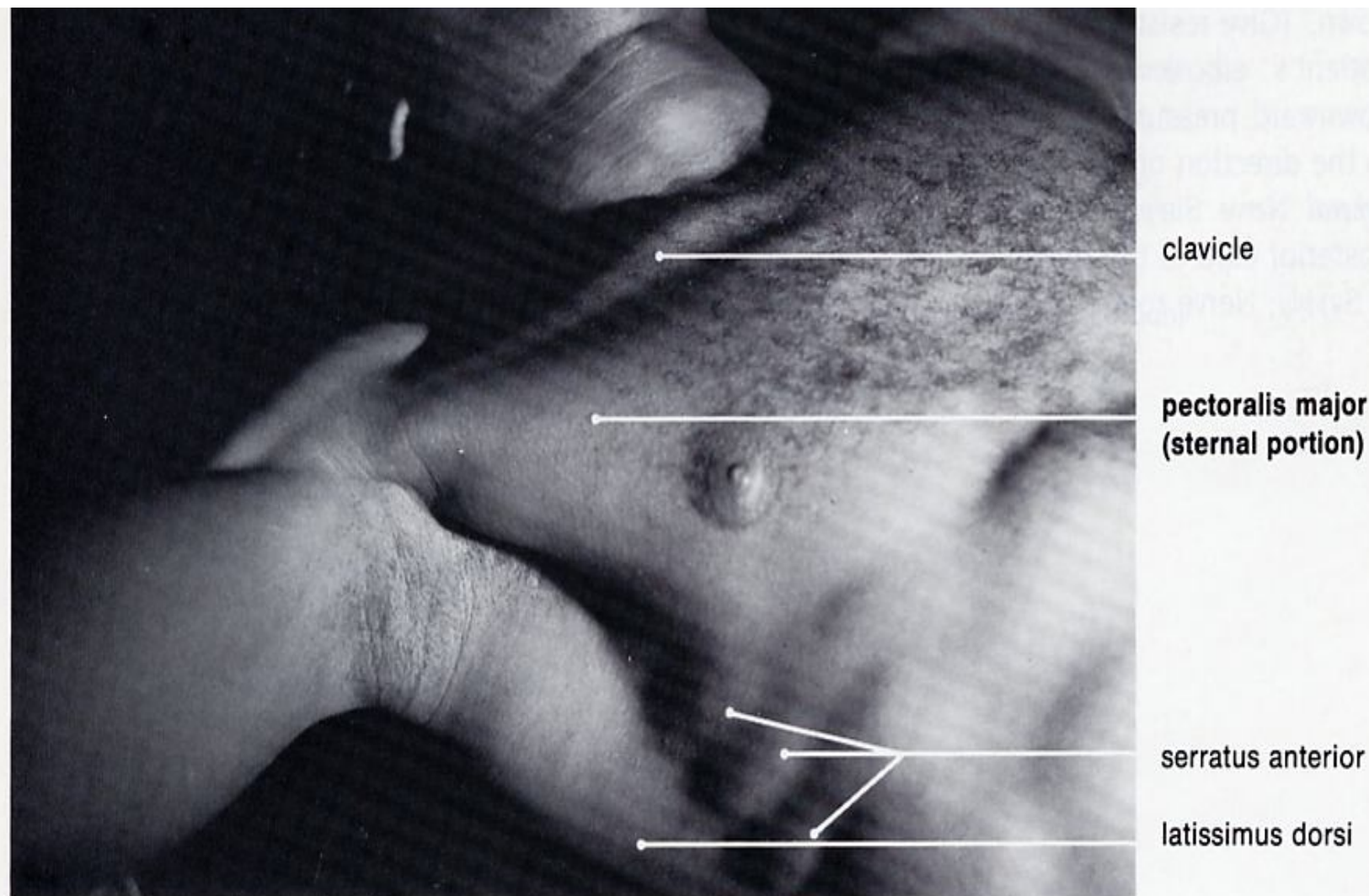


FIGURE 2-34 Pectoralis major (sternal portion).