



Human Anatomy in Motion: Shoulder & Chest Muscles

**Jennifer Chu, M.D.
Electrodiagnosis: An Anatomical and Clinical Approach
Lippincott, Phila, 1986**


Copyright © Jennifer Chu, M.D.

Chu-Andrews
Johnson

Electrodiagnosis
An Anatomical and Clinical Approach

Electrodiagnosis

An Anatomical and Clinical Approach



Jennifer Chu-Andrews • Robert J. Johnson



Elsevier



Sponsoring Editor: Sanford J. Robinson
Manuscript Editor: Lee Henderson
Indexer: Ann Cassar
Design Director: Tracy Baldwin
Designer: Arlene Putterman
Production Supervisor: J. Corey Gray
Production Assistant: Kathleen R. Diamond
Compositor: Ruttle, Shaw & Wetherill, Inc.
Printer/Binder: Halliday Lithograph

Copyright © 1986, by Jennifer Chu-Andrews.
All rights reserved. No part of this book may be
used or reproduced in any manner whatsoever
without written permission except for brief
quotations embodied in critical articles and
reviews. Printed in the United States of
America. For information write J. B. Lippincott
Company, East Washington Square,
Philadelphia, Pennsylvania 19105.

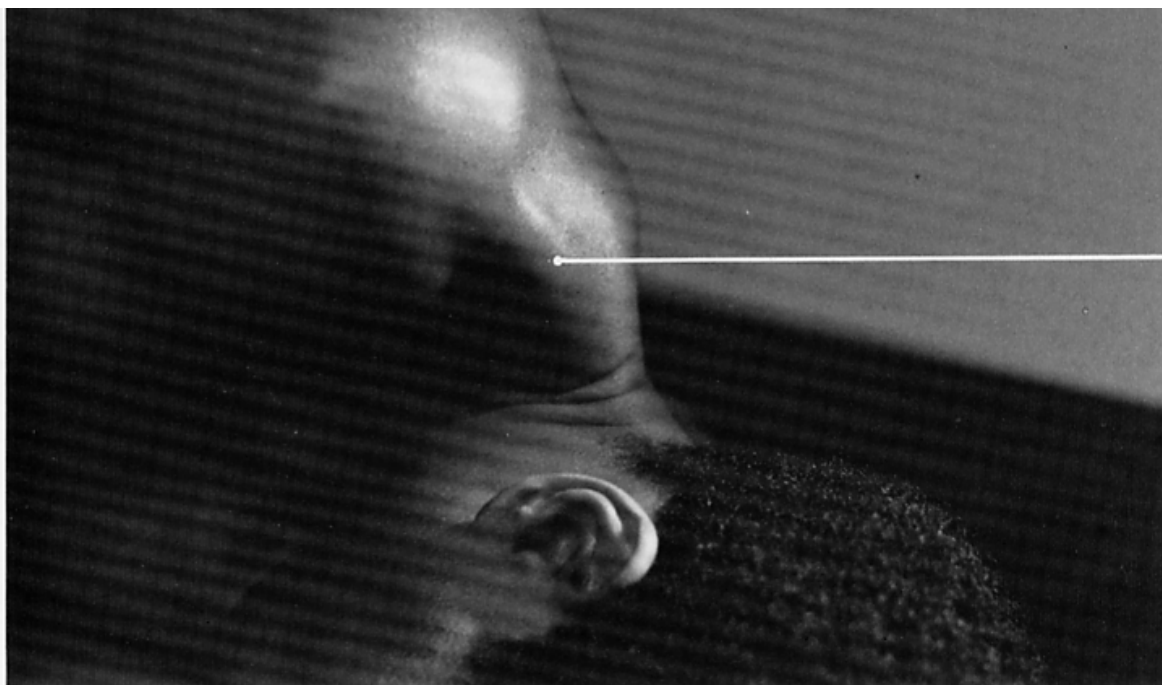
6 5 4 3 2 1

**Library of Congress Cataloging-in-
Publication Data**


Chu-Andrews, Jennifer.
Electrodiagnosis: an anatomical and clinical
approach.

Includes bibliographies and index.

I. Neuromuscular diseases—Diagnosis. 2.
Electrodiagnosis. 3. Electromyography. I.
Johnson, Robert J. (Robert Joseph), DATE. II.
Title. [DNLM: 1. Anatomy. 2. Electrodiagnosis.
WB 141 C5587e]
RC925.7.C48 1986 616.7'4'07547 85-19884
ISBN 0-397-50687-2




**trapezius
(upper portion)**



trapezius (upper portion)

**sternocleidomastoid
(clavicular head)**

**sternocleidomastoid
(sternal head)**



spines capitis
et cervicis

ligamentum nuchae

trapezius
(upper portion)

spinous processes
of vertebrae

lower border of delt
(posterior portion)

trapezius
(middle portion)

rhomboideus major

infraspinatus

lumbodorsal fascia

intercostal (external)

trapezius
(lower portion)

upper edge of
latissimus dorsi,
forming lower border
triangle of auscultat

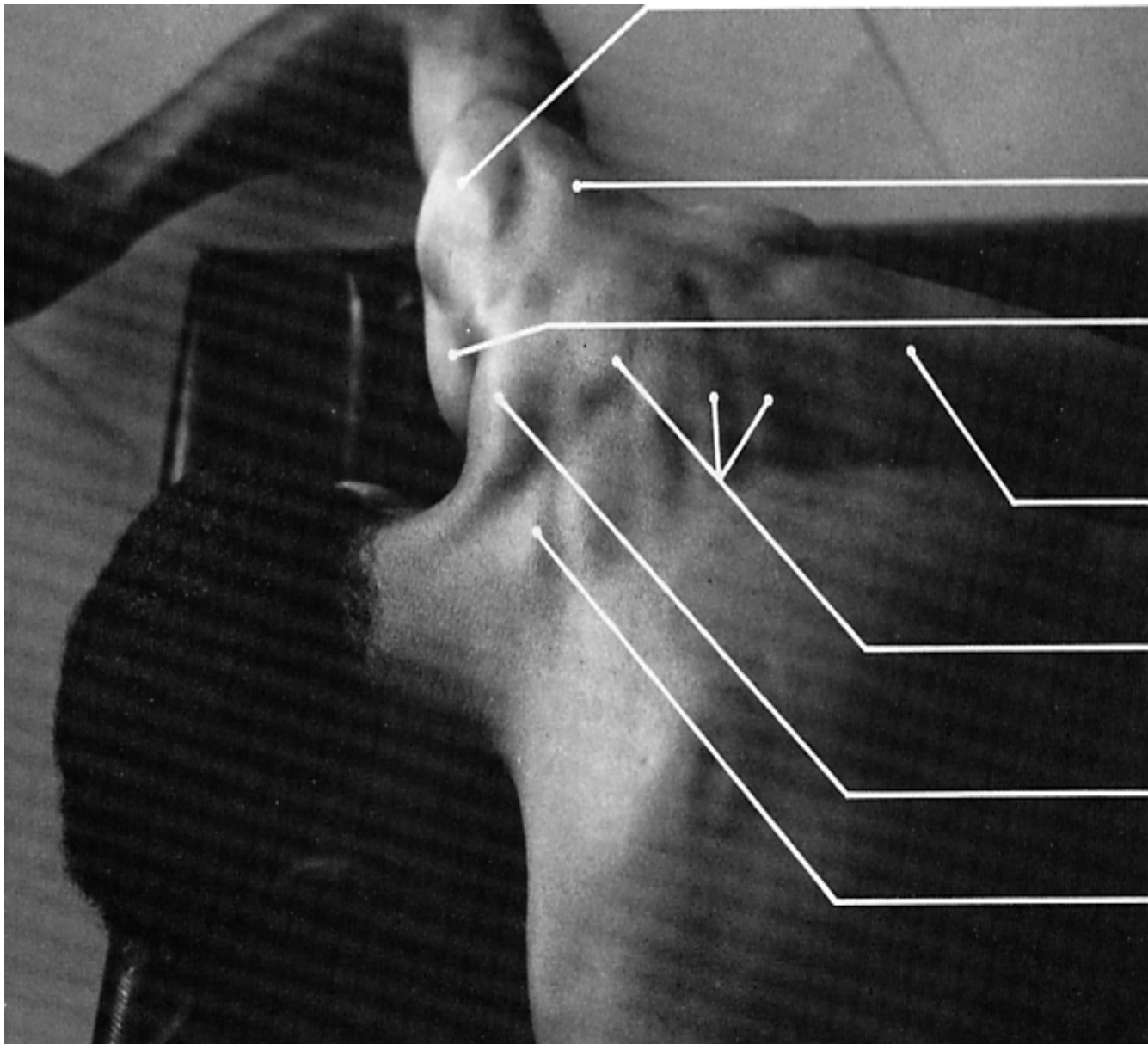
latissimus dorsi

vertebral border
of scapula

teres major

teres minor

triceps (long head)



(middle portior

deltoid
(posterior porti

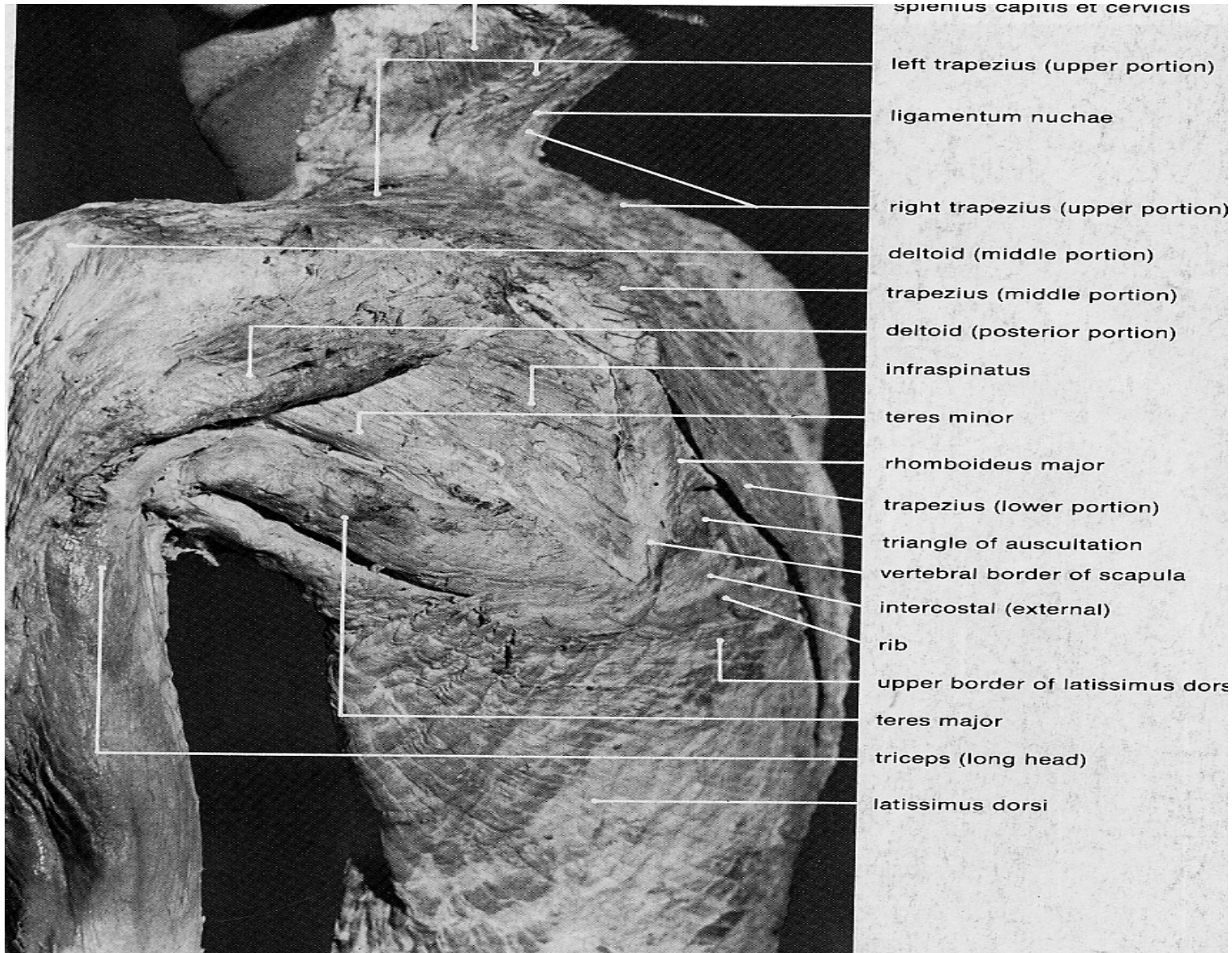
deltoid
(anterior portio

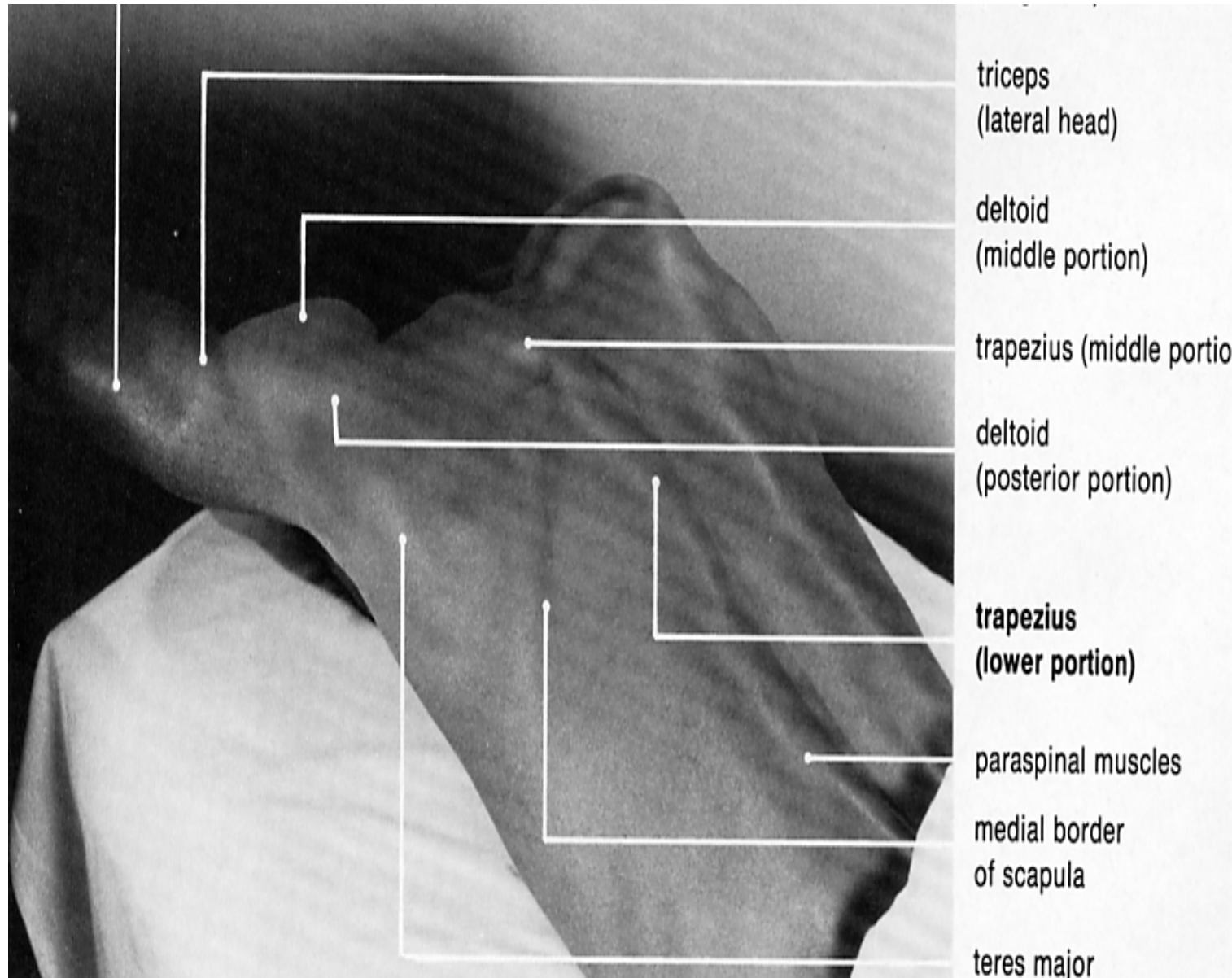
trapezius
(lower portion)

trapezius
(middle portio

trapezius
(upper portion)

C7 spinous pro





triceps
(lateral head)

deltoid
(middle portion)

trapezius (middle portion)


deltoid
(posterior portion)

trapezius
(lower portion)

paraspinal muscles

medial border
of scapula

teres major



deltoid (anterior portion)

trapezius (upper portion)

omohyoid (inferior belly)

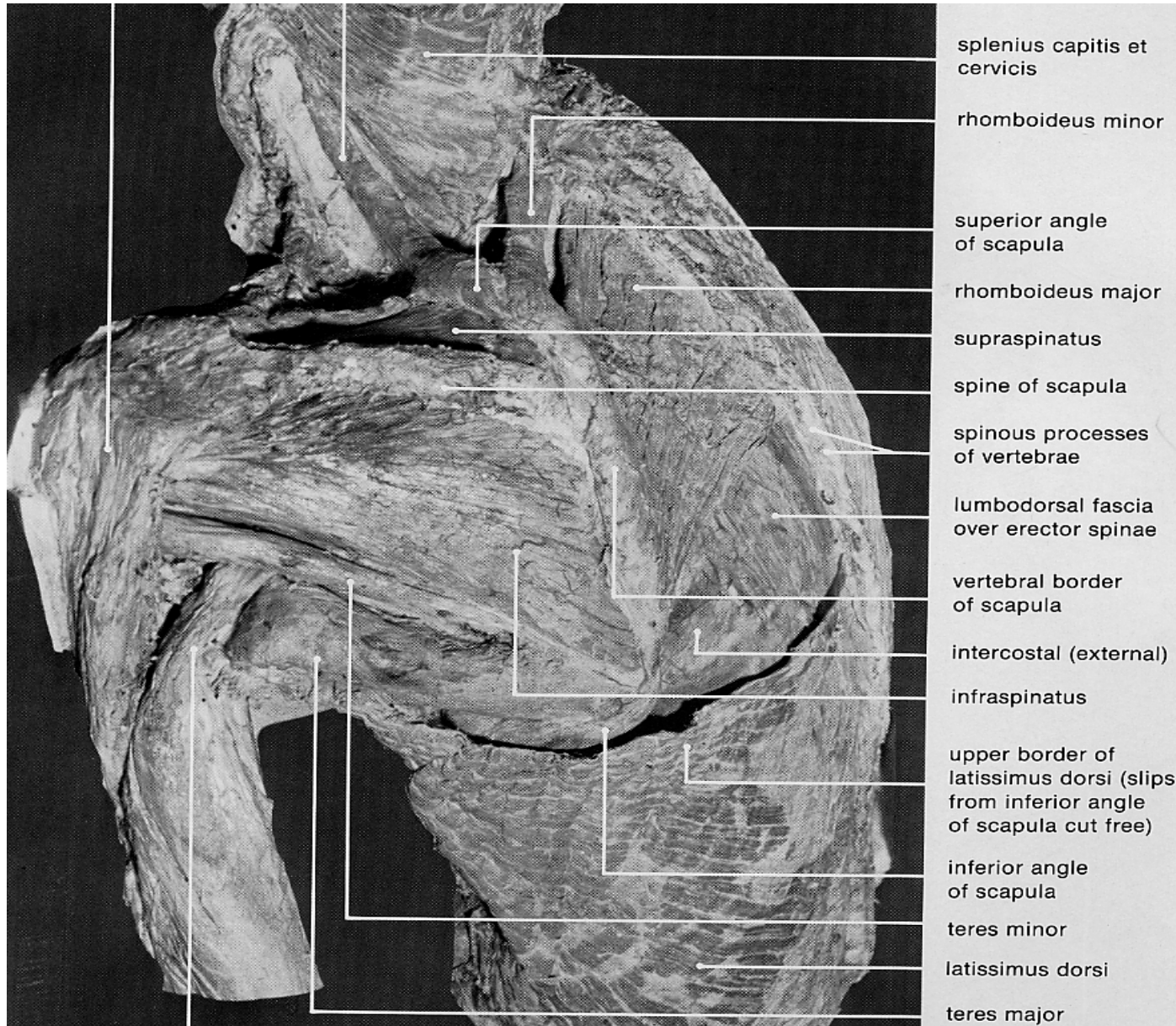
levator scapulae

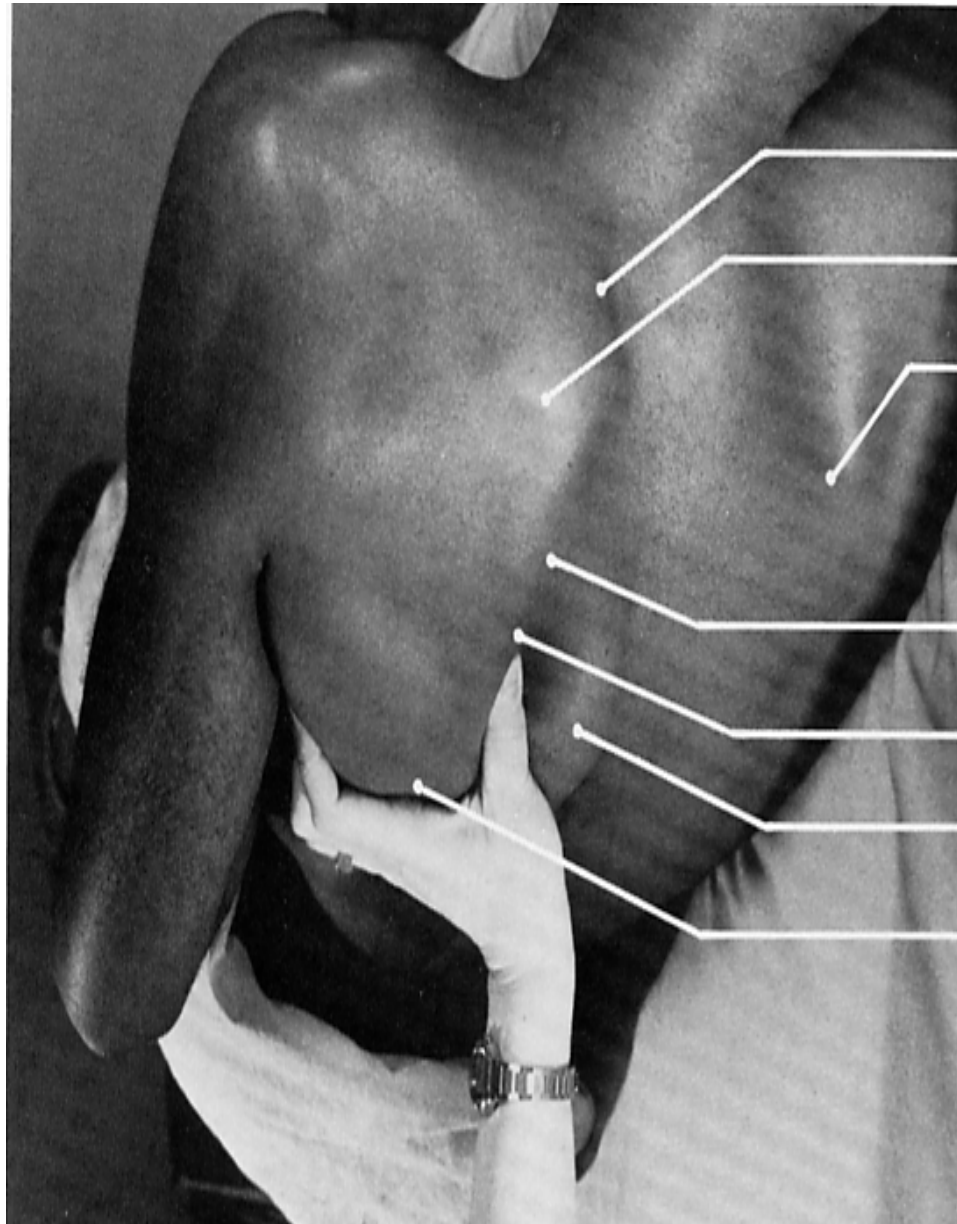
sternocleidomastoid (clavicular head)

sternocleidomastoid (sternal head)

pectoralis major (clavicular portion)

pectoralis major (sternal portion)





superior angle of scapula

spine of scapula

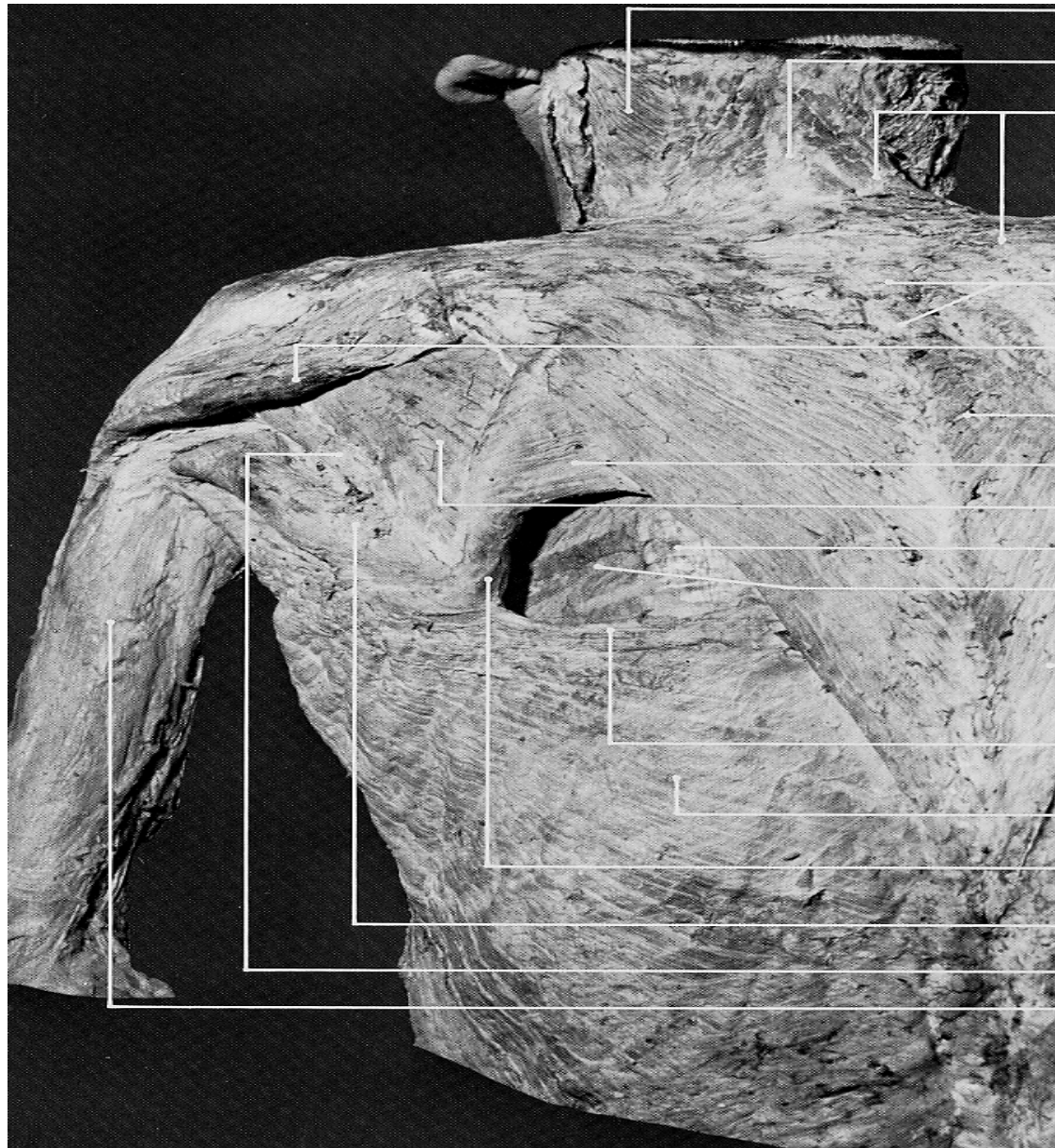
medial border of right scapula

medial border of left scapula

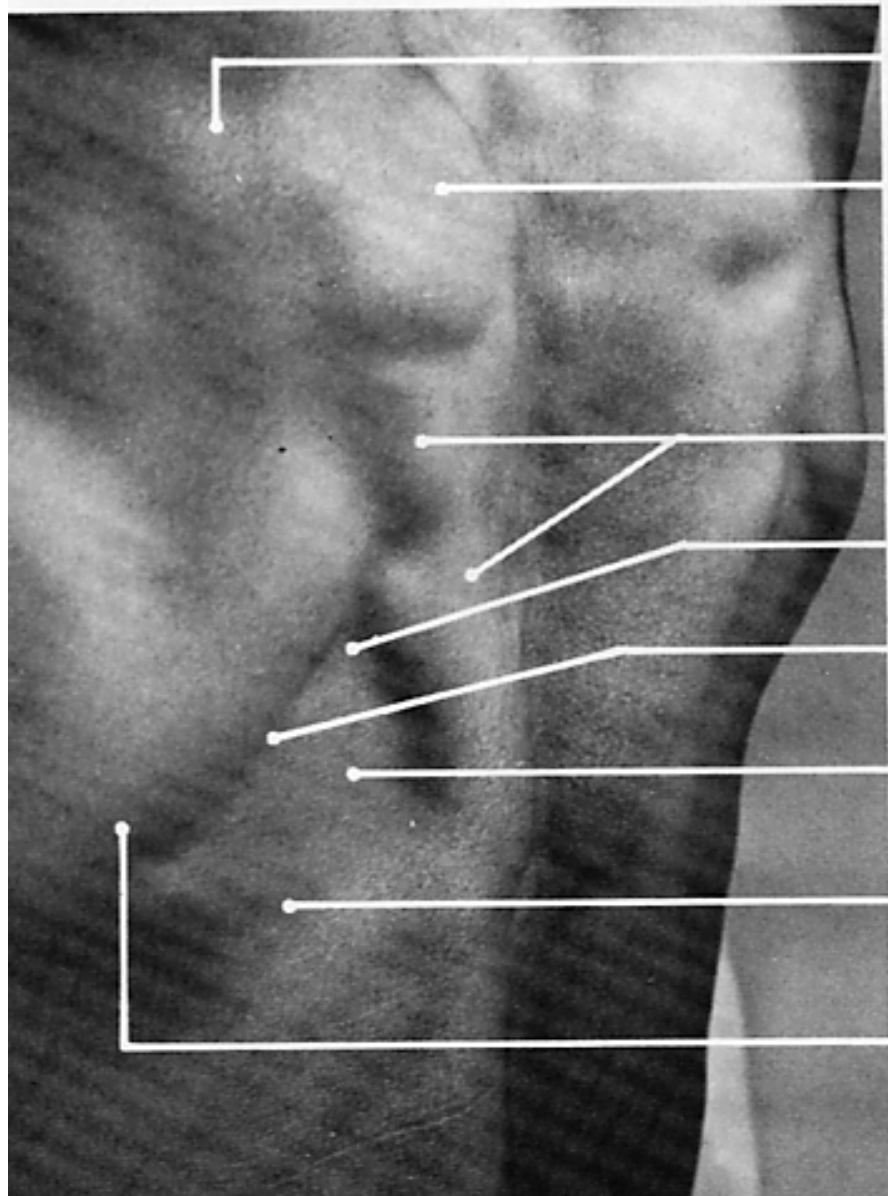
pin insertion site for **rhomboideus major**

trapezius (lower portion)

inferior angle of scapula



- spines capitis
et cervicis
- ligamentum nuchae
- trapezius
(upper portion)
- spinous processes
of vertebrae
- lower border of delt
(posterior portion)
- trapezius
(middle portion)
- rhomboideus major
- infraspinatus
- lumbodorsal fascia
- intercostal (external)
- trapezius
(lower portion)
- upper edge of
latissimus dorsi,
forming lower border
triangle of auscultat
- latissimus dorsi
- vertebral border
of scapula
- teres major
- teres minor
- triceps (long head)



spine of scapula

trapezius (middle portion)

trapezius (lower portion)

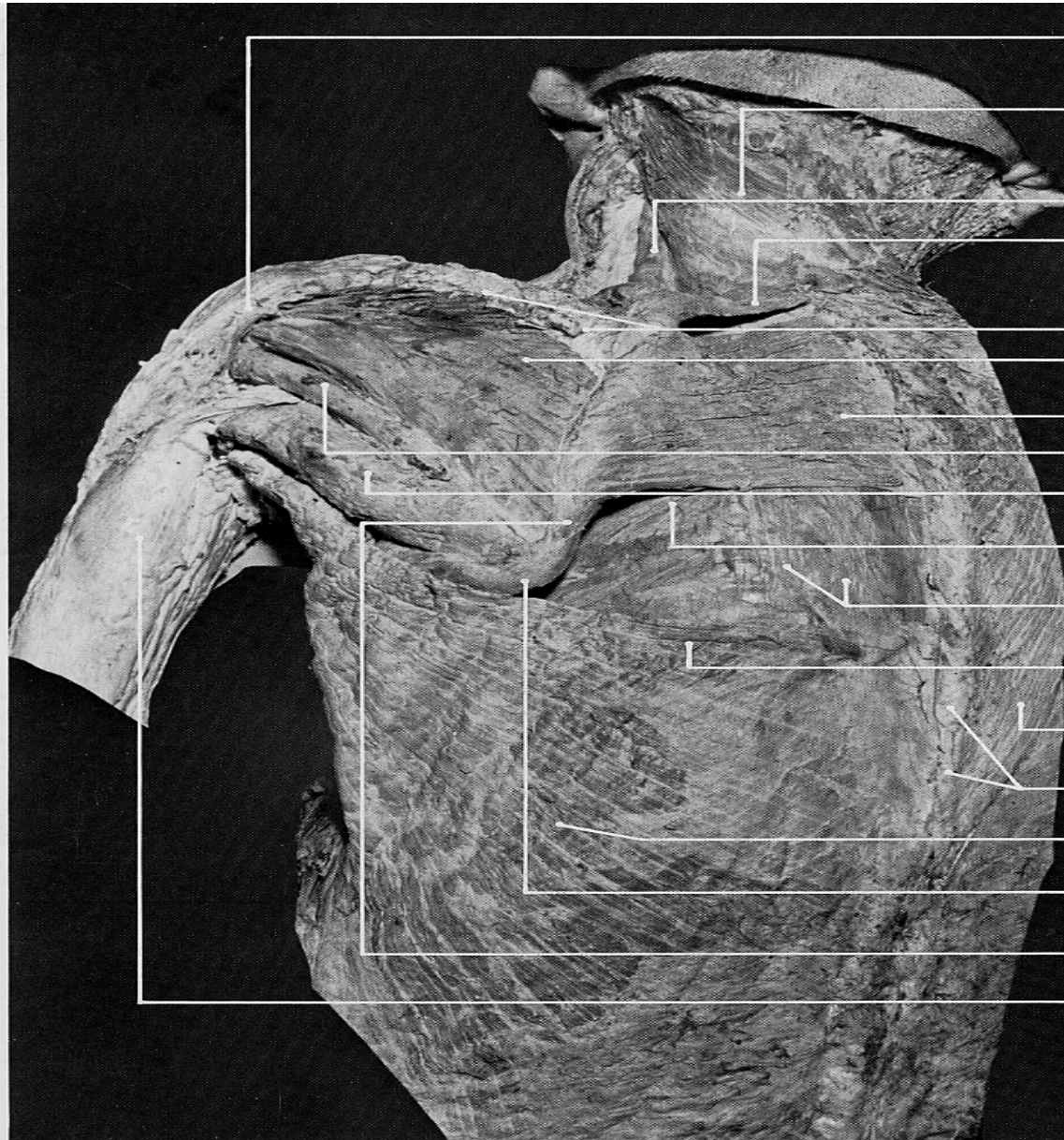
pin insertion site for **rhomboid**

medial border of scapula

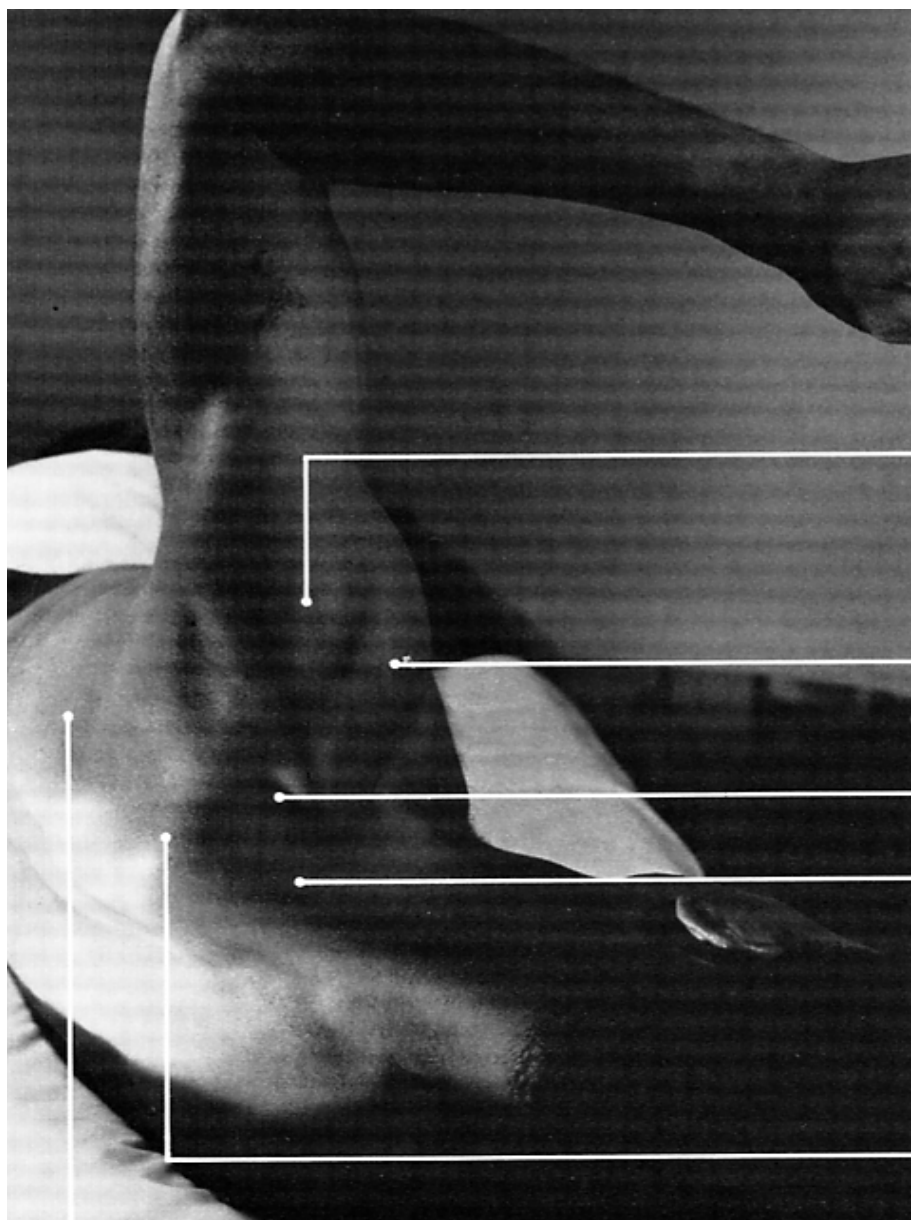
triangle of auscultation

upper border of latissimus dors

inferior angle of scapula



- deltoid (posterior portion largely cut away)
- splenius capitis et cervicis
- levator scapulae
- rhomboideus minor
- spine of scapula
- infraspinatus
- rhomboideus major
- teres minor
- teres major
- intercostal (external)
- lumbodorsal fascia over erector spinae
- upper edge of latissimus dorsi
- right trapezius (lower portion)
- spinous processes of vertebrae
- latissimus dorsi
- inferior angle of scapula
- vertebral border of scapula
- triceps (long head)



deltoid (middle portion)

deltoid (anterior portion)

supraspinatus
(deep to upper portion of trapez

trapezius (upper portion)

spine of scapula

infraspinatus

