



Human Anatomy in Motion: Head & Facial Muscles

**Jennifer Chu, M.D.
Electrodiagnosis: An Anatomical and Clinical Approach
Lippincott, Phila, 1986**


Copyright © Jennifer Chu, M.D.

Chu-Andrews
Johnson

Electrodiagnosis
An Anatomical and Clinical Approach

Electrodiagnosis

An Anatomical and Clinical Approach



Jennifer Chu-Andrews • Robert J. Johnson



Elsevier



Sponsoring Editor: Sanford J. Robinson
Manuscript Editor: Lee Henderson
Indexer: Ann Cassar
Design Director: Tracy Baldwin
Designer: Arlene Putterman
Production Supervisor: J. Corey Gray
Production Assistant: Kathleen R. Diamond
Compositor: Ruttle, Shaw & Wetherill, Inc.
Printer/Binder: Halliday Lithograph

Copyright © 1986, by Jennifer Chu-Andrews.
All rights reserved. No part of this book may be
used or reproduced in any manner whatsoever
without written permission except for brief
quotations embodied in critical articles and
reviews. Printed in the United States of
America. For information write J. B. Lippincott
Company, East Washington Square,
Philadelphia, Pennsylvania 19105.

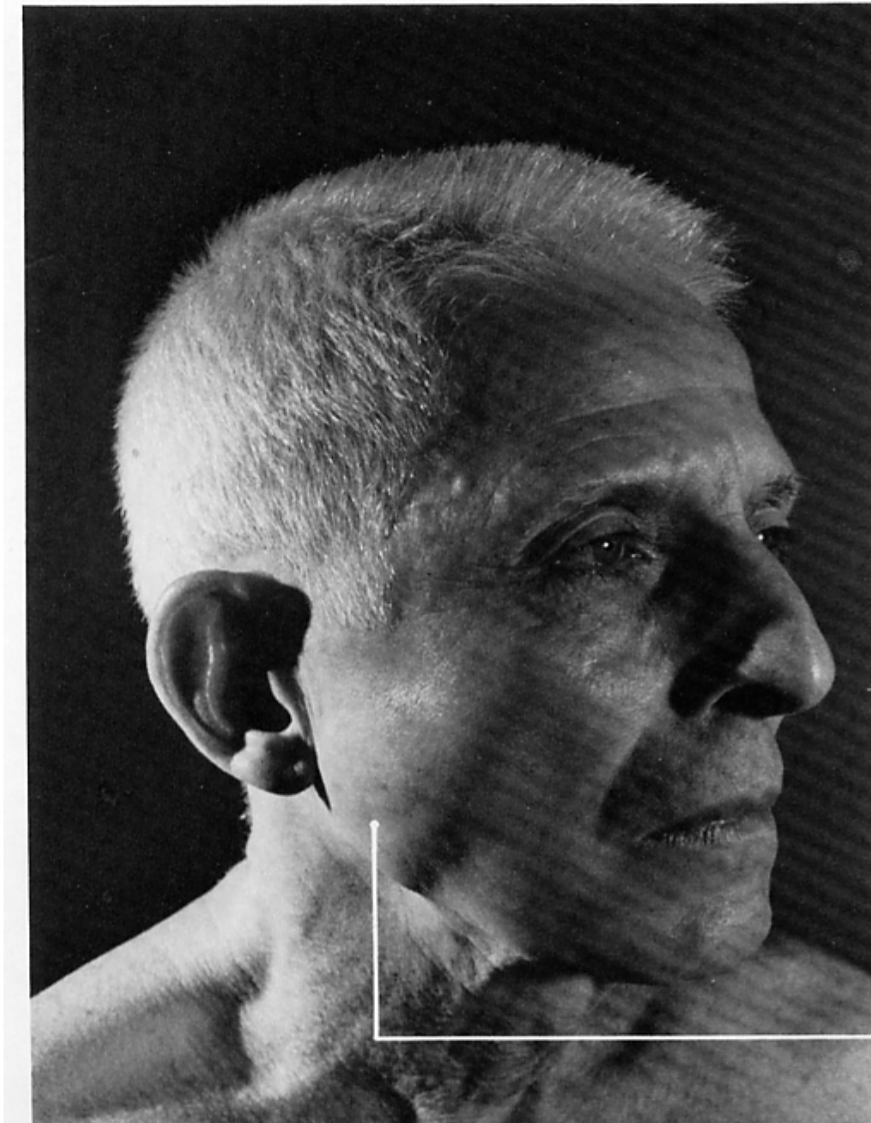
6 5 4 3 2 1

**Library of Congress Cataloging-in-
Publication Data**

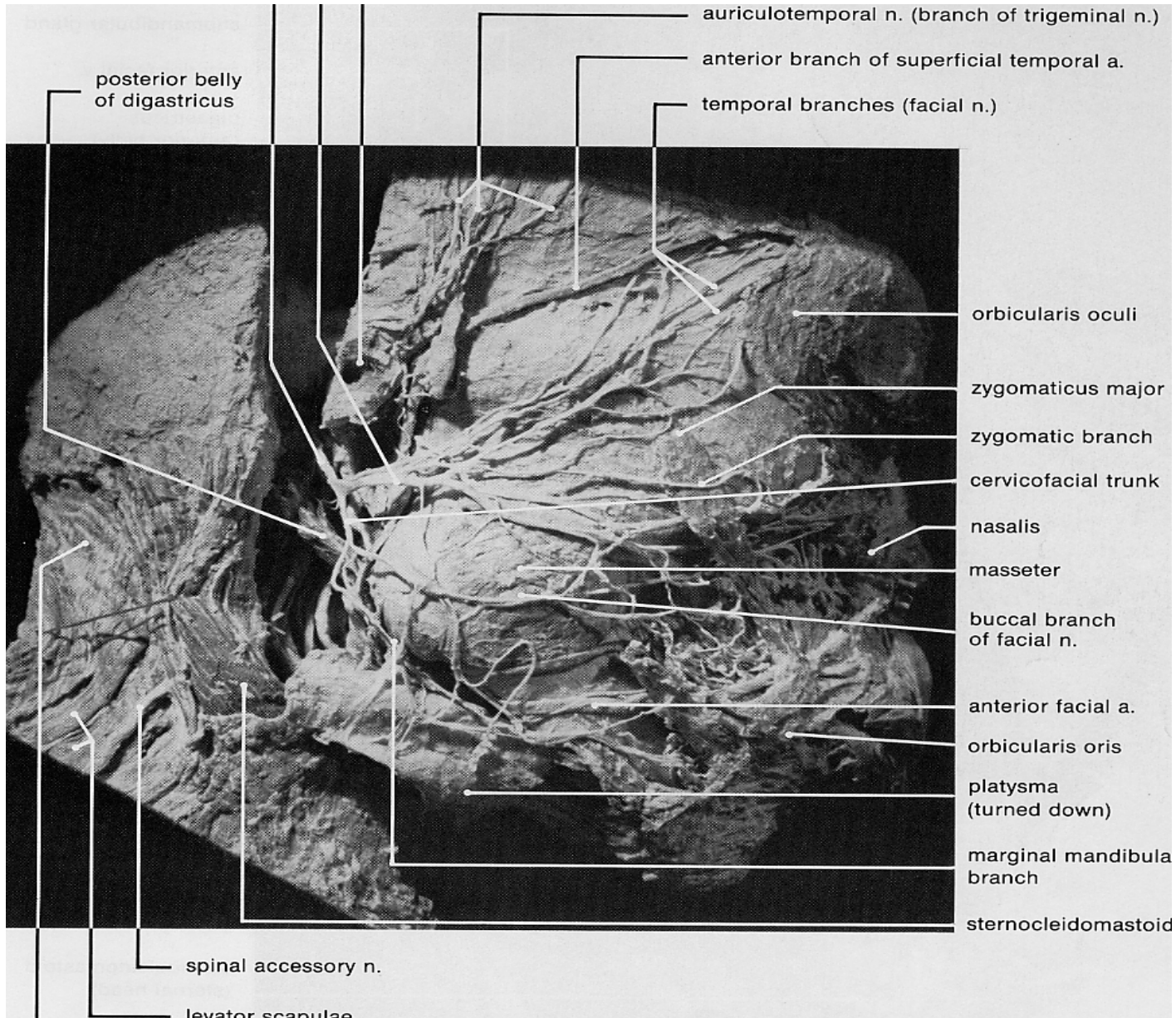
Chu-Andrews, Jennifer.
Electrodiagnosis: an anatomical and clinical
approach.

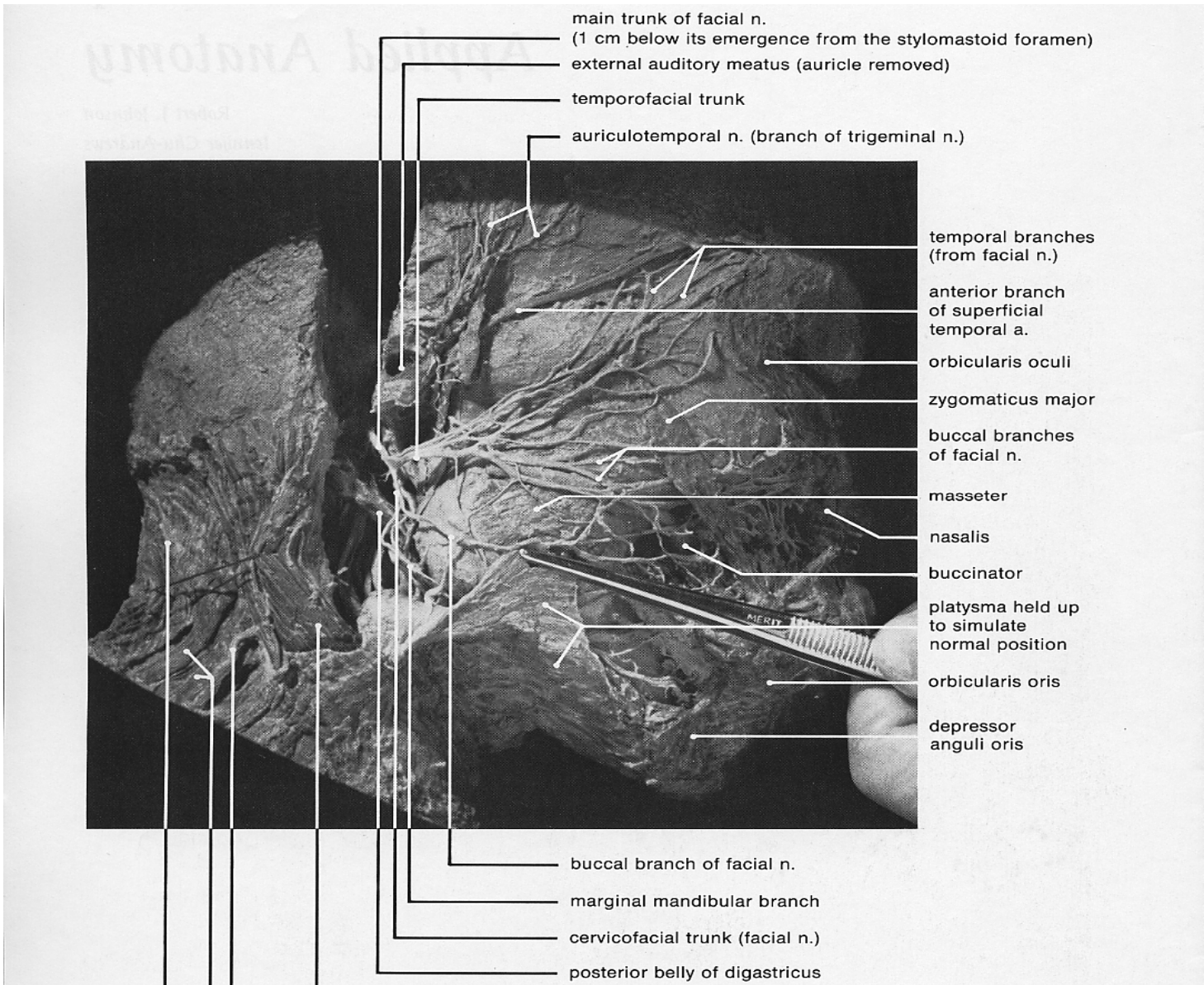
Includes bibliographies and index.

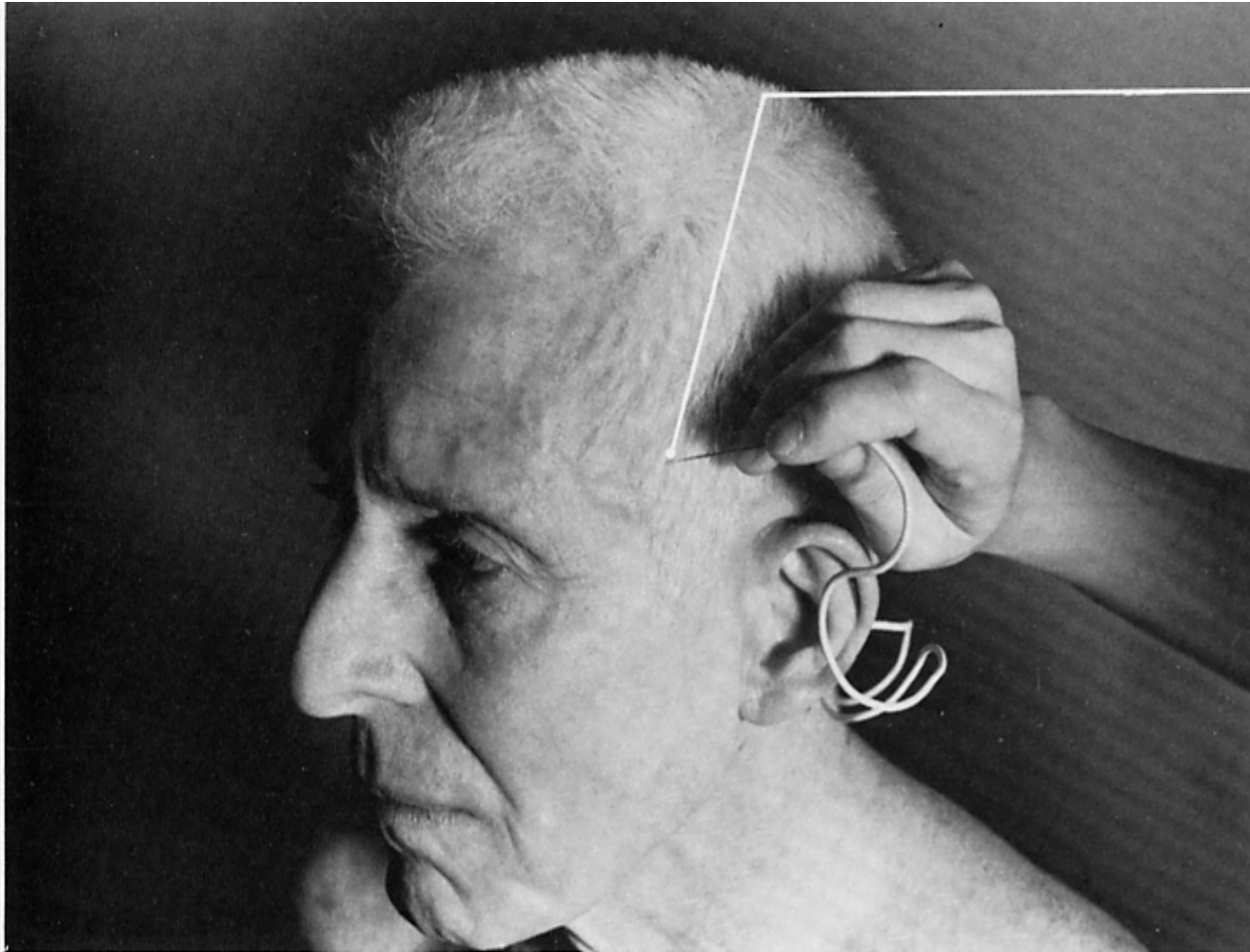
I. Neuromuscular diseases—Diagnosis. 2.
Electrodiagnosis. 3. Electromyography. I.
Johnson, Robert J. (Robert Joseph), DATE. II.
Title. [DNLM: 1. Anatomy. 2. Electrodiagnosis.
WB 141 C5587e]
RC925.7.C48 1986 616.7'4'07547 85-19884
ISBN 0-397-50687-2



masseter (superficial portion)

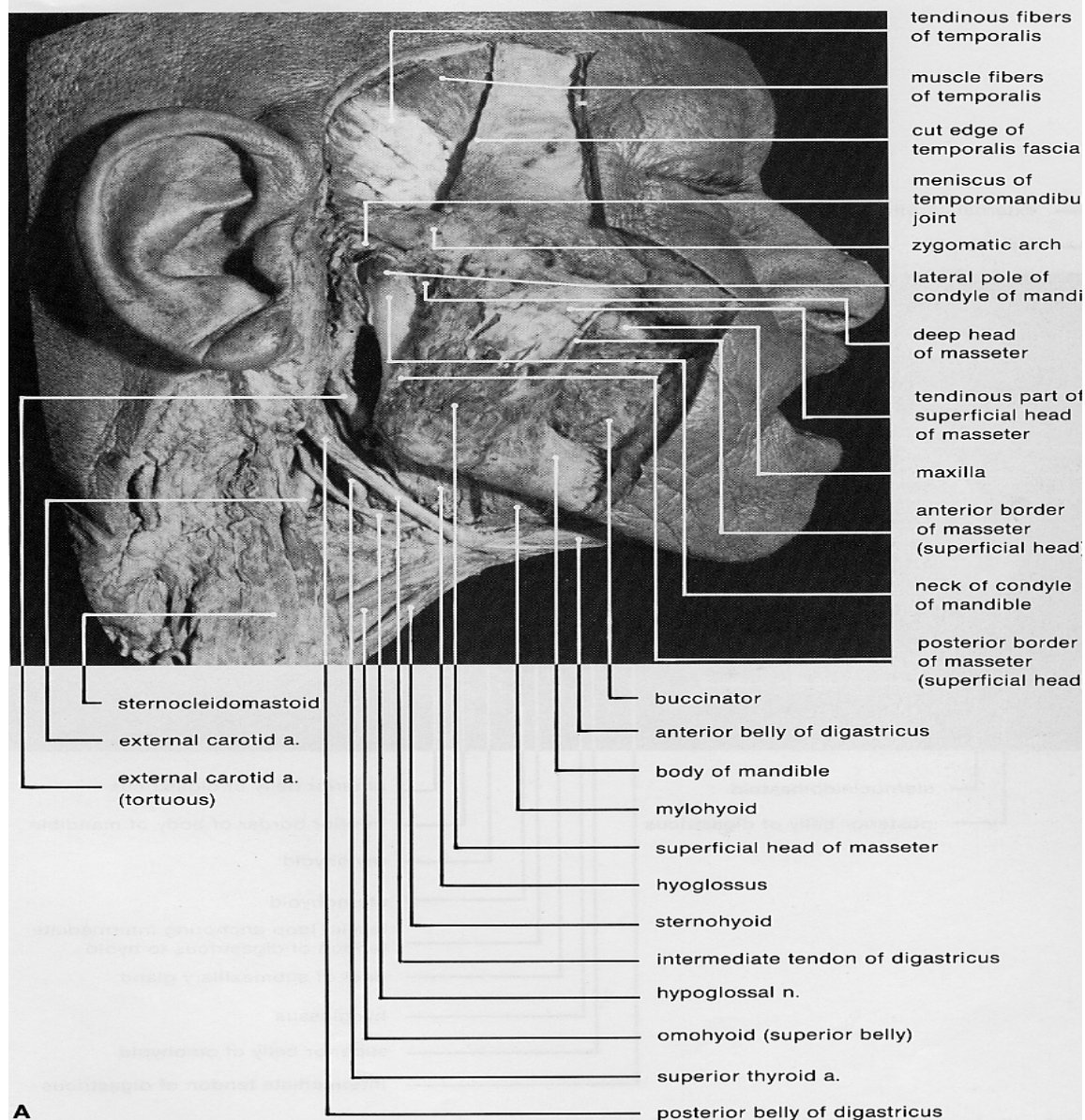






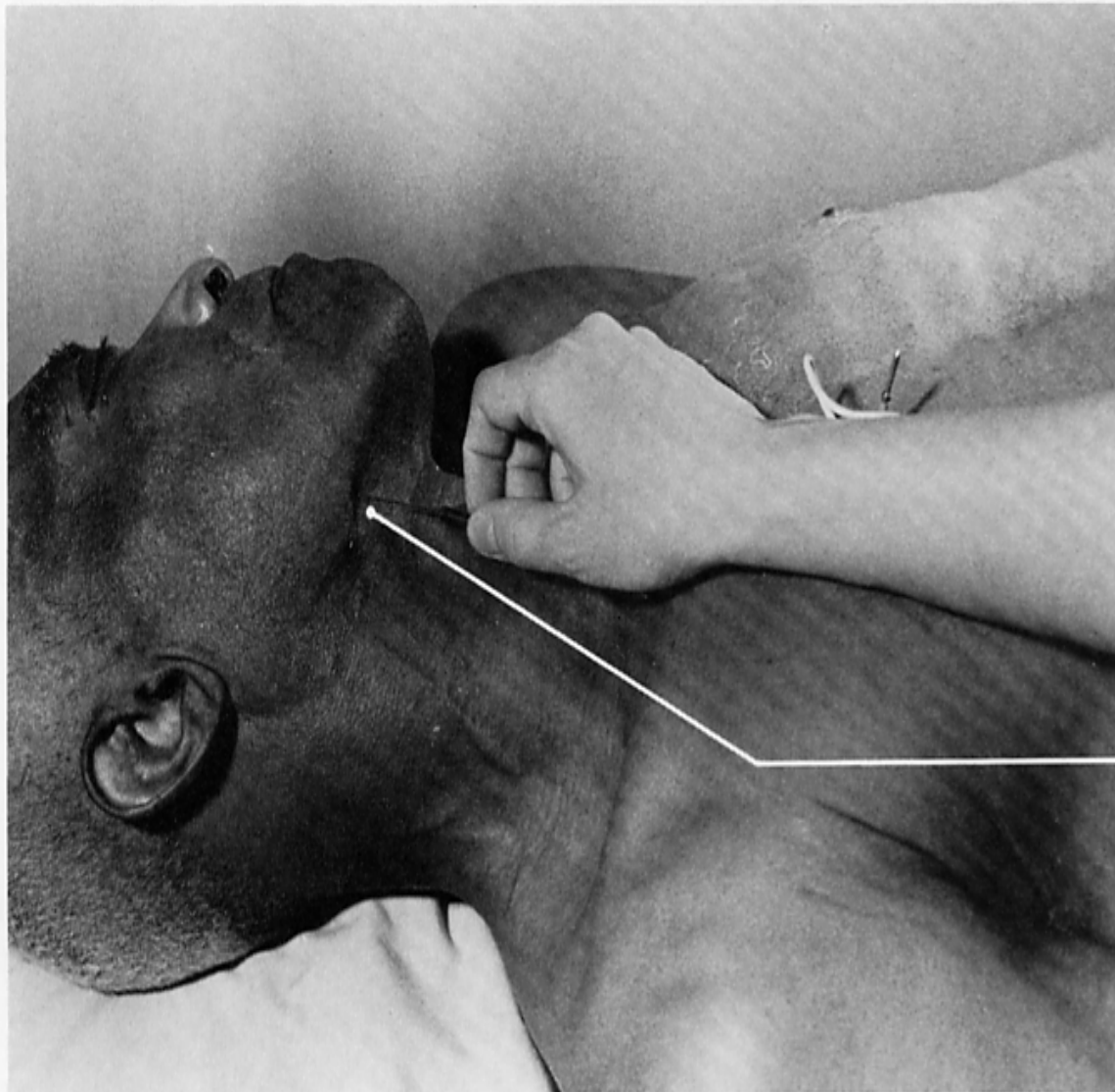
pin ins
for ter

FIGURE 2-1 Temporalis.

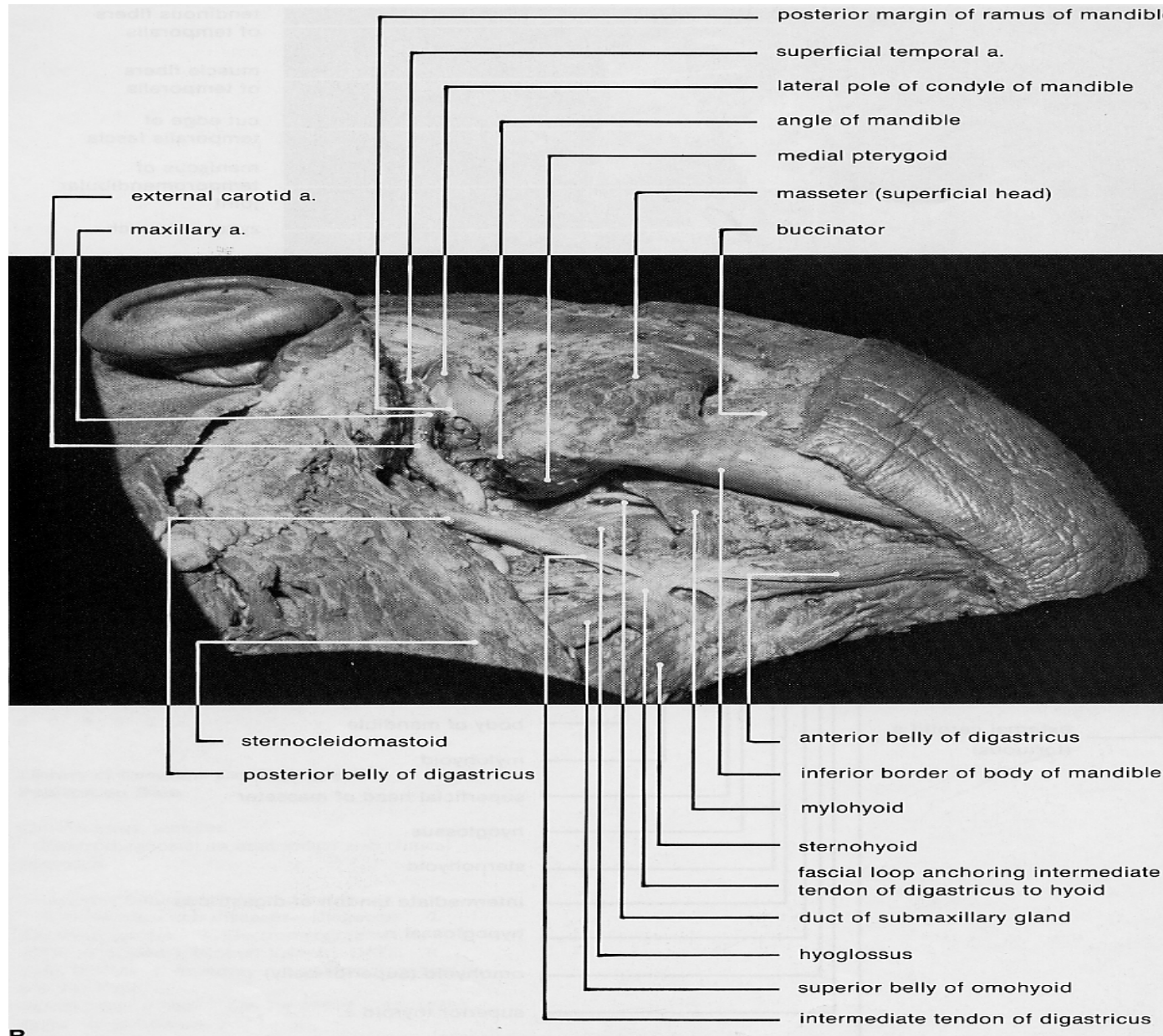


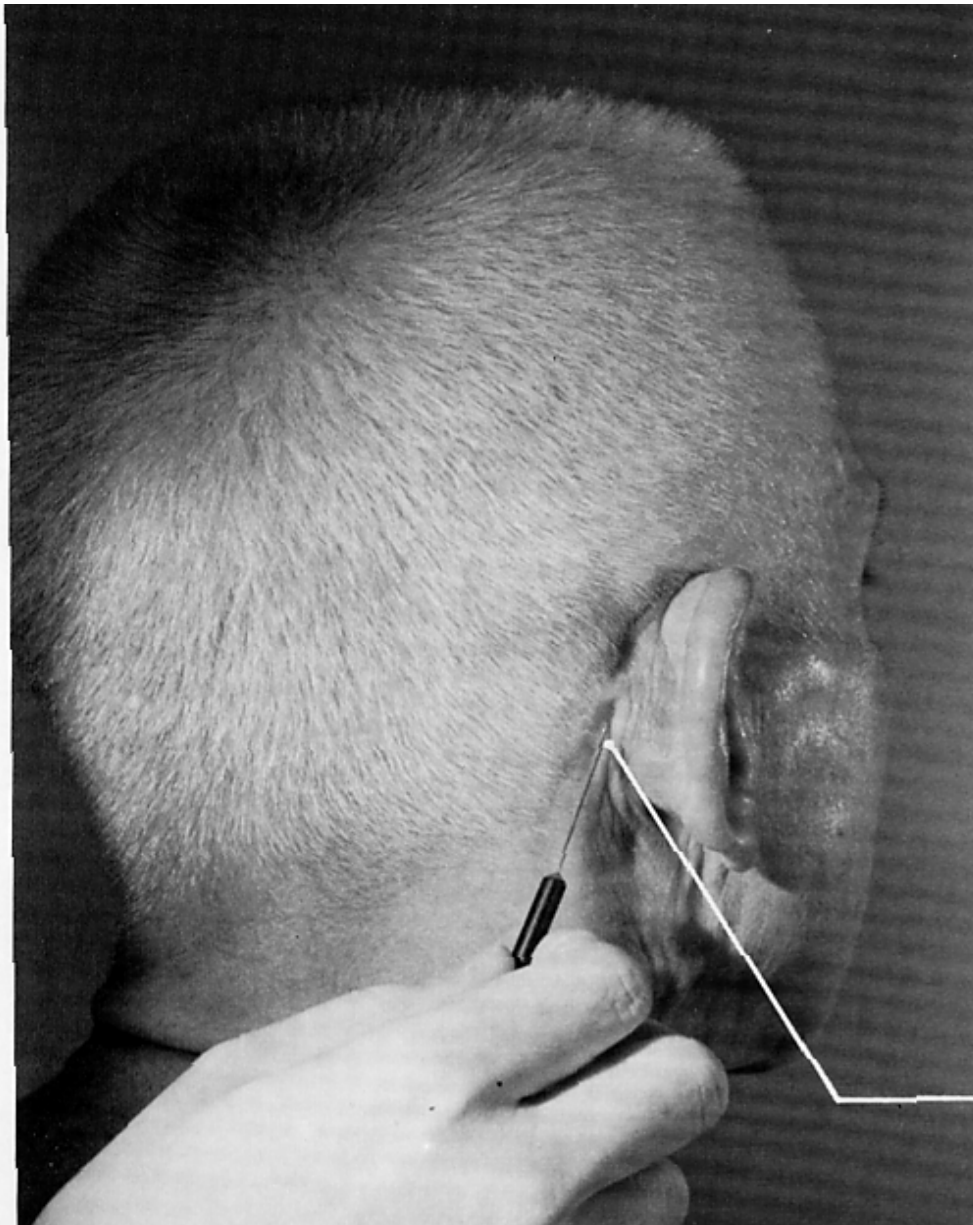
A

FIGURE 1-9 (A) Head and neck—lateral view (muscles of mastication, parotid gland totally removed)

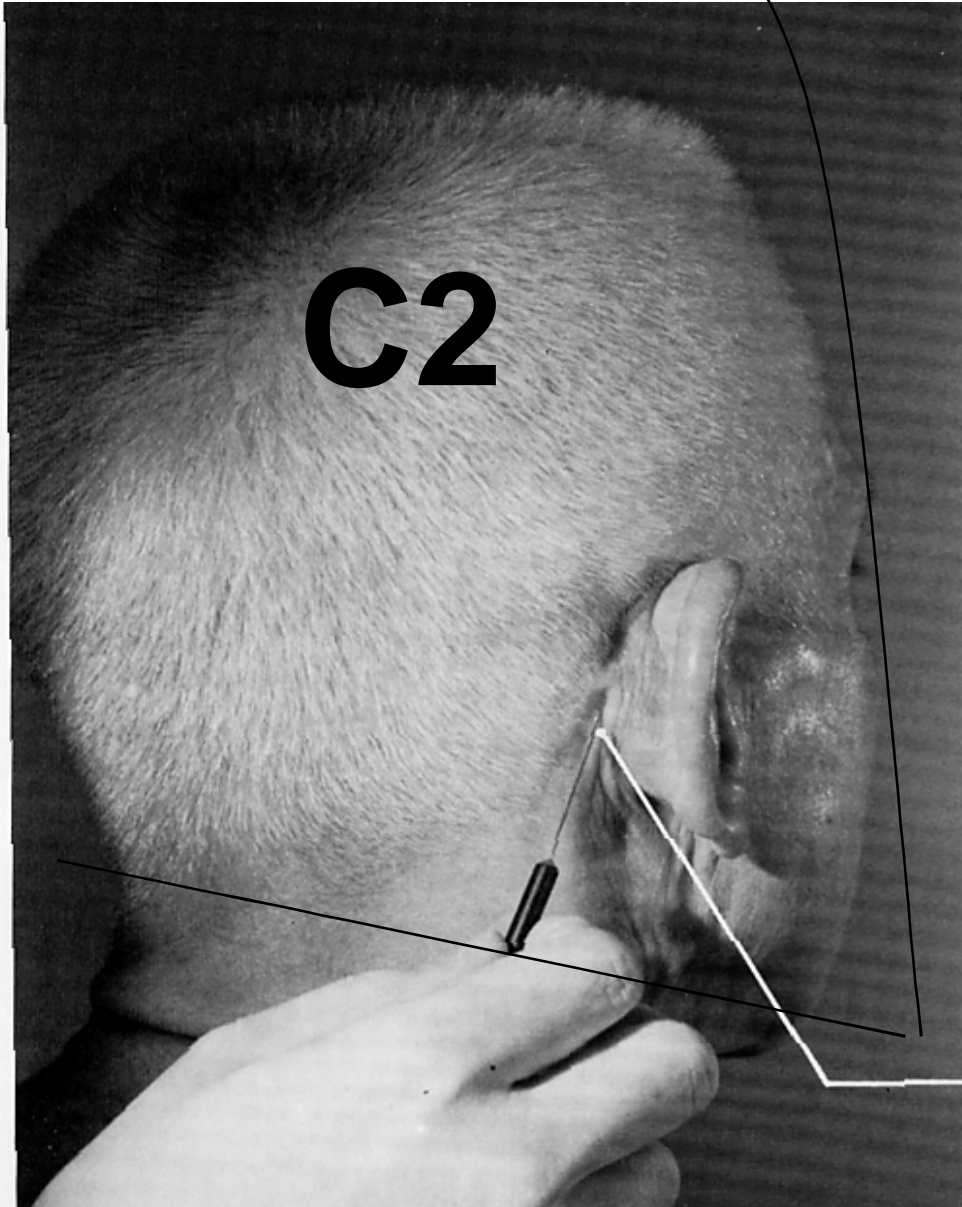


pin insertion site for
internal (medial) pterygoid

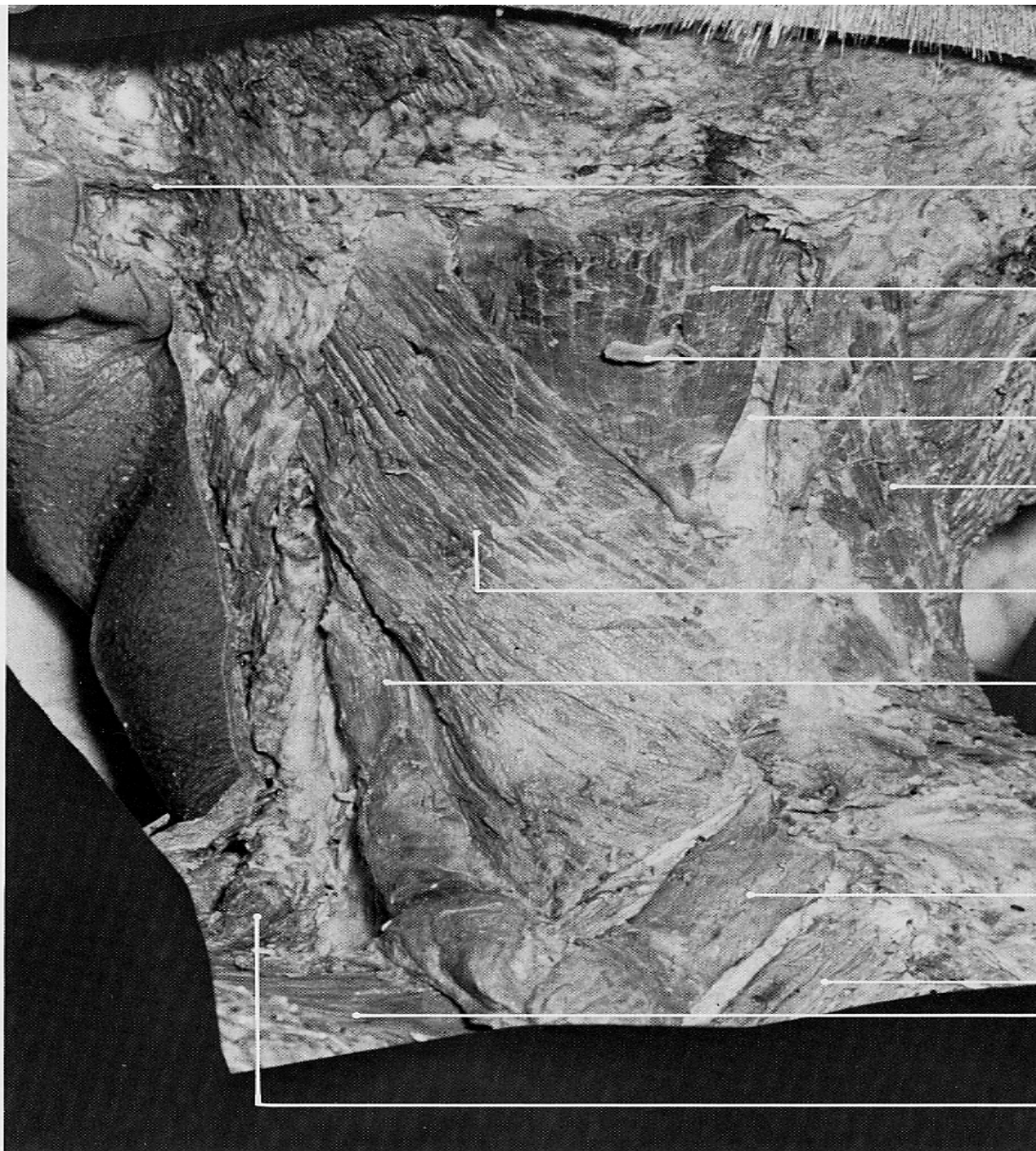




pin insertion site
for **auricularis posterior**



pin insertion site
for **auricularis posterior**



auricularis posterior

semispinalis

posterior primary
division of second
cervical n.

ligamentum nuchae

right trapezius
(upper portion)

splenius capitis et
cervicis

levator scapulae

rhomboideus minor

rhomboideus major
supraspinatus

sternocleidomastoid


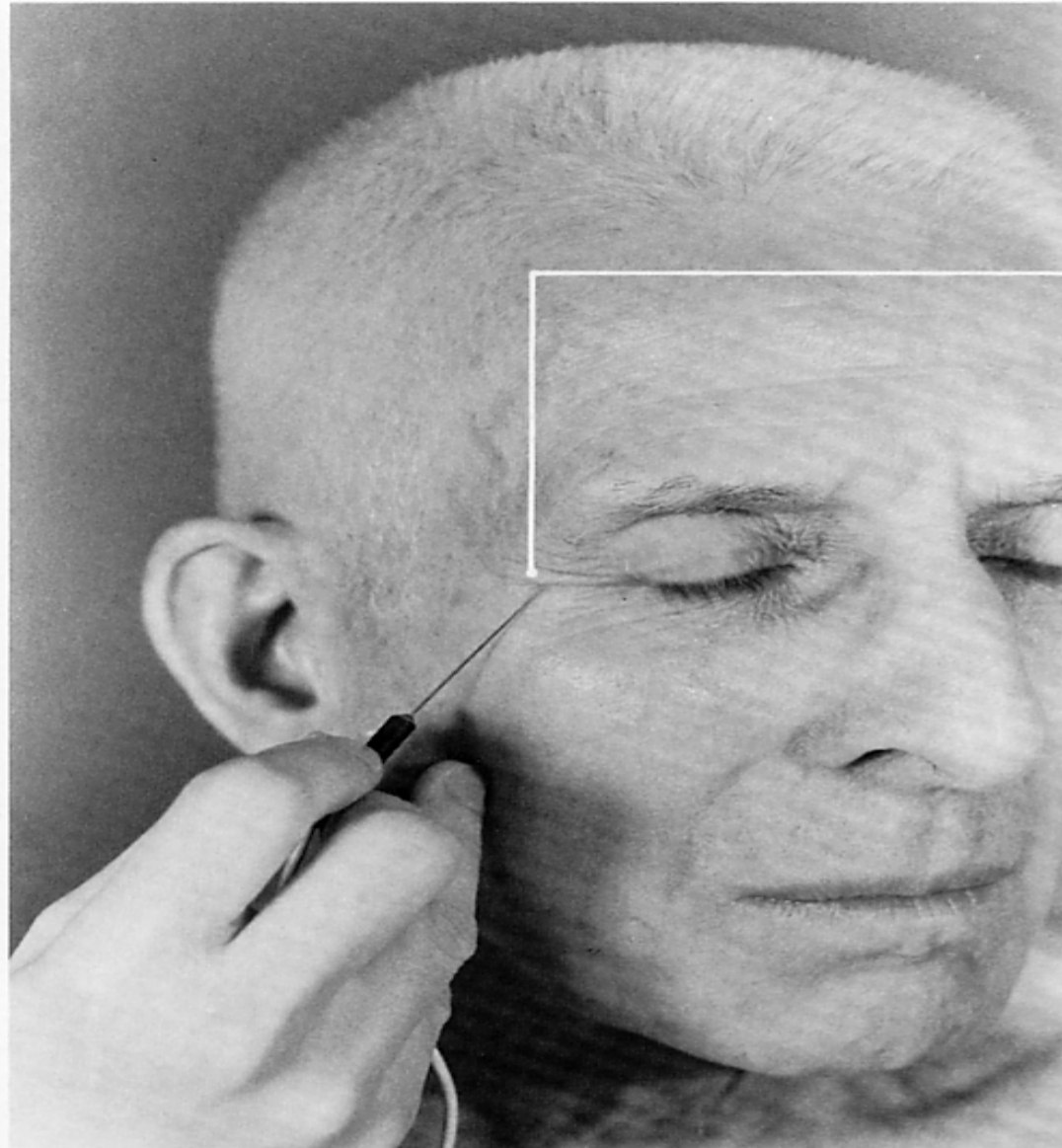
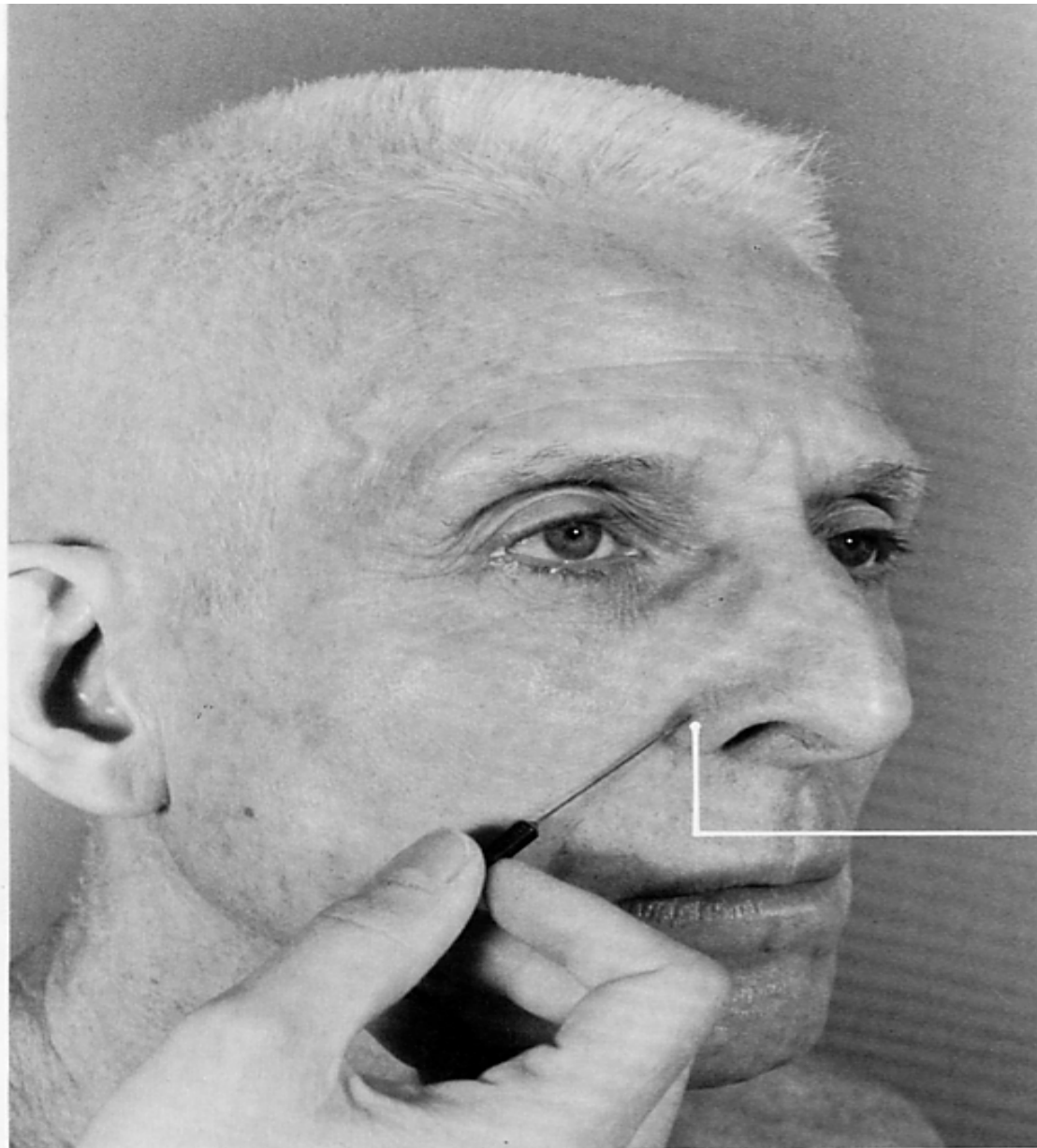


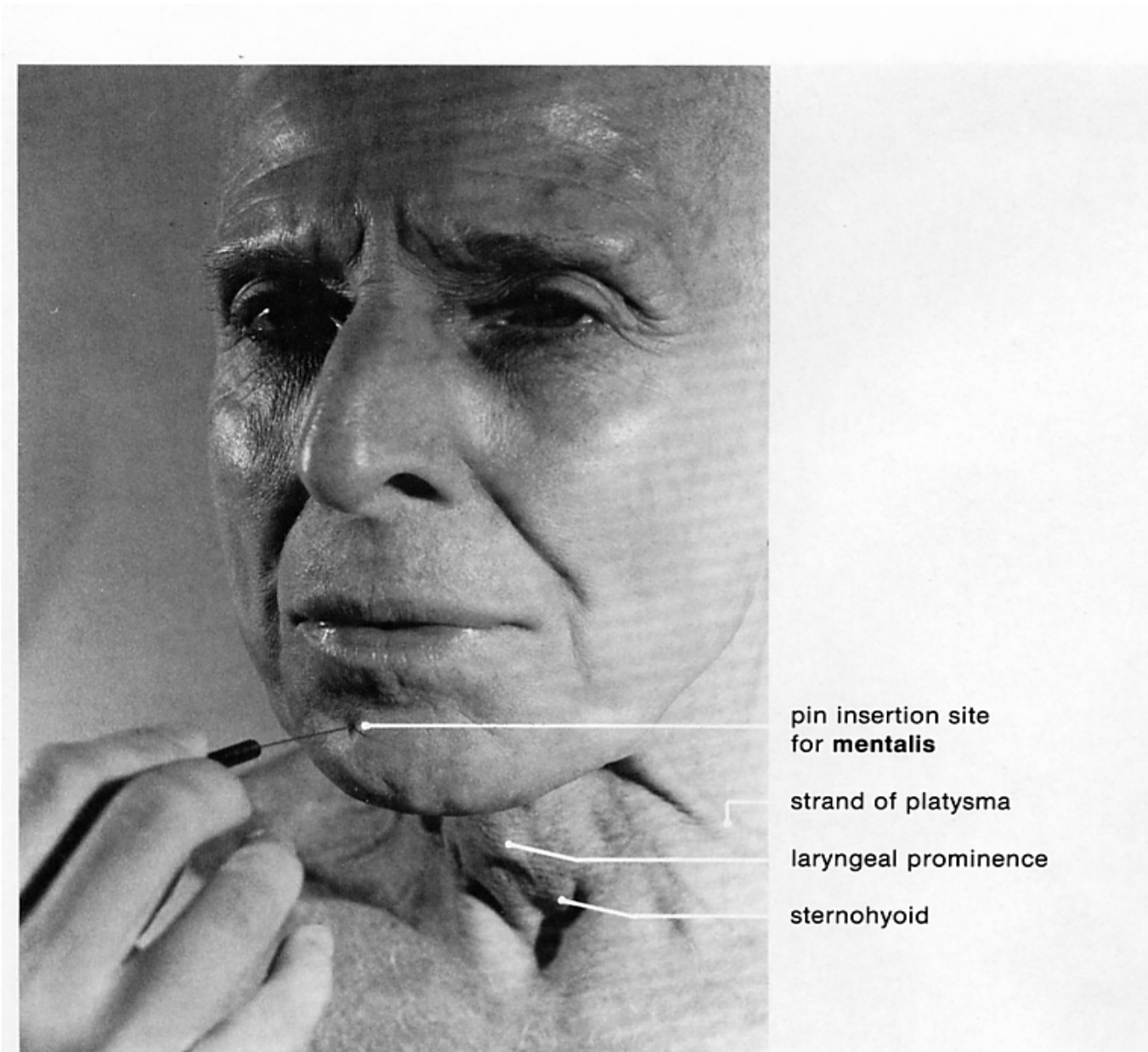
FIGURE 2-5 Frontalis.

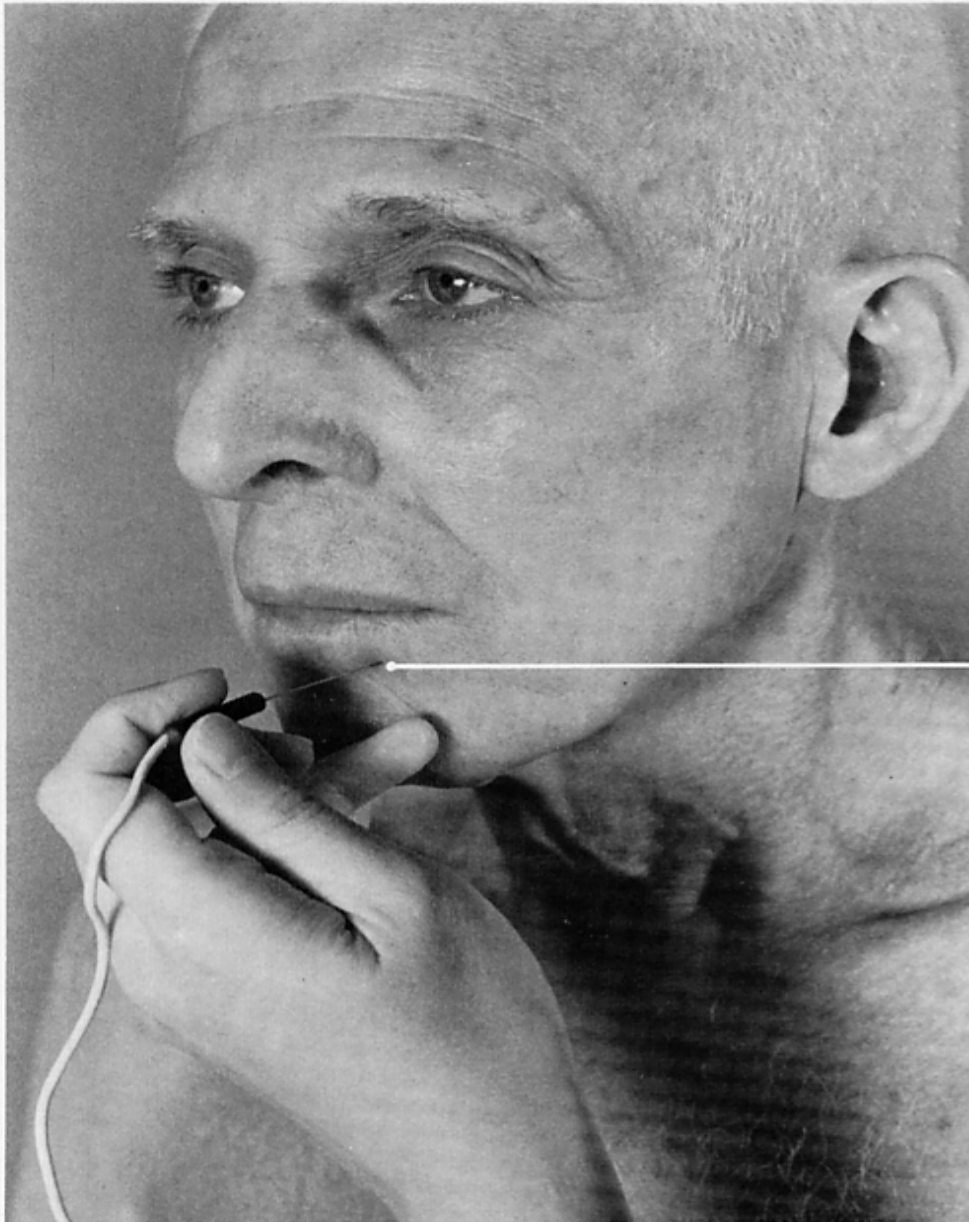


pin insertion site
for **orbicularis oculi**

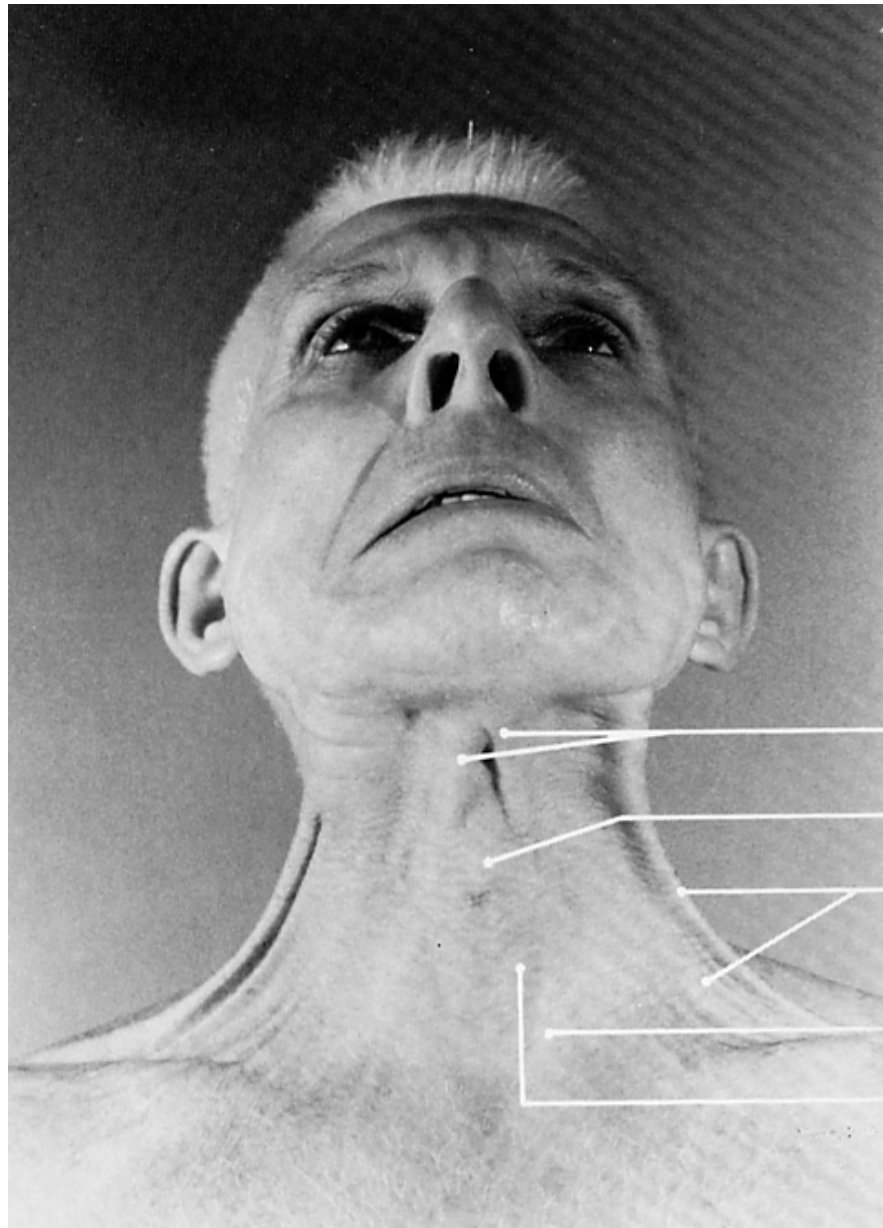


pin insertion :
for **nasalis**





pin insertion site
for **orbicularis oris**



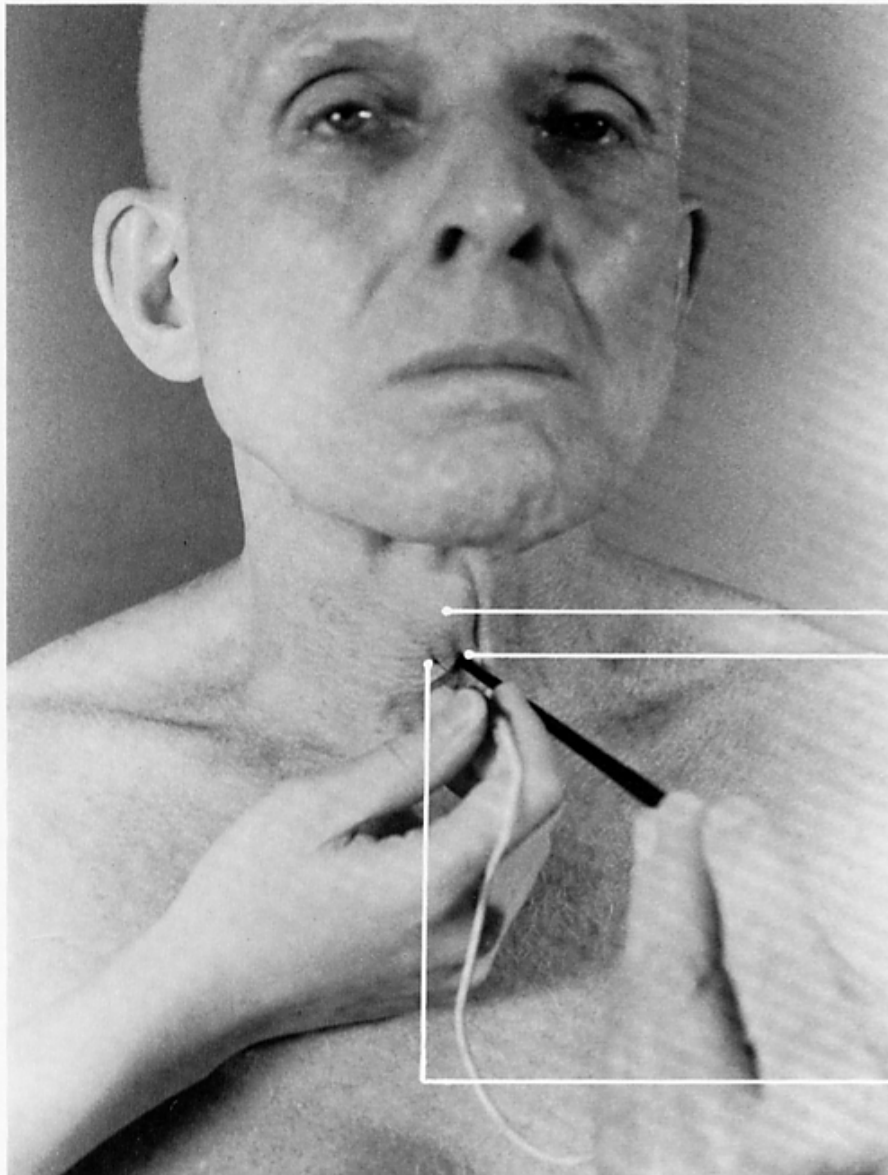
decussating fibers of **platysma**

laryngeal prominence

platysma

sternocleidomastoid (sternal head)

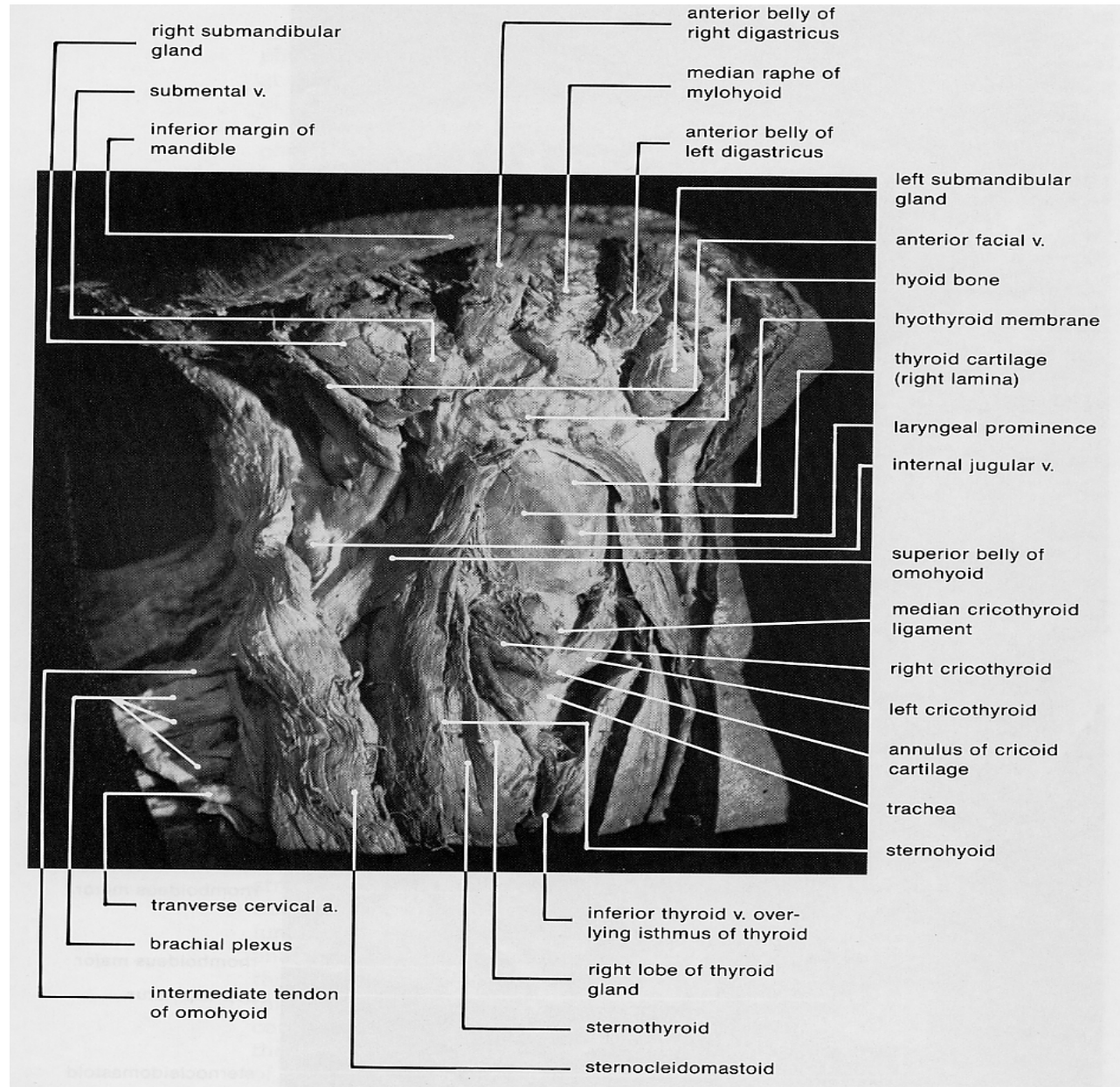
sternohyoid

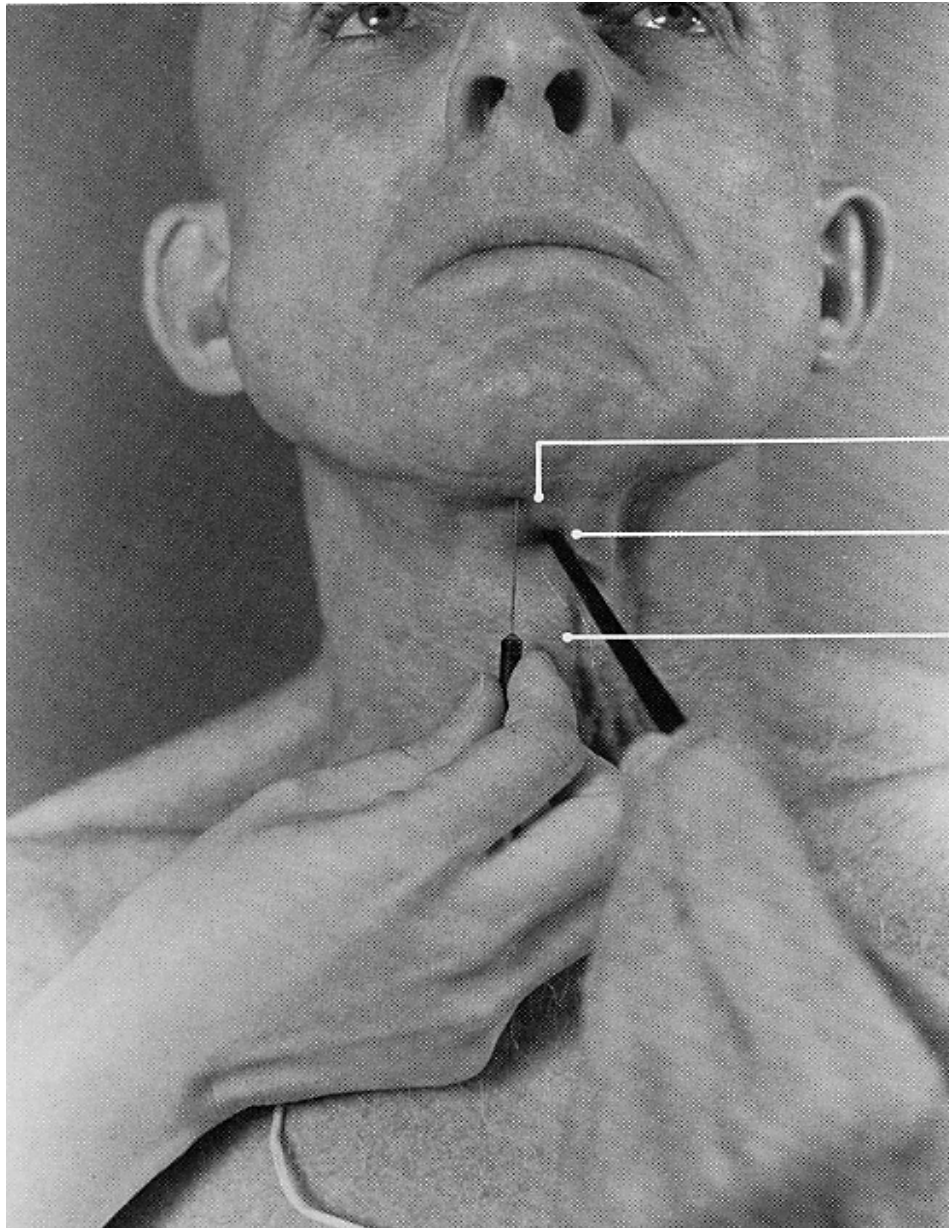


laryngeal prominence

upper border of cricoid cartilage

pin insertion site
for **cricothyroid**





pin insertion site
for **genioglossus**

hyoid bone

laryngeal prominence

